

Sequential use of cryoextraction postelectrocautery for airway recanalization using fiberoptic bronchoscopy

Mohammad Kh. El Badrawy, Nesrein M. Shalabi, Asem A. Hewidy, Ahmed M. Fouda

Background Airway obstruction presents with dyspnea, cough, hemoptysis, and atelectasis. Removing or decreasing the size of the obstructing lesions improves patient's symptoms and life quality.

Aim Assessing the efficacy and safety of sequential use of cryoextraction and electrocautery in achievement of airway patency using fiberoptic bronchoscopy (FOB).

Patients and methods This study was conducted at the Chest Medicine Department, Mansoura University, Egypt and included 22 patients with central airway obstruction (15 males and seven females) with a mean age of 50.5 ± 18.3 years. After etiologic diagnosis of airway obstruction, they were divided into two groups: group A (nonmalignant); eight patients and group B (malignant); 14 patients. All patients were subjected to sequential use of cryoextraction after electrocautery. Operable, unfit patients or patients with extraluminal obstruction were excluded. Clinical, radiological, functional, and bronchoscopic data were evaluated before and after FOB.

Results The improvement in performance scale was highly significant in group B ($P < 0.001$) and significant

in group A ($P = 0.001$). Spirometric parameters improved in both groups but were highly significant in group B ($P < 0.001$). Radiological improvement occurred in four out of eight of group A and in three out of 14 of group B. FOB score improved in group B ($P = 0.003$) and was more significant in group A. The procedure was complicated with atrial fibrillation and hemoptysis in one case and postbronchoscopy hypoxemia in two cases with no deaths.

Conclusion Cryoextraction after electrocautery using FOB are effective, safe, easy, and cheap in achieving airway patency. *Egypt J Broncho* 2015 9:269–275
© 2015 Egyptian Journal of Bronchology.

Egyptian Journal of Bronchology 2015 9:269–275

Keywords: cryoextraction, electrocautery, lung cancer

Department of Chest, Faculty of Medicine, Mansoura University, Mansoura, Egypt

Correspondence to Asem A. Hewidy, MD, 15-Beshbeshi St, Hay Elgamaa, Mansoura, Egypt
Tel/fax: +20 100 521 0674;
e-mail: ahewidy@yahoo.com

Received 20 April 2015 **Accepted** 14 May 2015

Introduction

Central airway obstruction from malignant or benign endobronchial tumor may lead to symptoms and respiratory failure. Therapeutic bronchoscopy offers an effective method in the palliation of lung cancer especially in alleviating dyspnea, controlling hemoptysis, and improving quality of life [1]. Endobronchial electrocautery is the application of heat produced by high-frequency electrical current to treat tumor tissue using special accessories such as coagulation probes, knives, and snares. It is considered as poor man's laser [2]. Endobronchial cryotherapy refers to the application of cold to destroy the tissue using cytotoxic effects of freezing. If the fiberoptic cryoprobe is applied to a tissue, it will stick to it and can be extracted *in toto* and may be used for tumor debulking [3].

Endoscopic treatment with fiberoptic bronchoscopy (FOB) by electrocautery and extraction provides an excellent outcome when performed by expert hands. Therefore such treatment is recommended in highly symptomatic patients or in those patients with significant bronchial obstructions [4].

Patients and methods

After approval of the local ethical committee of Faculty of Medicine, this prospective study was conducted at Chest Medicine Department, Mansoura University Hospitals, Egypt during the period from September 2012 to December 2013. Sixty-three patients with suspected central airway obstruction were enrolled in this study and 41 of them were excluded. Our study included 22 patients (15 males and seven females) with age range from 13 to 80 years and a mean age of 50.5 ± 18.3 years. Patients gave their signed written consents after detailed explanation of the protocol of the study. All the included patients were diagnosed to have tracheal, bronchial or tracheobronchial obstruction either with malignant or nonmalignant causes. They were divided into two groups according to the cause of airway obstruction: group A (nonmalignant) included eight patients with endobronchial obstruction by benign tumor, granulation tissue either post-

This is an open access article distributed under the terms of the Creative Commons Attribution-NonCommercial-ShareAlike 3.0 License, which allows others to remix, tweak, and build upon the work non-commercially, as long as the author is credited and the new creations are licensed under the identical terms.

tracheostomy or with foreign body and group B (malignant) included 14 patients with endobronchial obstruction by malignant tumors.

The obstructing lesions must be endoluminal in the trachea, main bronchi or lobar bronchi, and the margin between the lesion and the bronchial wall should be identified [5]. The excluded patients were 41; five were candidates for surgery, seven refused to be enrolled in the study, four with uncorrectable bleeding diathesis, five with intractable arrhythmia, two with a pacemaker, 12 with severe pulmonary dysfunction, and six with extraluminal compression on the airway were excluded from the study.

The endpoint of the procedure was a satisfactory response of airway opening or a maximum of three sessions of electrocautery and cryoextraction.

Methods

All patients were subjected to the following:

Clinical evaluation

With stress on dyspnea, cough, hemoptysis, performance status, quality of life, and lung collapsing before and 1 day after the last session of the procedure, dyspnea was evaluated according to American Thoracic Society (1999) [6]. Hemoptysis and cough were evaluated according to Walsh *et al.* [7]. Lung collapsing was evaluated according to Speiser and Spratling [8]. Performance status was done using Karnofsky performance scale (KPS) according to Muers [9] and evaluation of quality of life status was done according to Gridelli *et al.* [10].

Laboratory investigations

Complete blood count, liver function tests, kidney function tests, and coagulation profile were performed before FOB.

Radiological investigations

Chest radiography and computed tomography chest for staging and postobstruction effects as consolidation or collapse before and 1 day after the last session were performed.

Spirometry

Using smart pulmonary function test (PFT) CO with stress on FVC% and FEV₁% of the predicted and FEV₁/FVC ratio.

Fiberoptic bronchoscopy

For diagnosis and treatment: FOB (Pentax FB 19 TV; Hoya corporation, Tokyo, Japan), with porcelain tip and inner channel diameter of 3.2 mm was used after local instillation of 2% lidocaine and intravenous 5–10 mg midazolam 15 min before the procedure. Through

oral route, diagnostic FOB was done for patients with suspected airway obstruction for biopsy and evaluation of the degree of airway obstruction according to Speiser [11] (Table 1). After diagnosis, the patient included in the study was subjected to therapeutic cryoextraction after electrocautery from one to a maximum of three sessions and the duration of session was a maximum of 45 min according the response to therapy and patient tolerability.

Number of sessions was individualized according to the response of the airway opening. The sessions were repeated every week for re-evaluation and application of therapy if needed.

- (a) Endobronchial electrocautery was done using an electrocautery device WEM SS-100 MC, WEM equipamentos eletronicos ltda: Riberao preto (Brazil), using high-frequency electrocautery generator with blunt ended probe. It was applied in direct contact with the obstructing lesion for 3–4 s in each shot till debridement of the obstructing lesion, using energy of 70 W and utilizing the spray mode. The probe was applied to the lesion according to the site and pathology of the obstruction. If the obstruction was circumferential, the probe was applied in the four directions: at 3, 6, 9, and 12 o'clock then the rest was debrided. If the obstruction was total, the probe was applied firstly in the center of the obstructing lesion. If the obstruction was from one direction, the probe was applied to its pedicle. If the obstruction was by foreign body, debridement of the covering granulation tissue with electrocautery was followed by extraction with cryoprobe.
- (b) Endobronchial cryoextraction was done by device (ERBE erbokryo ca; ERBE Elektromedizin GmbH, Tübingen, Germany). The flexible cryoprobe was used with outer diameter of 2.8 mm utilizing carbon dioxide as a cooling agent. The cryoprobe was advanced through the working channel of the bronchoscope till the site of the debrided tissue and freezing was switched on for 3–4 s and the probe within the FOB was extracted *in toto* catching the extracted tissue to its tip. In cases with foreign bodies impacted in the airways, electrocautery debridement was done first to explore the foreign body followed by cryoextraction

Table 1 Speiser score for airway obstruction (Speiser 1990) [11]

Trachea	>50% = 10	<50% = 6	<10% = 2
Main bronchus	>50% = 6	<50% = 3	<10% = 1
Lobar bronchus	>50% = 2	<50% = 1	
Atelectasis	2 per lobe		
Pneumonia	2 per lobe		

of the FB. The FOB was reintroduced more than one time after cryoextraction without the need for intubation, laryngeal mask or rigid bronchoscope.

The patients were monitored for 24 h for the possible complications as bleeding, hypoxemia, and pneumothorax.

Evaluation of response after therapy

- (1) Subjective evaluation by recording the changes in patients' symptoms, performance status, and quality of life.
- (2) Objective evaluation by bronchoscopic, radiologic, and functional evaluation as follows:
 - (a) Bronchoscopic evaluation: according to Speiser's obstruction scoring and achievement of the airway patency was evaluated according to response evaluation criteria in solid tumors (revised RECIST) (Table 2).
 - (b) Radiological evaluation was done with chest radiography and computed tomography scan.
 - (c) Functional evaluation: with spirometry measuring FEV₁, FVC, and FEV₁/FVC.

Statistical analysis

Data was analyzed using SPSS (Statistical Package for Social Sciences) version 15 (International Business Machines Corporation, New York, USA). Qualitative data was presented as number and percent. Comparison between groups was done by χ^2 -test. Quantitative data was presented as mean \pm SD. Student *t*-test was used to compare two groups. *P* value less than 0.05 was considered to be statistically significant.

Results

This prospective study included 22 patients with airway obstruction (15 males and seven females), with age range from 13 to 80 years and mean of 50.5 \pm 18.3 years; 14 of them were of malignant etiology,

92.9% of malignant patients were non-small-cell lung cancer and eight patients of nonmalignant group were postintubation and tracheostomy tracheal stenosis in four cases, foreign body with granulation tissue was present in three (37.5%) cases, and benign tumor in one (12.5%). The trachea and main bronchus were obstructed in two (9.1%) patients, main bronchus in 10 (45.5%) patients, and lobar bronchus in 10 (45.5%) patients. Number of sessions of endobronchial therapy was from one to three. One session was applied to 14 out of 22 patients (63.6%), whereas two sessions were applied to seven (31.8%) patients and only one patient was treated with three sessions.

Figure 1 shows significant improvement in dyspnea, hemoptysis, cough, postobstructive pneumonia, and performance scale after electrocautery and cryoextraction in nonmalignant group (*P* = 0.015, 0.083, 0.024, 0.039, and 0.014), respectively.

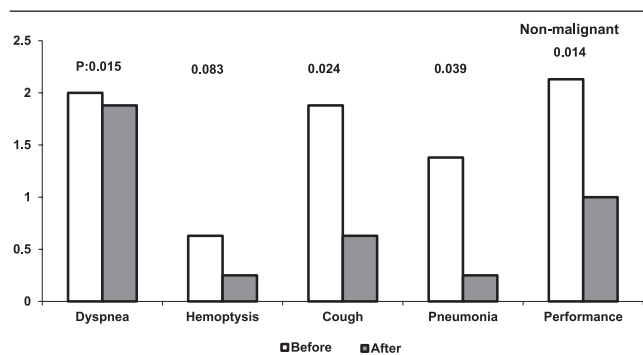
Figure 2 shows significant improvement in dyspnea, hemoptysis, cough, postobstructive pneumonia, and performance scale after electrocautery and cryoextraction in malignant group (group B) (*P* = 0.002, 0.02, 0.001, 0.317, and 0.001), respectively.

Figure 3 shows the effect of interventional bronchoscopy upon some spirometric parameters. All the measured variables were improved after the end of the procedure in malignant group more than

Table 2 Response evaluation criteria in solid tumors (revised RECIST) [12]

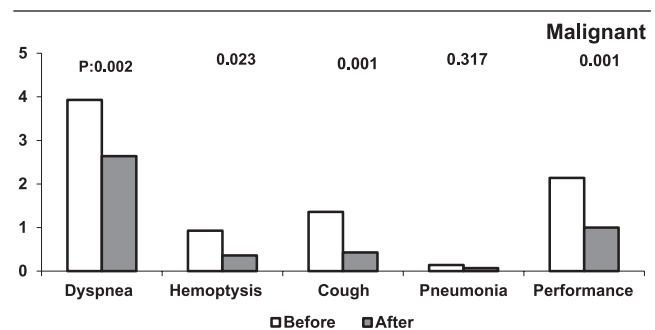
Good response	More than 50% increase in caliber of the lumen
Partial response	25–50% increase in the caliber of the lumen
No response	Less than 25% increase in the caliber of the lumen
Progressive disease	A 25% or more increase in the size of one or more measurable lesions or the appearance of new lesions

Fig. 1



Dyspnea, cough, hemoptysis, postobstructive pneumonia, and performance scores before and after treatment in nonmalignant group (group A).

Fig. 2



Dyspnea, cough, hemoptysis, postobstructive pneumonia, and performance scores before and after treatment in malignant group (group B).

nonmalignant group as the malignant patients had poor spirometric parameters before the study.

Table 3 shows that nonmalignant patients (four out of eight) showed radiological improvement as regard to chest computed tomography, meanwhile three out of 14 patients showed radiological improvement in malignant group.

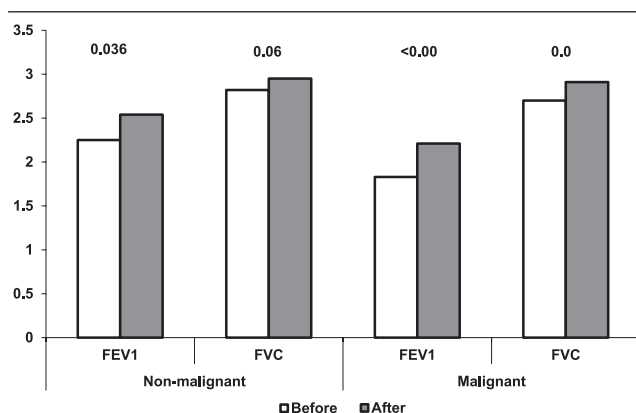
Table 4 shows significant improvement ($P = 0.003$) in bronchoscopic score (Speiser's obstruction scoring system) after the end of procedure in malignant group with less significant improvement as compared with nonmalignant group ($P = 0.012$). Bronchoscopic response according to criteria for evaluation of therapeutic effects (revised RECIST) shows that all the patients in nonmalignant group showed favorable response with most of them and seven (87.5%) showed good response, whereas in malignant group 11 (78%) patients showed favorable response and five (35.7%) of them showed good response. Meanwhile only three (21.4%) patients showed no response.

Table 5 shows the incidence of complications after interventional bronchoscopy. There were no deaths, four (18.01%) patients only had complications; one had rapid atrial fibrillation, one bleeding, and two needed prolonged mechanical ventilation (Figs. 4 and 5) show the bronchoscopic view before and after the procedure.

Discussion

A variety of benign and malignant diseases may result in endoluminal lesions. Depending on the extent and location of an endoluminal lesion, patients may exhibit significant symptoms of dyspnea, cough, postobstructive atelectasis, and hemoptysis. Removing or decreasing the overall size of the endobronchial lesion may improve a patient's symptoms, quality of life, and life expectancy [13].

Fig. 3



FEV₁ and FVC in both groups before and after treatment.

Table 3 Collective data of chest computed tomography findings before and after the procedure in both groups separately

Lesion	Nonmalignant (group A)		Malignant (group B)	
	Before [n (%)]	After [n (%)]	Before [n (%)]	After [n (%)]
No abnormality detected (NAD)	—	4 (50)	—	1 (7.1)
Mass	—	—	6 (42.8)	8 (57.4)
Collapse	2 (25)	1 (12.5)	3 (21.4)	2 (14.2)
Mass + collapse	—	—	3 (21.4)	1 (7.1)
Pneumonia	3 (37.5)	—	—	—
Not done	3 (37.5)	3 (37.5)	2 (14.2)	2 (14.2)
Total	8 (100)	8 (100)	14 (100)	14 (100)

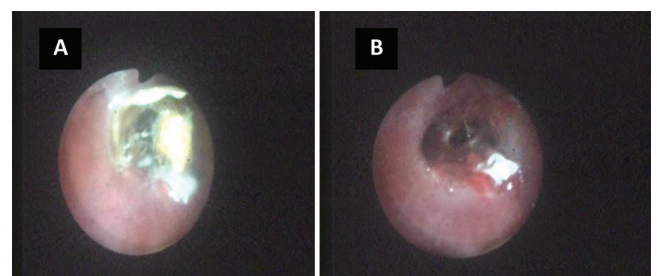
Table 4 Assessment of bronchoscopic score (Speiser's obstruction scoring system) and criteria for evaluation of therapeutic effects (revised RECIST) before and after the interventional procedures in both groups

Response	Group A: nonmalignant		Group B: malignant	
	Before	After	Before	After
Bronchoscopic Score Median (min–max)	5.5 (1–12)	1 (1–4)	3.5 (2–12)	1 (1–12)
P value	0.012		0.003*	
Therapeutic response [n (%)]				
Good	7 (87.5)		5(35.7)	
Partial	1 (12.5)		6 (42.8)	
No response	—		3 (21.4)	

Table 5 The incidence of complications after the interventional bronchoscopic procedures among all the studied patients

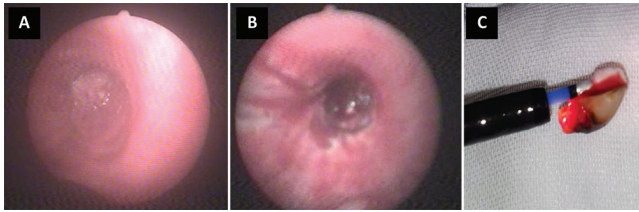
Complications	n (%)
No complication	18 (81.8)
Hypoxemia	2 (9.1)
Arrhythmia	1 (4.5)
Bleeding	1 (4.5)
Mortality	0 (0)
Total	22 (100.0)

Fig. 4



35 year-old female presented with persistent dry cough for 1 week with history of aspiration of part of date, treated with one session of cryotherapy used: (a) fiberoptic bronchoscopy (FOB) snapshot before intervention showing the foreign body impacted at bronchus intermedius and (b) after intervention showing patent bronchus intermedius.

Fig. 5



A 63 year-old male, ex-smoker presented with progressive dyspnea and hemoptysis. Fiberoptic bronchoscopy (FOB) revealed a cauliflower mass totally obstructing left main bronchus which was diagnosed as adenocarcinoma, after two sessions of interventional bronchoscopy 1 week apart, both electrocautery and cryotherapy were used: (a) FOB snapshot before intervention showing endobronchial mass obstructing the left main bronchus, (b) after intervention showing recanalized left main bronchus, and (c) tip of FOB and the cryoprobe attached to a large piece of the extracted tumor.

Our study was planned to assess the efficacy and safety of sequential use of cryoextraction and electrocautery in achievement of airway patency which may provide answers for many questions about the impacts of interventional bronchoscopic modalities as palliative tools in patients with airway obstruction that may be caused by lung cancer and variety of nonmalignant causes.

Twenty-two patients, 15 males and seven females, whose age ranged from 13 to 80 years with a mean age of 50.5 ± 18.3 years were recruited in this study; current smokers account for 27.3% of the studied patients. The included patients were categorized according to the etiology of airway obstruction into eight patients with nonmalignant (group A) and 14 patients with malignant causes (group B).

Our study, included 14 patients with malignant airway obstruction (group B); 13 patients had bronchogenic carcinoma and one patient had lymphoma, whereas the nonmalignant group (group A) included eight patients, of which four patients were with secondary tracheal stenosis caused by prolonged endotracheal intubation or secondary to tracheostomy, one patient with endobronchial benign tumor, and three patients with foreign body with granulation tissue were included.

In our study, number of sessions ranged from 1 to 3, with most patients (14/22) required in one session. The duration of session was from 20 to 45 min with a mean of 30 min.

In our study, the percentage of improvement of dyspnea was significant as the degree of improvement in the mean grade of dyspnea was from 3.9 ± 0.9 to slight category of 2.4 ± 0.9 . It was significant after intervention ($P < 0.0001$). A total of 59.1% of the patients improved from grade 4 and 5 to (50%) grade 1 and 2.

Dyspnea improved in 73% of patients in a study conducted by Sutedja and Postmus [14] who discussed various bronchoscopic techniques, in 67% of patients of a study conducted by Homasson [15] who studied endobronchial electrocautery, in 41.7% of patients in a study conducted by Mohammad [16] who studied cryotherapy, in only 37% of patients in the study of Walsh *et al.* [7] who studied cryotherapy, in 25% of patients in the study of Abdel Salam [17] who studied argon plasma coagulation for achievement of airway way patency, and in 50.5% of patients in the study of Asimakopoulos *et al.* [18] who studied cryotherapy for obstructive, symptomatic, and malignant endobronchial tumors.

In our study, there was a significant improvement in hemoptysis in 62.5% of patients with hemoptysis in nonmalignant group. In malignant group, there was an improvement in 53.3% of the patients. Compared with the result reported by Maiwand [19] there was an improvement in control of hemoptysis in 76.4% of symptomatic patients after cryotherapy, compared with Asimakopoulos *et al.* [18] who reported 61.9% of patients had reduction or cessation of hemoptysis after cryotherapy, and compared with the study by Abdel Salam [17] reported an improvement in hemoptysis in argon plasma coagulation (APC) treated cases was 83%. The cause of improvement of hemoptysis in patients with malignant or nonmalignant obstruction may be due to the coagulation of blood vessels traversing the obstructing lesions.

In our study there was a significant reduction of cough score in 95.3% of patients; these results were better than described by Maiwand and Asimakopoulos [20] who reported reduction of cough score in 69% of patients after treatment. In our study, cough intensity decreased significantly ($P < 0.0001$) in all symptomatic patients. In 11 (50%) patients cough disappeared completely. Compared with Hussein *et al.* [21] cough intensity decreased significantly ($P < 0.0001$) in all the patients.

The slight difference between the above studies and the current study may be due to the effect of usage of two modalities rather than one modality and number of the studied patients or the stage of the disease.

As regard to the KPS, there was a significant improvement from 60 to 80 in both groups A and B ($P < 0.001$ and $P = 0.001$), respectively when compared with that before treatment. These results were in agreement with Maiwand and Asimakopoulos [20] who reported improvement in Karnofsky scale treated with cryotherapy with significant improvement ($P < 0.05$) of KPS from 60 to 75 after treatment also; Asimakopoulos *et al.* [18] reported that group A included 172 patients

who underwent at least two sessions of cryotherapy showed change in KPS from 67.7 to 74.6 ($P = 0.001$). Group B included 157 patients who underwent only one session of cryosurgery showed a significant change in KPS from 67.6 to 73.6 ($P = 0.001$). These results are similar to that reported by Amer *et al.* [22] who assessed the effect of electrocautery and APC in management of endobronchial lesions which showed a significant improvement in performance scale ($P < 0.05$) and ($P < 0.01$) in both studied groups treated with electrocautery and APC, respectively. Improvement in KPS is an indication of improvement of quality of life, this may be due to reduction of tumor burden, also performance status is the one of the best factor for identifying individuals who can benefit from palliative treatment

As regard to functional response there was highly significant improvement ($P = 0.0003$) in spirometric PFTs ($FEV_1\%$, $FVC\%$, and FEV_1/FVC). All the measured three variables significantly improved; $FEV_1\%$ was the most markedly improved parameter ($P < 0.001$). In a study conducted by Sutedja *et al.* [23], PFTs were obtained in eight patients with two patients only having greater than a 15% improvement from baseline values. In a study conducted by Ledingham and Goldstraw [24] all the 11 patients improved symptomatically. $FEV_1\%$ improved in all 11 patients with varying degrees from 30 to 120% (mean 69%). A study conducted by Amer *et al.* [22] showed a significant improvement in $FEV_1\%$ ($P < 0.01$), in $FVC\%$ ($P = 0.05$), and in FEV_1/FVC ($P = 0.01$). A study conducted by Asimakopoulos *et al.* [18] showed an increase in the mean $FEV_1\%$ in both group A and B from 1.36 to 1.43 l ($P = 0.13$) and from 1.45 to 1.49 l ($P = 0.43$), respectively; the mean $FVC\%$ improved in both group A and B from 1.89 to 2.02 l ($P = 0.001$) and from 2.07 to 2.11 l ($P = 0.38$), respectively. The variation in results can be attributed to the type of patient illness (benign vs. malignant), the degree of airway obstruction, and the presence of concomitant diseases as chronic obstructive pulmonary disease.

A slight difference between the above studies and the current study may be due to the effect of usage of two modalities rather than one modality and number of the studied patients or the stage of the disease.

As regard to response score of bronchoscopy, response was assessed by Speiser's obstruction scoring system showing significant improvement in both A and B groups from 5.5 to 1 ($P = 0.012$) in group A and from 3.5 to 1 ($P = 0.003$) in group B. These results were similar to that reported by Safwat *et al.* [25] in which Speiser's obstruction score decreased from 5.20 before treatment to 2.47 ($P = 0.001$) after treatment. While

Sindhvani *et al.* [26] studied role of endobronchial electrocautery in management of neoplastic central airway obstruction on seven cases on whom Speiser's obstruction scored 10.7 and improved to 6.7 after treatment.

Revised RECIST was used as another parameter for assessing therapeutic response after treatment; in our study most of the patients 12 (54.5%) showed good response, whereas seven (31.8%) patients showed partial response. Meanwhile only three (13.6%) patients showed no response. These results are comparable with the study conducted by Safwat *et al.* [25] that included 15 patients with endobronchial obstruction treated with intratumoral chemotherapy out of those patients, seven (46.7%) showed good response, whereas five (33.3%) patients showed partial response. Meanwhile only three (20%) patients showed no response. Hetzel *et al.* [27] studied the role of cryocanalization in achieving airway patency on 60 patients reported that complete recanalization was achieved in 37 (61%) patients. Thirteen (22%) patients' treatment was rated as partially successful and 10 (17%) patients' treatment was unsuccessful.

As regard to the radiological response in the present study, in group A there was a significant improvement in patients presented with pneumonia [3/8 (37.5%)] before treatment with 100% response. In group B [3/14 (21.4%)] patients presented with lung collapse, only one of them showed improvement. These results were in agreement with Safwat *et al.* [25] nine (60%) of the patients had pneumonia before treatment which improved after treatment to three (20%) and 14 (93.3%) of them had collapse that improved after treatment to nine (46.7%).

In our study, 4/22 (18.1%) of the patients treated were associated with complications and no mortality, one with rapid atrial fibrillation, and two patients developed marked hypoxemia that required assisted mechanical ventilation, whereas one patient complicated with bleeding and all of them were managed and the patients improved. Asimakopoulos *et al.* [18] reported bleeding in six (3.5%) patients, three (1.7%) patients had new onset of atrial fibrillation, and respiratory distress in four (2.3%), whereas bleeding was reported in 4/38 (10.5%); excessive cough occurred in 1/38 (2.6%) as reported by Coulter and Mehta [28]. The difference between the above studies and the current study in complications especially hemoptysis may be because of the effect of usage of electrocautery for hemostasis. The cost of this method was about 40 US\$ and the mean duration was about 30 min. These modalities are cheap when compared with laser therapy.

Conclusion

The sequential use of cryoextraction after electrocautery for re-establishment of central airway patency is an effective, safe, cheap, and rapid method for alleviating symptoms, improving performance, quality of life, and ventilatory functions in patients with central airway obstruction.

Financial support and sponsorship

Nil.

Conflicts of interest

There are no conflicts of interest.

References

- Lee P, Tamm M, Chhahed PN. Advances in bronchoscopy – therapeutic bronchoscopy. *J Assoc Physicians India* 2004; **52**:905–914.
- Kupeli E, Karnak D, Mehta AC. Flexible bronchoscopy. In: Mason RJ, Murray JF, Broaddus VC, Nadel JA, Martin RT, King TE, Talmadge E, Schraufnagel DE, editors. *Murray and Nadel's textbook of respiratory medicine*. 5th ed. USA: Elsevier; 2010. –331.
- Lahm T, Sheksi FD. Update on cryotherapy, brachytherapy, and photodynamic therapy. In: Mathur P, Mehta AC, Beamis J, editors. *Interventional pulmonary medicine*. 5th ed. USA: Informa Healthcare; 2010. 230:–44.
- Altin S, Dalar L, Karasulu L, Cetinkaya E, Timur S, Solmaz N. Resection of giant endobronchial hamartoma by electrocautery and cryotherapy via flexible bronchoscopy. *Tuberk Toraks* 2007; **55**:390–394.
- Koletsis EN, Prokakis C, Karanikolas M, Apostolakis E, Dougenis D. Current role of surgery in small cell lung carcinoma. *J Cardiothorac Surg* 2009; **4**:30–34.
- American Thoracic Society. Dyspnea: mechanisms, assessment and management a consensus statement. *Am J Respir Crit Care Med* 1999; **159**:321–340.
- Walsh DA, Maiwand MO, Nath AR, Lockwood P, Lloyd MH, Saab M. Bronchoscopic cryotherapy for advanced bronchial carcinoma. *Thorax* 1990; **45**:509–513.
- Speiser B, Spratling L. Remote after loading brachytherapy for the local control of endobronchial carcinoma. *Int J Radiat Oncol Biol Phys* 1993; **25**:57–67.
- Muers MF. Quality of life and symptom control. *Eur Respir Monogr* 2001; **17**:305–329.
- Gridelli C, Ardizzone A, Le Chevalier T, Manegold C, Perrone F, Thatcher N, *et al.* Treatment of advanced non-small-cell lung cancer patients with ECOG performance status 2: results of an European Experts Panel. *Ann Oncol* 2004; **15**:419–426.
- Speiser B. Protocol for local control of endobronchial carcinoma using remote after loading HDR brachytherapy. *Acta Sel Brachyther J* 1990; **1**:16–19.
- Eisenhauer E, Therasse P, Bogaerts J, Schwartz L, Sargent D, Ford R. New response evaluation criteria in solid tumors: revised RECIST guideline. *Eur J Cancer* 2009; **45**:228–247.
- Seaman JC, Musani AI. Endobronchial ablative therapies. *Clin Chest Med* 2013; **34**:417–425.
- Sutedja G, Postmus PE. Bronchoscopic treatment of lung tumors. *Lung Cancer* 1994; **11**:1–17.
- Homasson JP. Endobronchial electrocautery. *Semin Respir Crit Care Med* 1997; **18**:535–543.
- Mohammad YA. Evaluation of the role of APC and cryotherapy in management of endobronchial tumors MD thesis]. Egypt: Chest Department, Faculty of Medicine, Assiut University; 2007
- AbdelSalam N. Argon plasma coagulation versus chemotherapy in palliative treatment of inoperable non-small cell lung cancer MD Thesis]. Egypt: Chest Department, Faculty of Medicine, Mansoura University; 2005
- Asimakopoulos G, Beeson J, Evans J, Maiwand MO. Cryosurgery for malignant endobronchial tumors: analysis of outcome. *Chest* 2005; **127**:–2014.
- Maiwand MO. Endobronchial cryosurgery. *Chest Surg Clin N Am* 2001; **11**:791–811.
- Maiwand MO, Asimakopoulos G. Cryosurgery for lung cancer: clinical results and technical aspects. *Technol Cancer Res Treat* 2004; **3**:143–150.
- Hussein RM, Korraa EA, Fawzy MA, Sileem AE. Prognostic factors for bronchoscopic electrocautery and/or argon plasma coagulation in patients with central airway obstruction. *Egypt J Chest Dis Tuberculosis* 2013; **62**:501–511.
- Amer WM, Kamel KM, El-Shahat HM, Nafea RM. Role of electrocautery and argon plasma coagulation in management of endobronchial neoplasms. *Zagazig Univ Med J* 2012; **18**:80–86.
- Sutedja G, van Kralingen K, Schramel F, Postmus PE. Fiberoptic bronchoscopic electrosurgery under local anaesthesia for rapid palliation in patients with central airway malignancies: a preliminary report. *Thorax* 1994; **49**:1243–1246.
- Ledingham SJ, Goldstraw P. Diathermy resection and radioactive gold grains for palliation of obstruction due to recurrence of bronchial carcinoma after external irradiation. *Thorax* 1989; **44**:48–51.
- Safwat T, Hosny M, Korraa M, Madkour A, Elghazaly H, Ali T. The efficacy of bronchoscopic intratumoral chemotherapy in palliation of inoperable lung cancer: initial Egyptian experience. *Egypt J Bronchol* 2011; **5**:96–104.
- Sindhvani G, Rawat J, Keserwani V. Role of endobronchial electrocautery in management of neoplastic central airway obstruction: initial experience with seven cases. *Indian J Chest Dis Allied Sci* 2012; **54**:165–168.
- Hetzel M, Hetzel J, Schumann C, Marx N, Babiak A. Cryorecanalization: a new approach for the immediate management of acute airway obstruction. *J Thorac Cardiovasc Surg* 2004; **127**:1427–1431.
- Coulter TD, Mehta AC. The heat is on: impact of endobronchial electrosurgery on the need for Nd-YAG laser photoresection. *Chest* 2000; **118**:516–521.