

A pilot study of chemical ablation of peripheral non-small-cell lung cancer: a novel, effective, safe, and inexpensive method

Mohammad K. El Badrawy^a, Ahmad Y. Badawy^a, Saleh M. Ta-Ema^b, Asem A. Hewidy^a, Mohammad M. El Gamal^a

Introduction Chemical ablation with acetic acid or ethanol is effective against hepatocellular carcinoma and therefore its application in peripheral non-small-cell lung cancer (NSCLC) may be beneficial.

Aim The aim of the study was to assess the efficacy and safety of percutaneous chemical ablation using acetic acid or ethanol in peripheral NSCLC cases.

Patients and methods This was a prospective randomized control study conducted at the Chest and Clinical Oncology Departments, Mansoura, Egypt, from 2011 to 2014.

Thirty-three patients were included with a mean age of 60 years, and were randomly divided into three groups: group A (acetic acid plus chemotherapy group) consisted of nine patients; group B (ethanol plus chemotherapy group) consisted of nine patients; and the control group C (chemotherapy alone group) consisted of 15 patients. Patients who were operable, who had tumors infiltrating the main stem bronchi or mediastinum, and those who refused to complete the study were excluded. Clinical and radiological data were evaluated before treatment and 3 and 6 months after treatment.

Results There was a significant reduction in both cough score and chest pain in group A after 6 months of treatment, in the hemoptysis score in group A and group

B after 6 months of treatment, and in dyspnea score in groups A and B after 3 and 6 months of treatment. There was a statistically significant difference in the tumor response results in both groups after 3 and 6 months of treatment when compared with the control group. There were one or more immediate complications but all were controllable with no mortality. Survival was better in groups A and B than in the control group. The cost of acetic acid and ethanol palliation for each patient was 10 \$US.

Conclusion Chemical ablation is an effective and inexpensive adjuvant palliative treatment for patients with inoperable peripheral NSCLC. *Egypt J Broncho* 2016 10:5–11

© 2016 Egyptian Journal of Bronchology.

Egyptian Journal of Bronchology 2016 10:5–11

Keywords: acetic acid, chemical ablation, ethanol, lung cancer

Departments of ^aChest Medicine, ^bClinical Oncology and Nuclear Medicine, Mansoura University, Mansoura, Egypt

Correspondence to Asem A. Hewidy, MD, Department of Chest Medicine, 15-Beshbeshi St, Hay Elgamaa, Mansoura, Egypt
Tel/fax: +20 100 521 0674;
E-mail: ahewidy@yahoo.com

Received 27 August 2015 **Accepted** 15 September 2015

Introduction

Lung cancer remains one of the leading causes of cancer-related mortality [1]. Approximately 75% of patients with lung cancer presented with locally advanced or metastatic disease at the time of diagnosis [2]. Surgery carries the most favorable response, but in inoperable patients tumor debulking increases survival using multiple modalities in the management of peripheral lung cancer [3].

Many ablative techniques are used for palliation of peripherally situated lung cancer, such as radiofrequency and microwave [4]. Percutaneous chemical ablation is an established, effective technique, easy to perform, requires no specialized equipment for ablation of hepatocellular carcinoma, is well tolerated by patients, and is associated with a low complication rate [5].

Percutaneous ethanol injection is convenient and effective in the treatment of malignant tumors with pleural invasion with little damage and few complications [6]. Acetic acid can also be used for

local ablation therapies and its effect is due to lipid dissolution and the extraction of collagen fiber in the tumor [7].

Study design

This prospective randomized controlled trial considered three arms of treatment for peripheral NCLC: acetic acid (group A), ethanol ablation (group B), and only chemotherapy (the control group, group C). All groups were treated with the conventional regimen of chemotherapy for non-small-cell lung cancer (NSCLC); in addition, group A was treated with acetic acid, group B was treated with ethanol directly injected into the tumor mass, and group C was treated with chemotherapy alone as a control group, evaluated before treatment and at 3 and 6 months after treatment

This is an open access article distributed under the terms of the Creative Commons Attribution-NonCommercial-ShareAlike 3.0 License, which allows others to remix, tweak, and build upon the work non-commercially, as long as the author is credited and the new creations are licensed under the identical terms.

(start of chemical ablation plus chemotherapy or chemotherapy alone). Follow-up was done by monthly visits during the first 6 months and then by phone for 2 years. The patients were randomly selected using the closed envelop method.

Patients and methods

This study was carried out at the Chest Medicine and Clinical Oncology and Nuclear Medicine Departments, Mansoura University Hospitals, during the period from April 2011 to May 2014. The study included 38 patients (31 men and seven women); only 33 of them completed the study (28 men and five women) with peripheral NSCLC of different pathological subtypes (18 with adenocarcinoma, 11 with squamous cell carcinoma, and four with large cell carcinoma). Their ages ranged from 40 to 76 years, with a mean of 60.10 ± 7.82 years.

Ethical approval had been obtained from the Medical Research Ethics Committee of the Faculty of Medicine, Mansoura University. Patients signed written consent forms after receiving a detailed explanation of the study protocol.

Inclusion criteria

This study included symptomatic patients with peripherally situated NSCLC of any histological type who were not candidates for surgery (inoperable or unfit; they were excluded if they became operable or fit because of downstaging) or radiotherapy. Patients must be fit for chemotherapy with adequate bone marrow reserve, such as white blood cell count greater than $3500/\text{mm}^3$, neutrophil count greater than $1800/\text{mm}^3$, hemoglobin greater than 10 g/dl, and hematocrit value greater than 30%.

Exclusion criteria

Operable patients, those with tumors infiltrating the main stem bronchi or the mediastinum, patients with small-cell lung cancer, with lung metastasis, patients who refused to be included or to complete the study, patients with pleural effusion on the same side of the peripheral lung cancer, those with uncorrectable bleeding diathesis, patients with creatinine greater than 1.5 mg/dl and FEV_1 less than 35% of the predicted value, and patients unfit for chemotherapy were excluded from the study.

The study started with 38 patients, but only 33 completed the study. In group A, 12 patients started the study but only nine completed, and in group B 11 patients started the study and only nine of them completed. The patients dropped out of the study because of immediate complications such as chest

pain, hemoptysis, dry irritative cough, or shortening of breath during the technique.

All patients were diagnosed using computed tomography (CT) and/or ultrasound (US)-guided biopsy with an 18-G tru-cut needle, randomly selected for the treatment method using the enclosed envelop method, and subjected to the following:

- (1) *Clinical evaluation*: Thorough medical history with stress on cough, hemoptysis, dyspnea, and chest pain. The four symptoms were scored before the start of treatment and 3 and 6 months after the first session of chemical ablation and chemotherapy. Cough was evaluated according to Belfiore *et al.* (2004) [8] as no cough (0), intermittent cough (1), and persistent cough (3). Hemoptysis was evaluated according to VanKralingen *et al.* (1995) [9] as no hemoptysis (0), blood streaked (1), less than 20 ml/day (2), 20–200 ml/day (3), and 600/day or at least 150 ml in a single attack (4). Dyspnea was evaluated according to the mMRC scoring for dyspnea [10] and chest pain scoring according to the McGill Pain Questionnaire [11] as none (0), mild, requiring no medications (1), discomforting, requiring mild analgesics (2), distressing, requiring strong analgesics (3), horrible, requiring narcotic analgesics (4), and excruciating, not responding to narcotic analgesics (5). Performance status was evaluated using the Karnofsky performance scale according to Muers (2001) [12].
- (2) *Laboratory investigations*: This included complete blood count, liver function tests, kidney function tests, and coagulation profile.
- (3) *Radiological investigations*: This included chest radiography in posteroanterior and lateral views on admission and after every session of chemical ablation.

CT of the chest was performed in the following sequence:

- (a) First chest CT for staging and biopsy with CT-guided tru-cut biopsy.
- (b) Second and third follow-up chest CT scans after 3 and 6 months from the start of chemical ablation.
 - (1) The size of the tumor was measured according to its largest diameter and the radiological response to treatment was assessed according to the modified response evaluation criteria in solid tumors (RECIST) (Table 1).

Pelvic-abdominal ultrasonography, CT of the abdomen, CT of the brain and bone scan were

Table 1 Modified RECIST criteria for evaluation of treatment response [13]

Response	CT mass size	CT mass quality
Complete (two of the following)	Lesion disappearance (scar) less than 25% of the original size	Cyst or cavity formation, low-density entire lesion
Partial (one of the following)	More than 30% decrease in the LD of the target lesion	Central necrosis or central cavitation with liquid density
Stable lesion (one of the following)	Less than 30% decrease in the LD of the target lesion	Mass solid appearance, no central necrosis or cavitation
Progression (two of the following)	Increase of more than 20% in the LD of the target lesion	Solid mass, invasion adjacent structures

CT, computed tomography; LD, largest diameter of lesion.

performed for evaluation of distant metastasis before starting the study and at 6 months as an endpoint of the study.

- (4) Fiberoptic bronchoscopy was performed for all cases once, at the time of diagnosis for evaluation of the bronchial tree and for staging.
- (5) Staging was done according to the seventh TNM staging system for NSCLC as per Goldstraw *et al.* [14], before the start of treatment.
- (6) Chemical ablation was performed according to the technique of Shiina *et al.* [15]. The volume of absolute ethanol of 99.5% concentration was calculated using the formula $V = 4/3\pi(r + 0.5)^3$ and the volume of injected acetic acid of 30% concentration was calculated according to the formula $V = 1/3\{4/3\pi(r + 0.5)^3\}$, where V is the target volume of ethanol, r is the maximum radius of the lesion (in ml), and 0.5 is the correction for the additional 'surgical margin' [16]. The ablation was scheduled for multiple injection sessions, 10 ml once weekly, and the number of ablation sessions varied according to the size of the tumor mass and radiological response. O₂ saturation with pulse oximetry and ECG was monitored before, during, and 24 h after the procedure. After sterilization of the skin with povidone iodine and alcohol, 2–5 ml of 2% lidocaine was injected to anesthetize the skin and subcutaneous tissue, muscles, and pleura along the assumed track of entry. The ablation procedures were guided with CT or US using a 3.5 MHz probe by free-hand technique and the dose was injected slowly over 20 min using a 18-G spinal needle with a single end bore. By varying the length and rotating the needle, the ablative agents were widely distributed within the tumor. The injection was performed from the deep portions to more superficial portions of the tumor mass. Injection was stopped when:
 - (a) A homogenous perfusion of the lesion was observed,
 - (b) A strong resistance to injection was felt,
 - (c) Or when the ablative agent was seen to spill outside the lesion. Then 1–2 ml lidocaine 2% was injected before needle removal.

- (7) *Chemotherapy protocol:* Chemotherapy was continued during the ablation treatment. All patients were treated with cisplatin 75 mg/m² on day 1 plus gemcitabine 1250 mg/m² on days 1 and 8 every 3 weeks [17]. Cisplatin was administered on day 1 through intravenous infusion over ~120 min. Gemcitabine was administered on days 1 and 8 through intravenous infusion over ~30 min. Patients after first-line therapy and with sufficiently good performance score were treated with second-line chemotherapy with docetaxel at 75 mg/m² on day 1 every 3 weeks intravenously as a 1-h infusion.

Statistical analysis

Data were analyzed using SPSS (Statistical Package for Social Sciences), version 15 (International Business Machines Corporation, New York, USA). Qualitative data were presented as number and percentage. Comparison between groups was done by means of the χ^2 -test. Quantitative data were presented as mean \pm SD. The Student t -test was used to compare between two groups. P value less than 0.05 was considered statistically significant.

Results

Group A included nine patients with a mean age of 62.11 ± 7.87 years. Five had adenocarcinoma and four had squamous cell carcinoma. There were four patients at stage IIIa and five patients at stage IIIb. These patients were subjected to intratumoral acetic acid injection (average volume was 57 ml and the average number of sessions was 5) plus systemic chemotherapy.

Group B included nine patients with a mean age of 62.56 ± 6.06 years. Five had adenocarcinoma, three had squamous cell carcinoma, and one had large-cell carcinoma. There were six patients at stage IIIA and three patients at stage IIIb. These patients were subjected to intratumoral ethanol injection (average volume was 62 ml and the average number of sessions was 5) plus systemic chemotherapy.

Group C included 15 patients with a mean age of 57.20 ± 8.27 years; eight had adenocarcinoma, four had squamous cell carcinoma, and three had large-cell carcinoma. There were two patients at stage IIb, five patients at stage IIIa, and eight patients at stage IIIb, respectively. These patients were subjected to systemic chemotherapy alone as a control group.

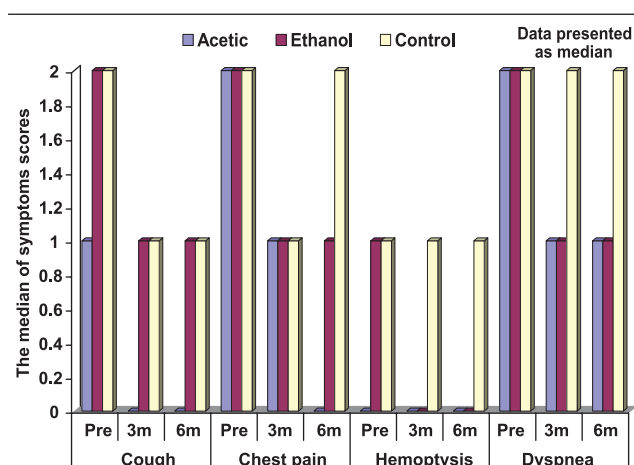
The laboratory tests for complete blood count, liver function, and kidney function were within normal values (Fig. 1).

There was no statistically significant difference between the three groups as regards the median of symptom scores for cough, chest pain, hemoptysis, and dyspnea before the treatment, and all patients were symptomatic. There was a statistically significant reduction in cough score, chest pain, hemoptysis, and dyspnea in both group A and group B (3 and 6 months after treatment vs. before treatment). When compared with the control group, there was a significant reduction in both cough score and chest pain in group A after 6 months of treatment. There was a statistically significant reduction in hemoptysis score in group B after 6 months of treatment and there was a significant reduction in dyspnea score in groups A and B after 3 and 6 months of treatment.

As regards the Karnofsky scale, there was a significant improvement from 63 to 72 in group A ($P=0.009$) and an improvement from 65 to 74 in group B 6 months after treatment when compared with that before treatment ($P=0.035$), and there was a statistically significant difference in group A versus the control group after 6 months of treatment ($P_2=0.006$) and in group B versus the control group after 6 months ($P\leq 0.001$).

The radiological size of the tumor was 27.21 ± 15.74 in group A, 27.21 ± 15.74 in group B, and 31.67 ± 12.06 in group C. In group A, imaging was performed with US in four patients, with CT in four patients, and with both US and CT in one patient. In group B imaging was performed with US in two patients, CT in six patients, and with both US and CT in one patient.

Fig. 1



Comparison between clinical symptoms in the three groups before and after treatment. Data are presented as median.

Figure 2 shows CT morphological changes after five sessions of acetic acid treatment showing cavitating lesions after 6 months.

There were many immediate complications such as chest pain, hemoptysis, dyspnea, wheezes, cough, and pneumothorax, all of which were controlled without ICU admission and no mortality.

Distant metastasis developed in one patient (11.1%) of group A, in two patients (22.2%) of group B, and in five patients (33.3%) of group C. There was no statistically significant difference in tumor metastasis between the three groups.

The 2-year survival rate was 13 patients (72%) in both group A and group B and five patients (33%) in the control group, which was statistically significant ($P=0.025$).

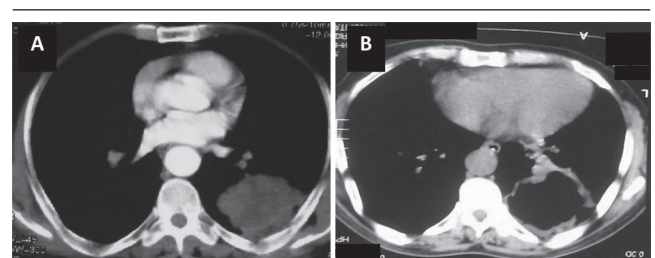
Discussion

Percutaneous chemical ablation with acetic acid injection in 15–50% concentration has stronger necrotizing power compared with pure ethanol [18] and may be equally effective or even superior to ethanol injection in treating small hepatocellular carcinoma [19]. Acetic acid is superior to ethanol in treating tumors with resistance to perfusion with ethanol [7].

Other studies reported combining thermal ablation of radiofrequency (RF) with other ablation therapies, such as intratumoral chemotherapy, transarterial chemoembolization, intratumoral ethanol, or intratumoral normal 0.9% or hypertonic saline solution injection [20].

To our knowledge, this is the first study to evaluate the safety and efficacy of percutaneous image-guided chemical ablation (acetic and ethanol injection) of peripheral NSCLC.

Fig. 2



Case no. 2: A 75-year-old smoker who presented with chest pain and hemoptysis. Computed tomography (CT) revealed left lower lobe mass measuring 6×5 cm diagnosed by CT-guided biopsy as squamous cell carcinoma, after five sessions of acetic acid treatment (volume: 50 cm). (a) Preinjection picture. (b) CT after 6 months showing cavitating lesion.

As regards the clinical response, our results were in agreement with those of Huang *et al.* [6], who studied nine patients with malignancies and pleural or chest wall invasion who were treated with percutaneous ethanol injection; they reported a significant reduction in cough score, chest pain (relieved obviously and pain degree reduced to 0–3), hemoptysis, and dyspnea after 6 months. These results were in agreement with other studies who used another ablative therapy in the treatment of NSCLC: El-Badrawy *et al.* [21] studied 25 patients, 10 of them were treated with combined radiofrequency ablation (RFA) and chemotherapy and they reported a significant reduction in cough score from 1.9 to 0.2 6 months after treatment. Those results were in agreement with the findings of Belfiore *et al.* [8], who studied 32 patients with unresectable primary lung cancer treated with RFA alone and reported reduction of cough score from 1.5 to 1 after 6 months of treatment. In our study, a significant decrease in symptom scores (cough, chest pain, hemoptysis, and dyspnea) was seen, which may be due to greater reduction of tumor size in both groups compared with the control group.

As regards the Karnofsky scale our results were in agreement with Huang *et al.* [6], who reported improvement in Karnofsky performance score, which was over 90, and with the results of El-Badrawy *et al.* [21], who reported a significant increase in the Karnofsky scale versus the control group 6 months after treatment after radiofrequency ablation ($P \leq 0.001$). Improvement in Karnofsky performance scale, which is a measurement of performance status, may be due to reduction in tumor burden. Further, performance status is the single best factor for identifying individuals who can tolerate and benefit from chemotherapy.

There was a statistically significant difference in CT morphological changes in group A and group B after 3 months of treatment when compared with the control group ($P = 0.001$ and 0.003 , respectively) (Table 2). These results were in agreement with those of Lee *et al.* [22], who studied 24 patients with NSCLC who were subjected to RFA and reported CT changes 3 months after treatment: central necrosis without cavitation was reported in eight patients (80%), of which two progressed to solid mass at 6 months' follow-up; necrosis with cavitation was reported in two patients (20%), which persisted at 6 months' follow-up. Our results were also in agreement with Bojarski *et al.* [23], who studied 26 patients with NSCLC treated with RFA and reported that cavitation occurred in 31% of the tumors imaged 3 months after treatment. These cavitated lesions did not become a site for infection and there was no need for long-term antibiotics on follow-up.

There was a statistically significant difference in tumor response in groups A and B after 3 months of treatment when compared with the control group ($P = 0.004$ and 0.036 , respectively). There was a statistically significant difference in tumor response in groups A and B after 6 months of treatment when compared with the control group ($P = 0.016$ and 0.062 , respectively) (Table 3). These results were in agreement with those of Huang *et al.* [6], who reported a significant reduction in tumor size and better local control, and also in agreement with the finding of Yang-Kui *et al.* [24], who reported a reduction in the size of 31 lesions out of 37 lung metastatic lesions in 17 patients who received intratumoral ethanol injection on lung metastasis from liver cancer. Our results were also in agreement with the findings of Masaki *et al.* [25] who reported a reduction in tumor size in three out of five patients with lung cancer who were injected intraoperatively with ethanol directly into the tumor by grasping the lung including the tumor.

As regards the immediate complications of chemical ablation (Table 4), chest pain was controlled by assurance and with paracetamol as a mild analgesic agent. Hemoptysis varied between being blood streaked to being less than 20 ml, and was stopped within 6 h with hemostatic drugs. Seven patients of group A developed wheezy chest; six of them had mild dyspnea. In group B, six patients developed wheezy chest; two of them had mild dyspnea and were relieved with inhaled salbutamol. Pneumothorax was recorded in two patients (22%) in group A and in one patient (11%) in group B. One of them resolved spontaneously with oxygen therapy and two patients were managed with intercostal tube drainage accompanied by surgical emphysema. These results were in agreement with those of Yang-Kui *et al.* [24] who studied 17 patients who received CT-guided intratumoral dehydrated ethanol injection on lung metastasis from liver cancer; pneumothorax was reported in two patients with lung compressed by less than 30%, which self-restored 3 days after pneumothorax drainage. These results were different from those of Zhu *et al.* [26], who performed 129 RFA sessions in 100 patients with inoperable lung tumors and reported pneumothorax in 32% of treatment sessions, as well as pleuritic chest pain (18%), hemoptysis (7%), pleural effusions (12%), and chest drain insertion (20%). The difference between the current study and the above listed studies as regards the rate and type of complications following chemical ablation may be due to the difference in the number of included patients in each study, difference in the skill of the operator, difference in site or size of the tumor, or difference in the ablative techniques used.

Table 2 Computed tomographic morphological changes in the tumor mass after 3 and 6 months of treatment

CT changes	Group A (n = 9) [n (%)]	Group B (n = 9) [n (%)]	Group C (n = 15) [n (%)]	P value
3 months				
Central necrosis	3 (33.3)	2 (22.2)	1 (6.7)	$P_1 = 0.912$
Cavitation	2 (22.2)	2 (22.2)	0 (0)	$P_2 = 0.001^*$
Central necrosis and cavitation	3 (33.3)	3 (33.3)	0 (0)	$P_3 = 0.003^*$
No change	1 (11.1)	2 (22.2)	14 (93.3)	
6 months				
Central necrosis	2 (22.2)	2 (22.2)	1 (6.7)	$P_1 = 0.924$
Cavitation	2 (22.2)	2 (22.2)	0 (0)	$P_2 = 0.001^*$
Central necrosis and cavitation	4 (44.5)	3 (33.3)	0 (0)	$P_3 = 0.003^*$
No change	1 (11.1)	2 (22.2)	14 (93.3)	

P_1 , group A versus B; P_2 , group A versus C; P_3 , group B versus C; * $P < 0.05$, significant.

Table 3 Radiological response in the tumor mass after 3 and 6 months of treatment measured with computed tomography of the chest (modified RECIST criteria) [13]

Radiological response	Group A (n = 9) [n (%)]	Group B (n = 9) [n (%)]	Group C (n = 15) [n (%)]	P value
3 months				
Complete	1 (11.1)	0 (0)	0 (0)	$P_1 = 0.426$
Partial	5 (55.6)	3 (33.3)	0 (0)	$P_2 = 0.004^*$
Stable	2 (22.2)	5 (55.6)	9 (60)	$P_3 = 0.036^*$
Progression	1 (11.1)	1 (11.1)	6 (40)	
6 months				
Complete	1 (11.1)	0 (0)	0 (0)	$P_1 = 0.198$
Partial	6 (66.7)	3 (33.3)	2 (13.3)	$P_2 = 0.016^*$
Stable	1 (11.1)	5 (55.6)	4 (26.7)	$P_3 = 0.062^*$
Progression	1 (11.1)	1 (11.1)	9 (60)	

P_1 , group A versus B; P_2 , group A versus C; P_3 , group B versus C; * $P < 0.05$, significant.

Table 4 Immediate complications after injection of the ablative agents

Complications	Group A (n = 9) [n (%)]	Group B (n = 9) [n (%)]	χ^2	P value
Chest pain	8 (88.8)	9 (100)	1.639	0.200
Cough	8 (88.8)	7 (77.8)	1.727	0.189
Hemoptysis	4 (66.7)	4 (66.7)	2.333	0.311
Wheezes	7 (77.8)	6 (66.7)	0.277	0.599
Dyspnea	6 (66.6)	2 (33.3)	4.444	0.108
Pneumothorax	2 (22.2)	1 (11.1)	1.059	0.303
Surgical emphysema	1 (11.1)	1 (11.1)	0.0	1.0
Mortality	0 (0)	0 (0)	—	—

In the current study, distant metastasis was reported in one patient (11%) in group A, in two patients (22%) in group B, and in five patients (33%) in the control group 6 months after treatment. This was less than that reported by Ambrogi *et al.* [27] who studied 30 NSCLC cases treated with RFA and reported distant metastasis in 39% of patients at a mean follow-up

period of 23.7 months. The difference between the current study and the other study may be the difference in the length of the follow-up period or the number of studied cases.

Conclusion

Chemical ablation is an effective and cheap adjuvant palliative treatment for systemic chemotherapy in patients with inoperable peripherally located NSCLC with tolerable nonserious complications, and it prolongs the longevity of patients.

Financial support and sponsorship

Nil.

Conflict of interest

There are no conflicts of interest.

References

- Massion PP, Carbone DP. Biology of non-small cell lung cancer. In: By, Mason RJ, Murray JF, Broaddus VC, Nadel JA, Martin RT, King TE, Talmadge E, Schraufnagel DE, editors. *Murray and Nadel's textbook of respiratory medicine*. 5th ed. USA: Elsevier; 2010. 571–582.
- Jantz MA, Silvestri GA. Fire and ice: laser bronchoscopy, electrocautery and cryotherapy. In *Thoracic Endoscopy: Advances in Interventional Pulmonology*. Simoff MJ, Sterman DH and Ernst A (eds.). Blackwell Publishing London; 2006. 1. 134–154.
- Dupuy DE, DiPetrillo T, Gandhi S, *et al.* Radiofrequency ablation followed by conventional radiotherapy for medically inoperable stage I non-small cell lung cancer. *Chest* 2006; **129**:738–745.
- Dupuy DE, Mayo-Smith WW, Abbott GF, *et al.* Clinical applications of radio-frequency tumor ablation in the thorax. *RSNA* 2002; **22**:S259–S269.
- Clark TW. Chemical ablation of liver cancer. *Tech Vasc Interventional Rad* 2007; **10**:58–63.
- Huang JH, Fan WJ, Ready N, *et al.* CT-guided percutaneous ethanol ablation in the treatment of malignancies with pleural or chest wall invasion. *Zhonghua Yi Xue Za Zhi* 2008; **88**:3365–3368.
- Ohnishi K, Yoshioka H, Ito S, *et al.* Prospective randomized controlled trial comparing percutaneous acetic acid injection and percutaneous ethanol injection for small hepatocellular carcinoma. *Hepatology* 1998; **27**:67–72.
- Belfiore G, Moggio G, Tedeschi E, *et al.* CT-guided radiofrequency ablation: a potential complementary therapy for patients with unresectable primary lung cancer — a preliminary report of 33 patients. *AJR* 2004; **183**:1003–1011.
- VanKralingen KW, vanKralingen-Heijboer AC, Zimmerman M, *et al.* Management of haemoptysis in a third city hospital a retrospective study. *Tuber Lung dis* 1995; **76**:344B.
- Mahler DA, Wells CK. Evaluation of clinical methods for rating dyspnea. *Chest* 1988; **93**:580–586.
- Melzack R. The short-form McGill Pain Questionnaire. *Pain* 1987; **30**:191–197.
- Muers MF. Quality of life and symptom control. *Eur Respir Monograph* 2001; **17**:305–329.
- Fernando HC, De Hoyos A, Landreneau RJ, *et al.* Radiofrequency ablation for the treatment of non-small cell lung cancer in marginal surgical candidates. *J Thorac Cardiovasc Surg* 2005; **129**:639–644.
- Goldstraw P, Crowley J, Chansky K, Giroux DJ, Groome PA, Rami-Porta R, *et al.* International Association for the Study of Lung Cancer International Staging Committee. Participating Institutions. The IASLC Lung Cancer Staging Project: proposals for the revision of the TNM stage groupings in the forthcoming (seventh) edition of the TNM Classification of malignant tumours. *J Thorac Oncol* 2007; **2**:706–714.
- Shiina S, Tagawa K, Niwa Y, *et al.* Percutaneous ethanol injection therapy for hepatocellular carcinoma in 146 patients. *Am J Roentgenol* 1993; **160**:1023–1028.
- David S, Kwan N, John B, *et al.* Hepatic tumor ablation. *Surg Clin* 2010; **90**:863–876.

- 17 Cardenal F, Lopez-Cabrerizo MP, Anton A, *et al.* Randomized phase III study of gemcitabine–cisplatin versus etoposide–cisplatin in the treatment of locally advanced or metastatic non-small-cell lung cancer. *J Clin Oncol* 1999; **17**:12–18.
- 18 Ohnishi K, Yoshioka H, Ito S, *et al.* Treatment of nodular hepatocellular carcinoma larger than 3 cm with ultrasound-guided percutaneous acetic acid injection. *Hepatology* 1996; **24**:1379–1385.
- 19 Huo TI, Huang YH, Wu JC, *et al.* Sequential transarterial chemoembolization and percutaneous acetic acid injection therapy versus repeated percutaneous acetic acid injection for unresectable hepatocellular carcinoma: a prospective study. *Ann Oncol* 2003; **14**:1648–1653.
- 20 Bloomston M, Binitie O, Fraiji E, *et al.* Transcatheter arterial chemoembolization with or without radiofrequency ablation in the management of patients with advanced hepatic malignancy. *Am Surg* 2002; **68**:827–831.
- 21 EL-Badrawy MKh, Elbadrawy A, Zeidan A, *et al.* Radiofrequency ablation in palliative treatment of nonoperable peripheral non small cell lung cancer. *Egypt J Chest Dis Tuberculosis* 2011; **60**:30–37.
- 22 Lee JM, Jin GY, Goldberg SN, *et al.* Percutaneous radiofrequency ablation for inoperable non-small cell lung cancer and metastases: preliminary report. *Radiology* 2004; **230**:125–134.
- 23 Bojarski JD, Dupuy DE, Mayo-Smith WCT. Imaging Findings of pulmonary neoplasms after treatment with radiofrequency ablation: results in 32 tumors. *AJR* 2005; **185**:466–471.
- 24 Yang-Kui G, Wei-Jun F, Huang J, *et al.* Efficacy of CT-guided intra-tumoral dehydrated ethanol injection on lung metastasis from liver cancer. *Chin J Cancer* 2007; **26**:31.
- 25 Masaki Y, Yamamoto M, Nishimura H, *et al.* Ethanol injection therapy to the lung cancer. *Kyobu Geka*. 1997; **50**:384–388.
- 26 Zhu JC, Yan TD, Glenn D, *et al.* Radiofrequency ablation of lung tumors: feasibility and safety. *Ann. Thorac. Surg* 2009; **87**:1028–1029.
- 27 Ambrogi MC, Lucchi M, Dini P, *et al.* Percutaneous radiofrequency ablation of lung tumours: results in the mid-term. *European Journal of Cardio-thoracic Surgery* 2006; **30**: 177-183.