Assessment of transthoracic sonography in patients with interstitial lung diseases

Suzan S. Sayed[a], Gamal M. Agmy[a], Azza F. Said[b], Ahmed H. Kasem[b]

Aim This study was designed to recognize the sonographic features of interstitial lung diseases (ILD). Furthermore, the possible correlations of these features with the functional and radiological parameters of the disease were assessed.

Patients and methods Forty-two patients with ILD were included; each patient underwent spirometry, Multi Detector CT chest (MDCT) and transthoracic sonography (TS). Fifteen healthy volunteers were also studied as controls.

Results The sonographic features among ILD patients were B lines in 73.8% , abolished lung sliding in 23.8%, irregular and thickened pleura in 47.6%and 35.7% respectively and subpleural lesions in 38.1%.Increasing distance between the B lines was negatively correlated with both of Forced Vital Capacity % predicted , ground glass opacities and positively correlated with reticular opacities patterns on MDCT chest.

Conclusion TS can be used as an additional imaging method for assessment of ILD and as a marker to estimate the severity of disease.

Egypt J Bronchol 2016 10:105–112

Egyptian Journal of Bronchology 2016 10:105–112

Keywords: interstitial lung disease, multi-detector CT, transthoracic sonography, B lines

[a]Department of Chest Diseases, Faculty of Medicine, Assiut University, Cairo, [b]Department of Chest Diseases, Faculty of Medicine, Minia University, Cairo, Egypt

Correspondence to Azza F. Said, MD, Department of Chest Diseases, Faculty of Medicine, Minia University, 6111 Minia, Egypt. Tel: +20 862 5846; fax: 0862362502;
e-mail: azza20022@yahoo.com

Received 9 February 2016 **Accepted** 1 March 2016

Introduction

Chest ultrasonography has many uses, both diagnostic and interventional. It is used in the diagnosis of diseases of the pleural space, such as pleural effusion, pleural thickening, pleural masses, and pneumothorax. It is also used in the diagnosis of diseases caused by lung parenchymal lesions, such as pneumonia, lung abscesses, neoplasms, pulmonary embolism, and arteriovenous malformations [1].

Interstitial lung disease (ILD) refers to a group of disorders that are characterized by varying combinations of inflammation and fibrosis involving the space between the epithelial and endothelial basement membranes [2].

High-resolution computed tomography (HRCT) should be considered the gold standard technique for the diagnosis of ILD, and many other noninvasive and invasive procedures concur in clinical practice to define and characterize ILD, such as chest radiography, laboratory and serological tests (e.g. angiotensin-converting enzyme and antinuclear antibodies), pulmonary function tests, bronchoscopy with bronchoalveolar lavage, and transbronchial lung biopsy [3].

However, some studies have demonstrated that transthoracic sonography (TS), as a consequence of its well-known advantages (absence of radiation exposure, ready availability, and cost-effectiveness), can play a complementary role in the diagnosis of ILD, especially when chest radiography or HRCT is not readily available or undesirable – for instance during pregnancy [4]. Moreover, TS can be useful in monitoring the course of the disease in patients with confirmed ILD (thus avoiding unnecessary overload of radiation exposure).

One study found that lung ultrasound can be used as a simple screening method for detection of ILD in very early systemic sclerosis [5].

Aim

This study was conducted to evaluate the TS features in patients with ILDs. Moreover, the possible correlations of sonographic findings with functional and radiological parameters of ILDs were assessed.

Patients and methods

This study was conducted in Minia University Hospital during the period from October 2014 to September 2015 on 42 patients with ILDs. The study protocol was approved by the Ethics Committee of the Faculty of Medicine, Minia University, and informed consent was obtained from all patients.

Diagnosis was based on the presence of dyspnea, cough, and other chest symptoms. Physical examination revealed inspiratory rales and clubbing in some cases with restrictive ventilatory defect on pulmonary function tests (PFTs) [6] on using ZAN 300 (Biomedica, Germany).

Results were obtained for forced vital capacity (FVC), forced expiratory volume in 1 s (FEV_1), ratio of FEV_1/FVC (FEV_1/FVC%), forced expiratory flow at 25–75% of vital capacity, and peak expiratory flow. Values were obtained while the patient exerted his or her maximum effort to avoid any expected error in diagnosis. The absolute values and the percentages of spirometric parameters predicted from the participant's age, sex, and height were calculated. Eight patients were excluded (four due to obesity and four due to inability to undergo pulmonary function tests).

Restrictive ventilatory defect was defined on spirometric findings of FEV_1/FVC greater than 70% predicted and FVC less than 80% predicted [7].

Multidetector computed tomography (MDCT) of the chest without contrast using GE bright speed 16 detector/slice (General Electric, Germany) was performed on all patients. Computed tomography (CT) patterns were recorded as reticular changes, ground glass, nodules, honey combing, mosaic, and traction bronchiectasis. Any abnormalities on MDCT of the chest in the form of areas of consolidation and pleural effusions were also evaluated.

Twelve cases were diagnosed as idiopathic pulmonary fibrosis (based on exclusion of other known causes of ILDs and usual interstitial pneumonia pattern on HRCT in the form of basilar, subpleural reticular opacities, and honeycombing with or without traction bronchiectasis) [8]. Ten cases had hypersensitivity pneumonitis (based on the history of exposure to organic agents and HRCT findings of ground-glass opacity, centrilobular nodules, mosaic areas, and traction bronchiectasis in chronic cases) [9]. The HRCT of eight cases was consistent with nonspecific interstitial pneumonia in the form of ground-glass opacities with or without areas of consolidation, and reticular changes sparing subpleural areas [10]. Five cases had sarcoidosis stage II–IV (based on peripheral lymph node biopsy) and seven cases had lymphangitis carcinomatosis (four cases due to bronchogenic carcinoma and three cases secondary to hematologic malignancies).

Transthoracic sonography

It was performed on all patients using Philips ClearVue 350 (USA) using both 2.5–5 MHz convex probe and 7.5–10 MHz linear probe for lung and pleural examinations. Patients were investigated in the supine or sitting position with their arms raised above heads to widen the intercostal space. Lung ultrasonography was performed in a series of scan lines along the chest wall with the transducer oriented either perpendicular or transverse to the chest wall. It was done using grayscale (B-mode), time-motion (M-mode), and color Doppler. TS was performed blindly with no knowledge of the clinical and radiological findings.

The following were assessed [11]:

Presence or absence of lung sliding (the 'to-and-fro' dynamic movement of the lung during respiration that was visible at the pleural line).

Artifact type: A lines=anterior predominant bilateral A lines (horizontal hyperechoic lines below and parallel to the pleural line and associated with lung sliding).

B lines=anterior predominant bilateral B lines (vertical hyperechoic lines arising from the pleural line that spreads all the way to the edge of the screen without fading) erasing A lines and moving with lung sliding. It is also called 'comet tails' artifact. The distance between each of two adjacent B lines close to the pleural line was measured and expressed in milliliters; B3 and B7 means that the distance between two B lines was 3 and 7 mm, respectively [12].

AB lines=anterior predominant B lines at one side, and predominant A lines at the other side [13].

O line (non-A, non-B) defined as absence of any visible artifact, either horizontal or vertical, arising from the pleural line [14].

Assessment of pleura as regards pleural thickness, pleural surface (either smooth, irregular or interrupted), and presence of pleural effusion.

Pleural thickenings are defined as focal or diffuse echogenic lesions arising from the visceral or parietal pleura that are greater than 3 mm in width with or without an irregular pleural surface [15].

Pleural effusion was seen as a homogeneous, anechoic space between the parietal and visceral pleura [15]. Subpleural parenchymal findings as hyoechoic or isoechoic lesions were also recorded. The echogenicity

of pleural fibrosis or thickening varies. It may be hypoechoic, which makes distinction from small pleural effusion problematic. A finding that favors fibrosis is absent respiratory movement of the lung pleural interface and the findings on color Doppler. Pleural fluid provides a color Doppler signal as small reflectors within the fluid move. Color signal from pleural fibrosis is generally absent [16].

The study also included 15 healthy volunteers as controls matched in age and sex with the studied patients. They had no history of previous respiratory diseases and their chest radiographs were normal. Pulmonary function tests and thoracic sonography were performed for them.

Statistical analysis

Data entry and analysis was performed using SPSS Inc. (Chicago, Illinois, USA), version 19 (Statistical Package for Social Science). Data were presented as number, percentage, mean, and SD. The χ^2-test was used to compare between qualitative variables. Differences were considered statistically significant when P values were less than 0.05. Bivariate correlation using Spearman's test was used.

Results

Table 1 shows descriptive and clinical data among patients of ILD and controls. Table 2 shows PFTs and MDCT findings among the studied participants. Table 3 shows the sonographic findings among patients of ILD and controls. It was found that patients with ILD had a significant % of B lines compared with controls (73.8 vs.0%, P=0.001), whereas healthy controls had a significant percentage of A and O lines compared with ILD patients (66.7 vs.7.1%, P=0.002; 33.3 vs.9%, P=0.009, respectively). Abolished lung sliding was significantly higher in ILD patients versus controls (23.8 vs. 0%, P=0.001). Regarding pleural abnormalities, thickened pleura and pleural effusion were significantly higher among patients than among controls (35.7 vs. 0%, P=0.002, 33.3 vs. 0%, P=0.001 respectively). The subpleural parenchymal lesions were significantly higher in ILD patients compared with controls (38.1 vs.0%, P=0.007). Their sizes ranged from 15 to 20 mm. Ten of these lesions were hypoechoic and six were isoechoic (Figs 1–3).

Regarding the correlation between B-line distance and pulmonary function tests, it was found that increasing B-line distance had a significant negative correlation with FVC% predicted only (r=−0.46, P=0.003) with no correlations with FEV_1 or FEV_1/FVC (Fig. 4).

Figure 5 shows that there was a significant positive correlation between increasing B-line distance and the reticular pattern on MDCT (r=0.51, P=0.004). In contrast, there was a significant negative correlation between B-line distance and ground-glass opacity (r=−0.41, P=0.02) (Fig. 6).

Considering the correlation of other sonographic findings of ILD with functional and radiological

Table 1 Descriptive and clinical data among the studied participants

Variables	Studied patients (n=42)	Controls (n=15)
Age (years)		
Mean±SD	49.6±12.7	45.5±5.6
Sex [n (%)]		
Male	19 (45.2)	8 (53.3)
Female	23 (54.8)	7 (46.7)
Symptoms [n (%)]		
Dyspnea	38 (90.5)	–
Dry cough	14 (33.3)	
Productive cough	22 (52.4)	
Chest pain	12 (28.8)	
Wheezing	11 (26.2)	

Data are presented as n (%).

Figure 1

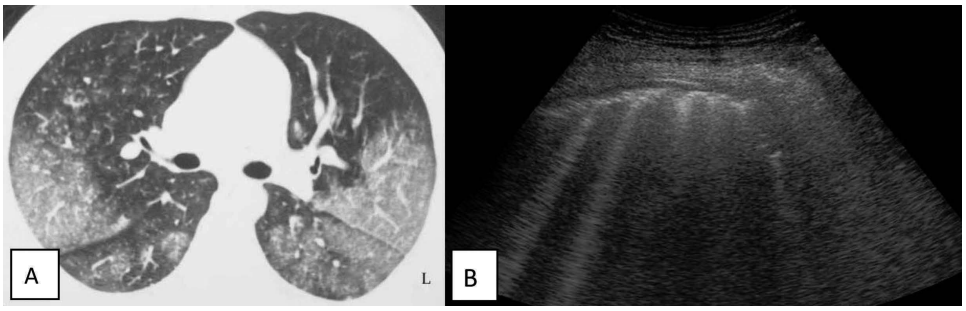

(a) Multidetector computed tomography (MDCT) of the chest in a patient with interstitial lung disease (ILD) showing bilateral ground-glass opacity. (b) Lung ultrasound of the same patient showing multiple B lines arising from a thickened and irregular pleural line.

Table 2 PFTs and MDCT findings among the studied patients

Variables	ILD patients (*n*=42)	Controls (*n*=15)	*P*
PFTs			
FVC% pred.	53.46±15.5	91.1±2.3	0.001*
FEV_1% pred.	62.77±17.5	85.6±5.3	0.002*
FEV_1/FVC	73.25±16.5	78.1±7.1	0.03*
MDCT findings [*n* (%)]			
GGO	16 (38.1)	–	
Reticular	13 (30.9)		
Honeycombing	12 (28.8)		
Nodular	7 (16.7)		
Mosaic pattern	4 (9)		
Traction bronchiectasis	4 (9)		
Pleural effusion	11 (26.2)		
Consolidation	6 (14.3)		

Data are presented as mean±SD for PFTs, *n* (%) for MDCT.
FEV_1, forced expiratory volume in 1 s; FVC, forced vital capacity; GGO, ground-glass opacity; HRCT, high-resolution computed tomography; ILD, interstitial lung disease; MDCT, multidetector computed tomography; PFT, pulmonary function test.
**Significant.

Table 3 Sonographic findings among the studied patients

Sonographic findings	ILD patients (*n*=42)	Controls (*n*=15)	*P*
Artifact type [*n* (%)]			
B line	31 (73.8)	0	0.001*
A line	3 (7.1)	10 (66.7)	0.002*
AB lines	3 (7.1)	0	0.08*
O lines	4 (9)	5 (33.3)	0.009*
Lung sliding [*n* (%)]			
Present	32 (76.2)	15 (100)	0.03*
Abolished	10 (23.8)	0	0.001*
Pleural line [*n* (%)]			
Thickened	15 (35.7)	0	0.002*
Smooth	22 (52.4)	12 (80)	0.06*
Irregular	20 (47.6)	3 (20)	0.08*
Pleural effusion	14 (33.3)	0	0.001*
Subpleural parenchymal lesions [*n* (%)]			
Present	16 (38.1)	0	0.007*
Absent	26 (61.9)	15 (100)	0.006*

Data are presented as *n* (%).
ILD, interstitial lung disease.
*Significant.

parameters of the disease, Table 4 shows that abolishing lung sliding is positively correlated with the reticular changes on MDCT, with no other correlations.

Discussion

The present study was designed to detect the sonographic features in patients with ILDs. On analyzing our findings, we found that the most predominant artifact type among patients with ILD was B lines (73.8%), followed by O lines (9%), A lines and AB lines (7.1% for each). Thirty-three and 47.6% of the studied patients had thickened and interrupted or irregular pleura, respectively. Abolished lung sliding was present in 23.8% of ILD patients (Table 3). A previous study of the sonographic lung surface in 12 patients with pulmonary sarcoidosis revealed that all patients had a rough, irregular pleural surface accompanied by an increase in comet tail artifacts [17].

Gargani *et al.* [18] found that 51% of systemic sclerosis patients had B lines as a hallmark of interstitial pulmonary fibrosis.

Under normal nonedematous or fibrotic conditions, bilateral B lines or comet tails are absent because no acoustic mismatch occurs as the ultrasound beam passes through the subpleural space [19]. Thus, none of the controls had bilateral B lines.

Figure 2

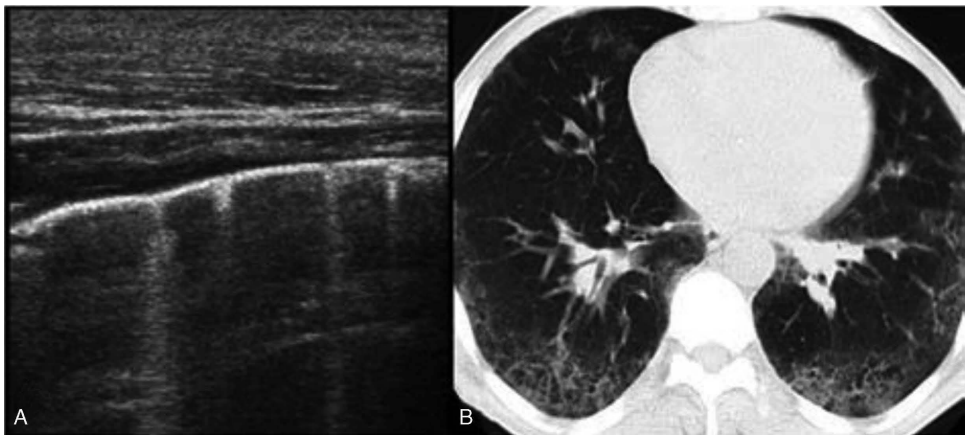

(a) Lung ultrasound showing four B lines arising from the pleural line with distance between the two B lines of about 7 mm. (b) Multidetector computed tomography (MDCT) of the chest showing bilateral subpleural reticular and honeycomb shadows in a patient with idiopathic pulmonary fibrosis.

Figure 3

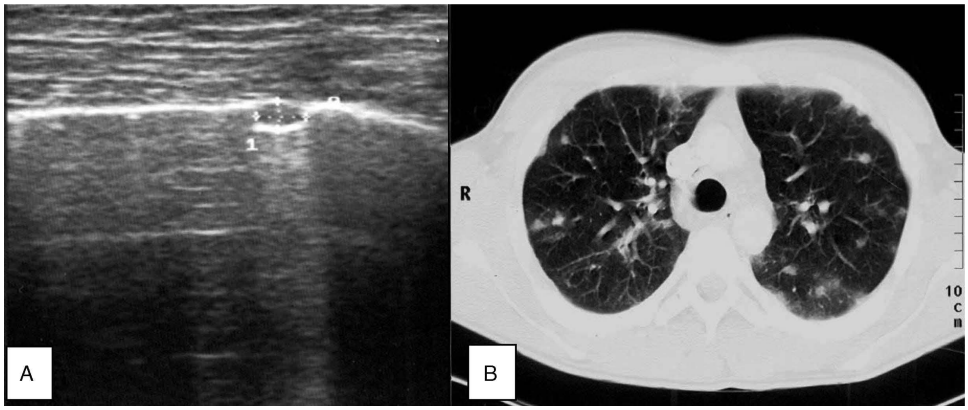

(a) Lung sonography of a case of sarcoidosis, showing a rounded subpleural hypoechoic lesion. (b) Corresponding chest computed tomography (CT), showing multiple subpleural nodules in both upper lobes.

B lines are generated by the reflection of the ultrasound beam from thickened subpleural interlobular septa. In patients with heart failure, interlobular septa are thickened by water, and in pulmonary fibrosis, interstitial lobular septa are thickened by collagen tissue accumulation [20]. Histologically the interlobular septa are 7 mm apart when they reach the subpleural space, and this is roughly the distance between the origins of individual comet tails at the pleural line [21].

TS can detect ILD if the interstitium of the peripheral lung is involved [22]. The typical TS findings associated with pulmonary fibrosis include [23] the following: fragmentation and irregular thickening of the pleural line, especially in the lower lobes (findings that are independent of the severity of the disease); attenuation of the physiological gliding sign, which is related to the stage of the disease; immobility of the diaphragm, which is best visualized on a scan of the right chest when the patient is in the supine position (end-stage disease); and multiple reverberation artifacts (advanced stage).

All these abnormalities can be detected in both lungs, which is a reflection of the diffuse nature of the fibrotic process [22].

In the present study, 38% of patients (16 cases) had subpleural parenchymal lesions, 31.3% (five cases) had lymphangitis carcinomatosis, 25% (four cases) had idiopathic pulmonary fibrosis, 25% (four cases) had nonspecific interstitial pneumonia, and 18.7% (three cases) had hypersensitivity pneumonitis.

Subpleural parenchymal alterations in patients with ILD are visible in TS and comprise a broad

Figure 4

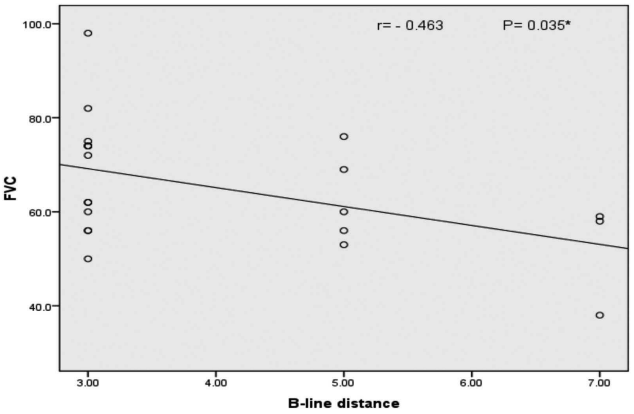

Correlation between forced vital capacity (FVC%) predicted and B-line distance in patients of interstitial lung disease (ILD).

Figure 5

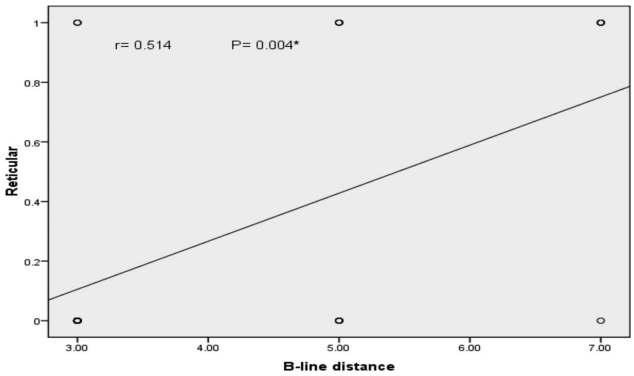

Correlation between reticular pattern on multidetector computed tomography (MDCT) and B-line distance in patients with interstitial lung disease (ILD).

Figure 6

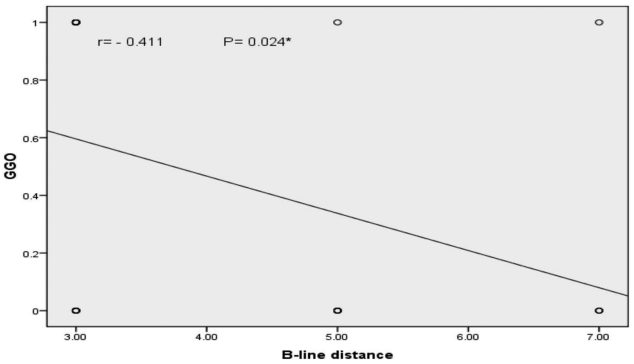

Correlation between ground-glass opacities (GGO) and B-line distance in patients with interstitial lung disease (ILD).

spectrum of pathologic changes, such as granuloma, pulmonary nodules, and pulmonary metastasis [4].

Reissig and Kroegel [4] found that one-third of ILD patients had subpleural alterations, of whom 85.7% had sarcoidosis, 66.7% had lymphangitis carcinomatosis, and 40% had silicosis. These alterations may represent granuloma in sarcoidosis and silicosis and tumor growth in lymphangitis carcinomatosis.

However, subpleural alterations and multiple comet tail artifacts are nonspecific. They may also occur in patients with chronic obstructive lung disease, bronchiolitis obliterans-organizing pneumonia, and pulmonary alveolar proteinosis, as well as after pneumonia and pulmonary embolism. It may be suggested that the number of comet tail artifacts is smaller and the affected area is more localized in these conditions [4]. In the current study, these abnormalities were detected on both sides of the lung, reflecting the diffuse fibrosing process and corresponding to the findings on MDCT as 16 cases had subpleural lesions on sonar and 19 cases had subpleural lesions on MDCT.

TS is the most sensitive technique, allowing very small amounts of pleural fluids of about 3–5 ml to be detected [24]. Pleural effusion may accompany ILD as well as a variety of other disorders, including heart failure, carcinoma, pneumonia, and pulmonary embolism, and thus is not specific. Among the 42 studied patients, 14 patients (33.3%) had pleural effusion (Table 3); five of them had lymphangitis carcinomatosis, six had areas of consolidation at the side of effusion, and three cases had nonspecific interstitial pneumonia, whereas MDCT detected 12 cases of pleural effusions.

The second aim of the current study was to detect the possible correlation of sonographic findings with the functional and radiological pattern of ILD. It was found that there was a significant negative correlation between B-line distance detected sonographically and FVC% predicted (r=−0.46, P=0.03) (Fig. 4). This was in agreement with the findings of Gargani *et al.* [18] and Hasan *et al.* [25], who found that B lines inversely correlated with FVC, total lung capacity (TLC), and diffusion capacity of the lung for carbon monoxide (DLCO), as narrow distances between B lines (B3) represent early alveolar wall affection and little pulmonary function impairment, whereas wide distances between B lines (B7) indicate thickened septa and marked impairment in lung function.

In the current study, the reticular pattern on HRCT had a highly significant positive correlation with B-line distance (r=0.51, P=0.004) (Fig. 5) and a significant negative correlation between ground-glass opacity and

Table 4 Correlation coefficient between sonographic findings, spirometry and MDCT

	FVC		FEV_1/FVC		GGO		Reticular		Honey-combing	
Variable	*r*	*P*	*r*	*P*	*r*	*P*	*r*	*P*	*r*	*P*
Pleural irregularities	−0.05	0.7	0.26	0.1	−0.22	0.1	0.11	0.4	0.21	0.1
Abolished lung sliding	0.09	0.6	0.04	0.8	−0.22	0.1	0.45	0.001*	0.19	0.2
Parenchymal alterations	0.07	0.7	-0.03	0.2	0.13	0.3	-0.31	0.07	0.04	0.2

FEV_1/FVC, forced expiratory volume in 1 s/forced vital capacity; FVC, forced vital capacity; GGO, ground-glass opacity; MDCT, multidetector computed tomography.
*Significant.

B-line distance (r=−0.41, P=0.02) (Fig. 6). This was in agreement with the findings of Hasan *et al.* [25] and Assayag *et al.* [26] who found that the distance between each two adjacent B lines positively correlated with the degree of interstitial affection on using the Warick scoring system on HRCT.

It was found that abolished lung sliding only had a highly significant positive correlation with reticular opacities on MDCT (r=0.45, P=0.001) (Table 4). This could be attributed to the fact that fibrosis affects the visceral pleura, which is followed by restriction of lung ventilation and expansion, which impairs lung sliding.

Pinal-Fernandez *et al.* [27] found that pleural irregularities were correlated with HRCT and pulmonary function test parameters in patients with systemic sclerosis and in those with antisynthetase syndrome, whereas in our study we found no correlation between pleural irregularities with pulmonary function tests and MDCT findings (Table 4).

The present study had some limitations; one of them was that diffusion capacity of the lung for carbon monoxide and total lung capacity were not measured. Second, the sonographic findings according to the thoracic area examined in the patients are not mentioned. Lastly, we did not compare chest radiographic findings with sonographic findings among patients with ILD.

Conclusion

TS is a cost-effective noninvasive modality that requires neither ionizing radiation nor a contrast medium. These advantages render it a complementary method for diagnosis of ILDs especially in situations where chest CT is not available or is contraindicated.

Bilateral B lines in combination with a thickened, irregular pleura and subpleural lesions are strongly suggestive of the presence of ILD. Increasing B-line distance can be used as a surrogate marker of pulmonary function deterioration and for the presence of fibrosis on chest CT.

Additional studies including a higher number of patients are needed to verify our results and to provide information on the feasibility of TS for early detection of ILD especially among patients with a high risk for developing ILDs.

Acknowledgements

This study was approved by the ethical committee of the Faculty of Medicine, Minia University. Informed consents were obtained from all participants.

Conflicts of interest

There are no conflicts of interest.

References

1 Havelock T, Teoh R, Laws D, Gleeson F. Pleural procedures and thoracic ultrasound: British Thoracic Society Guidelines, Pleural Diseases. *Thorax* 2010;**659**:ii72–ii74.

2 Deconinck B, Verschakelen J, Coolen J, Verbeken E, Verleden G, Wuyts W. Diagnostic workup for diffuse parenchymal lung disease: schematic flowchart, literature review, and pitfalls. *Lung* 2013;**191**(1):19–25.

3 American Thoracic Society; European Respiratory Society. American Thoracic Society/European Respiratory Society International Multidisciplinary Consensus Classification of the Idiopathic Interstitial Pneumonias. This joint statement of the American Thoracic Society (ATS), and the European Respiratory Society (ERS) was adopted by the ATS board of directors, June 2001 and by the ERS Executive Committee, June 2001. *Am J Respir Crit Care Med* 2002;**165**(2):277–304.

4 Reissig A, Kroegel C. Transthoracic sonography of diffuse parenchymal lung disease: the role of comet tail artifacts. *J Ultrasound Med* 2003;**22**(2):173–180.

5 Barskova T, Gargani L, Guiducci S, Randone SB, Bruni C, Carnesecchi G *et al.* Lung ultrasound for the screening of interstitial lung disease in very early systemic sclerosis. *Ann Rheum Dis* 2013;**72**(3):390–395.

6 Buzan MT, Pop CM. State of the art in the diagnosis and management of interstitial lung disease. *Clujul Med* 2015;**88**(2):116–123.

7 Aaron SD, Dales RE, Cardinal P. How accurate is spirometry at predicting restrictive pulmonary impairment? *Chest* 1999;**115**:869–873.

8 Raghu G, Collard HR, Egan J, Martinez FJ, Behr J, Brown KK *et al.* An official ATS/ERS/JRS/ALAT statement: idiopathic pulmonary fi brosis: evidence-based guidelines for diagnosis and management. *Am J Respir Crit Care Med* 2011;**183**:788–824.

9 Selman M. Hypersensitivity pneumonitis: a multifaceted deceiving disorder. *Clin Chest Med* 2004;**25**(3):531–547.

10 Kligerman SJ, Groshong S, Brown KK, Lynch DA. Nonspecific interstitial pneumonia: radiologic, clinical, and pathologic considerations. *Radiographics* 2009;**29**(1):73–87.

11 Bolliger CT, Herth FJ, Mayo PH, Miyazawa T, Beamis JF (Eds). *Clinical chest ultrasound: from the ICU to the bronchoscopy suite, Prog Respir Res*. Switzerland: Karger Medical and Scientific Publishers; 2009; **37**:22–33.

12 Lichtenstein D, Mezière G, Biderman P, Gepner A. The comet-tail artifact: an ultrasound sign ruling out pneumothorax. *Intensive Care Med* 1999;**25** (4):383–388.

13 Lichtenstein DA, Mezière GA. Relevance of lung ultrasound in the diagnosis of acute respiratory failure: the BLUE protocol. *Chest* 2008;**134**(1):117–125.

14 Lichtenstein DA. Suggestion for classifying air artifacts. *Whole body ultrasonography in the critically ill*. Berlin, Heidelberg, New York: Springer-Verlag; 2010: 185–188.

15 Tsai TH, Yang PC. Ultrasound in the diagnosis and management of pleural disease. *Curr Opin Pulm Med* 2003;**9**(4): 282–290.

16 Wu RG, Yuan A, Liaw YS, Chang DB, Yu CJ, Wu HD *et al.* Image comparison of real-time gray-scale ultrasound and color Doppler ultrasound for use in diagnosis of minimal pleural effusion. *Am J Respir Crit Care Med* 1994;**150**(2):510–514.

17 Targhetta R, Chavagneux R, Balmes P, Lemerre C, Mauboussin JM, Bourgeois JM, Pourcelot L. Sonographic lung surface evaluation in pulmonary sarcoidosis: preliminary results. *J Ultrasound Med* 1994;**13**(5):381–388.

18 Gargani L, Doveri M, D’Errico L, Frassi F, Bazzichi ML, Delle Sedie A *et al.* Ultrasound lung comets in systemic sclerosis: a chest sonography hallmark of pulmonary interstitial fibrosis. *Rheumatology (Oxford)* 2009;**48**(11):1382–1387.

19 Picano E, Frassi F, Agricola E, Gligorova S, Gargani L, Mottola G. Ultrasound lung comets: a clinically useful sign of extravascular lung water. *J Am Soc Echocardiography* 2006;**19**:356–363.

20 Agricola E, Bove T, Oppizzi M, Marino G, Zangrillo A, Margonato A, Picano E. Ultrasound comet-tail images': a marker of pulmonary edema: a comparative study with wedge pressure and extravascular lung water. *Chest* 2005;**127**:1690–1695.

21 Lichtenstein D, Mezière G, Biderman P, Gepner A, Barre O. The comet-tail artifact. An ultrasound sign of alveolar-interstitial syndrome. *Am J Respir Crit Care Med* 1997;**156**(5):1640–1646.

22 Doveri M, Frassi F, Consensi A, Vesprini E, Gargani L, Tafuri M *et al.* Ultrasound lung comets: new echographic sign of lunginterstitial fibrosis in systemic sclerosis. *Reumatismo* 2008;**60**:180–184.

23 Sperandeo M, Varriale A, Sperandeo G, Filabozzi P, Piattelli ML, Carnevale V *et al.* Transthoracic ultrasound in the evaluation of pulmonary fibrosis: our experience. *Ultrasound Med Biol* 2009;**35** (5):723–729.

24 Gryminski J, Krakowka P, Lypacewicz G. The diagnosis of pleural effusion by ultrasonic and radiological techniques. *Chest* 1976;**70**:33–37.

25 Hasan A, Makhlouf H, Mohamed A. Discrimination between pleural thickening and minimal pleural effusion using color Doppler chest ultrasonography. *Egypt J Chest Dis Tuberc* 2013;**62**:429–433.

26 Assayag D, Kaduri S, Hudson M, Hirsch A, Baron M. High resolution computed tomography scoring systems for evaluating interstitial lung disease in systemic sclerosis patients. *Rheumatology* 2012;**51**: ii3–ii5.

27 Pinal-Fernandez I, Pallisa-Nuñez E, SelvaOCallaghan A, Castella-Fierro E, Simeon-Aznar CP, Fonollosa-Pla V, Vilardell-Tarres M. Pleural irregularity, a new ultrasound sign for the study of interstitial lung disease in systemic sclerosis and antisynthetase syndrome. *Clin Exp Rheumatol* 2015;**33**(4): Suppl 91:S136–S141.