

# Complications and follow-up of foreign body inhalation

Nehad M. Osman, Emad Eldin Korraa, Nevine M. Abd Elfattah

**Background** Foreign body inhalation (FBI) is a dramatic incident with a number of complications.

**Objective** The aim of this study was to follow-up the patients after removal of the foreign body and to record the related complications.

**Patients and methods** This prospective follow-up study included 59 patients who presented to the Bronchology Unit of Chest Department at Ain Shams University Hospital, Cairo, Egypt, for their follow-up after successful removal of FBI. The follow-up consisted of three sections: clinical, radiological, and/or interventional.

**Results** Fifty-nine patients were included in the study, with a median age of  $3 \pm 7.30$  years. A total of 39 (66.1%) patients were followed up for 1 month, whereas 20 (33.9%) were followed up for more than 1 month. As regards the radiological follow-up, 37 (62.71%) patients showed complete radiological resolution of previous abnormalities within the duration of less than or equal to 1 month, and 10 (16.95%) patients needed more than 1 month to reach complete resolution; the difference was highly statistically significant ( $P < 0.001$ ). Only 16 patients needed rebronchoscopic evaluation; six patients refused to undergo rebronchoscopic evaluation, whereas seven needed it once, one needed it twice, and two needed it thrice. All patients who needed bronchoscope follow-up once

performed within less than 1 month recording highly statistically significant different ( $P < 0.001$ ). The most common complication was bleeding in 37 cases, followed by granulation tissue in 28 and purulent secretion in 24 cases. All patients received systemic steroids at the beginning of the procedure; meanwhile, local injection of steroids through the bronchoscope channel was performed in some selected patients. As regards the use of antibiotics, it was given either locally or systemic empirically until cultures were available.

**Conclusion** Although follow-up of patients with FBI is not an easy job, it is an essential step to complete the management and ensure no residual complications.

*Egypt J Bronchol* 2016 10:232–237

© 2016 Egyptian Journal of Bronchology

*Egyptian Journal of Bronchology* 2016 10:232–237

**Keywords:** bronchoscopy, complications, follow-up, foreign body inhalation

Department of Chest Diseases, Faculty of Medicine, Ain Shams University, Cairo, Egypt

Correspondence to Nehad M. Osman, MD, 7, Kadry St., Hamamat El Kobba, Cairo, Egypt, Tel: +20 2258 7668/20 122 354 9008; e-mail: osman\_nehad@yahoo.com

**Received** 17 March 2016 **Accepted** 8 April 2016

## Introduction

The incidence of tracheobronchial foreign body inhalation (FBI) varies with age; most of the studies emphasize its prevalence in the pediatric age group. Although it is uncommon in adults, in recent times, the geographic differences and variations in human habits has changed this concept [1–10].

Morbidity and mortality are frequently incidental with FBI, especially among children. It can lead to serious complications as well as chronic respiratory diseases if the diagnosis is delayed and/or missed. Therefore, in case of clinical and radiological suspicion, early bronchoscopic intervention in an expert center should be ensured [2–5].

Foreign body (FB)-induced lung pathologies sometimes persist after the extraction. Therefore, clinical and radiological follow-up with or without repeat bronchoscopy is essential to avoid prolonged hospitalization and minimize the medical cost [6]. Interestingly, although data on FB type are almost always reported, only a relatively small proportion of articles present details on complications revealing poor attention toward the follow-up of the patients after FB removal, and thus toward long-term outcome [7].

Therefore, the aim of this study was to follow-up patients with FBI and record the related complications during and after bronchoscopic intervention.

## Patients and methods

This prospective follow-up study included 59 patients who presented to the Bronchology Unit of Chest Department in Ain Shams University Hospital, Cairo, Egypt, during the period from June 2013 to May 2015 for their follow-up after successful removal of the FB.

After explaining the steps, duration, and procedures needed for the follow-up, written formal consent was obtained from the patients or guardian. On the basis of the previous literature, the duration of follow-up ranged from 1 week to 18 months [4–7]. All patients were followed up clinically and/or radiologically, at least for 1 month after removal of the FB. All patients were subjected to a comprehensive

---

This is an open access article distributed under the terms of the Creative Commons Attribution-NonCommercial-ShareAlike 3.0 License, which allows others to remix, tweak, and build upon the work noncommercially, as long as the author is credited and the new creations are licensed under the identical terms.

medical history and examination, with special emphasis on the following symptoms and signs, either newly developed or persistent: fever, cough, sudden or repeated paroxysms, purulent sputum, hemoptysis, wheezes, dyspnea, previous intake of antimicrobial and/or steroid, presence of cyanosis, tachypnea, decreased movement of chest wall, tracheal shift, localized area of hyper-resonance, diminished intensity of breath sounds, rhonchi, and crepitations.

Radiological evaluation was carried out with chest x-ray (CXR) primarily to compare it with the previous ones, looking for complete resolution or persistence and/or development of new findings. Chest computed tomography scan was performed in patients who had persistent and/or new findings. Rebronchoscopy, either fiberoptic and/or rigid, was performed based on the persistence of clinical and/or radiological findings within the duration of follow-up, despite undergoing medical treatment. It was carried out using a flexible video bronchoscope (Pentax; Asia Optical, Japan) of variable calibers according to the age of the patients. The procedure was performed transorally. With the patients in the supine position, a bronchoscope was introduced through the laryngeal mask in pediatric cases under general anesthesia. A rigid bronchoscope system with optical telescope connected to a video camera (Karl Storz Instruments, Tuttlingen, Germany) with the ventilating side-port, which allowed frequent intermittent oxygenation of the patient, was used. It was carried out under general anesthesia, supplemental oxygen, and pulse-oximetry monitoring according to the national [8] and international standards practice [9].

As regards the medications used in the current study, the patients received systemic steroids (hydrocortisone 100 mg/vial at a loading dose of 10–20 mg/kg for pediatric patients and 100–200 mg for adults) at the beginning of the procedure just after induction of anesthesia; meanwhile, local injection of steroids through the bronchoscope channel was performed in some selected patients using a dose of 100–200 mg hydrocortisone. As regards the use of antibiotics, they were given to patients presenting with repeated chest infection and if purulent secretions were found. It was administered locally through the bronchoscope channel (gentamicin at a dose of 5–7 mg/kg for pediatric patients and from 80 mg vial for adult patients) and/or as short course (3 days after procedure). Broad spectrum antibiotics were given until bronchoalveolar lavage culture was available. Accordingly, the antibiotics were prescribed targeting the isolated organism or stopped.

### Statistical analysis

Data were analyzed using statistical program for the social sciences (SPSS, version 18.0; SPSS Inc., Chicago, Illinois, USA). Quantitative data were expressed as mean  $\pm$  SD. Qualitative data were expressed as frequency and percentage. The following tests were carried out: the  $\chi^2$ -test of significance was used to compare proportions between two qualitative parameters.

### Results

Fifty-nine patients were included in the study with an age range of 1–40 years and a median age of  $3 \pm 7.30$  years. They were classified into two groups: group A included patients younger than 3 years and group B included patients who were 3 years or older) (Table 1).

Of the 59 patients, 39 (66.1%) were followed up for 1 month, whereas 20 (33.9%) were followed up for more than 1 month. The duration of follow-up of less than or equal to 1 month was proved to be statistically significant when compared with the duration of more than 1 month as regards sex (male/female), age groups (<3 and  $\geq 3$  years) and the type of FBI (organic/inorganic) ( $P=0.037$ ,  $0.043$ , and  $0.015$ , respectively). All of the patients reported clinical improvement, total improvement in 55 (93.22%) patients and partial improvement in four (6.78%). As regards the radiological follow-up, 37 (62.71%) patients showed complete radiological resolution of previous abnormalities (partial or total collapse and/or atelectasis and/or bilateral or unilateral consolidation/pneumonitis and/or shift of the mediastinum) within the duration of 1 month or less, and 10 (16.95%) patients needed more than 1 month to reach complete resolution; the difference was highly statistically significant ( $P<0.001$ ). Meanwhile, in six (10.17%) patients the findings persisted (unilateral hyperinflation), and only one case developed new finding (right lower lobe bronchiectasis), whereas five patients did not comply as they improved clinically. As regards the need for rebronchoscopy, the procedure was performed in

**Table 1 Patient's characteristics**

Patients characteristics	N (%) (n=59)
Sex	
Female	31 (52.54)
Male	28 (47.46)
Age (years)	
<3	35 (59.32)
$\geq 3$	24 (40.68)
Type of inhaled foreign body	
Inorganic	20 (33.90)
Organic	39 (66.10)

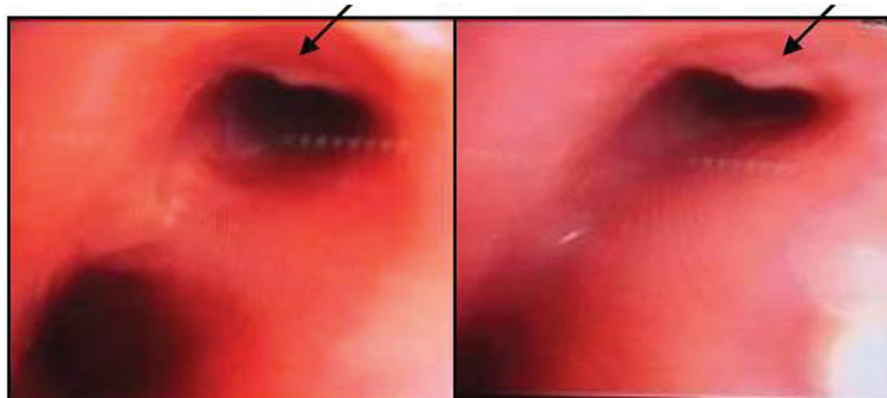
10 (16.95%) patients: seven (11.86%) cases underwent the procedure once within 1 month of their follow-up and showed marked improvement as regards granulation tissue, airway narrowing, and the lack of remnants of previous FBI, whereas three cases needed rebronchoscopy more than once. One case had longstanding (for 8 months) inhaled organic FB complicated with granulation tissue and airway stenosis, and hence rebronchoscopy was performed twice and the patient was managed conservatively. However, in two cases the procedure had to be repeated thrice as one had residual granulation tissue and airway stenosis resulting in bronchiectasis, and the other patient had tracheal stenosis after tracheostomy complicated with granuloma. However, there were six patients in whom the procedure needed to be repeated, but they had unfortunately missed follow-up. The need for rebronchoscopic evaluation as well as the bronchoscopic findings is listed in Table 2.

Comparison between the indication for rebronchoscopy and the duration of follow-up either 1 month or less or more than 1 month is shown in Table 3. All

**Table 2** Need for rebronchoscopy and the findings

	N (%)
Need for rebronchoscopy	
Not indicated	43 (72.88)
Indicated	10 (16.95)
Indicated but the patient refused	6 (10.17)
Number of bronchoscopies	
Once	7 (11.86)
Twice	1 (1.70)
Thrice	2 (3.39)
Rebronchoscopic findings	
Airway stenosis	5 (8.48)
Granulation tissue	4 (6.78)
Purulent secretions	2 (3.39)
Improved previous findings	4 (6.78)

**Figure 2**



Airway stenosis due to remaining granulation tissue after removal of the foreign body (black arrow).

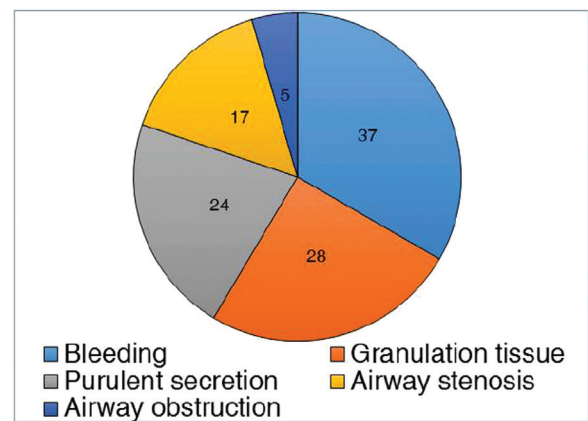
patients who needed bronchoscope follow-up once performed within 1 month recording highly statistically significant different ( $P < 0.001$ ).

Using bronchoscopy, 46 (77.9%) patients suffered from FB-induced complications mostly after 3 weeks during the follow-up period, as shown in Figs 1–3.

## Discussion

In this study, it was found that FBI is more common in children, as the median age was  $3 \pm 7.30$  years. This is in agreement with the findings of Foltran *et al.* [11] and Rajasekaran *et al.* [12] and could be explained by the lack of molar teeth, resulting in insufficient grinding, crying during feeding, and inadequately developed neuromuscular structures to protect the airways [13]. As regards the sex difference, the percentage was almost the same, with 31 (52.54%) female and 28 (47.46%) male patients. This finding is not in agreement with most of the

**Figure 1**

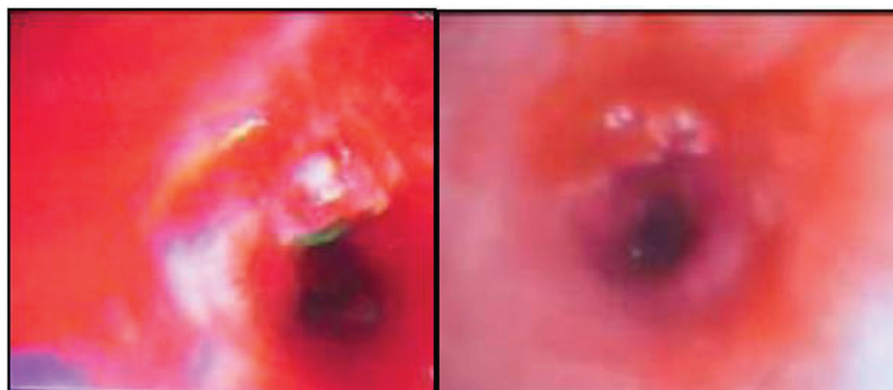


Number of patients who developed complications from foreign body inhalation.

**Table 3 Comparison between the need for rebronchoscopy and the duration of follow-up**

Bronchoscope follow-up	≤1 month [N (%)]	>1 month [N (%)]	Total	P-value	Odds ratio	95% CI	
						Lower	Upper
Not indicated	28 (65.12)	15 (34.88)	43	0.793	0.849	0.25	2.90
Indicated once	7 (100.0)	0 (0.0)	7	<0.001	9.461	0.512	174.86
Indicated more than once	0 (0.0)	3 (100.0)	3	0.073	0.063	0.003	1.29
Indicated but the patient refused	4 (66.7)	2 (33.3)	6	0.971	1.023	0.171	6.161

CI, confidence interval.

**Figure 3**

Granulation tissue in bronchus intermedius surrounded with purulent secretions after removal of the foreign body.

studies; Foltran *et al.* [11], Saki *et al.* [14], and Rajasekaran *et al.* [12] registered predominance of FBI among male patients, recording the following values, respectively: 4008 (60%) male patients from total 6757 cases in high-income countries; 9148 (53%) male patients from total 16977 in low–middle income countries; and 644 (63%) male patients from total 1015 cases. This discrepancy could be attributed to the following: first, the other studies included only children and infants younger than 3 years, in which boys could be a bit more active than girls; second, frequent scarf pin inhalation among female patients between 12 and 18 years of age who presented during the follow-up period. The patient's records revealed that organic FBI was more common compared with inorganic type, and this is in accordance with the results of Korraa *et al.* [15] and Saki *et al.* [14] in which the most common FBI was seeds.

In the current study, 59 patients were followed up. The follow-up duration ranged from one week to 18 months, wherein 39 (66%) patients were followed up for 1 month and 20 (33.9%) patients were followed up for more than 1 month. It was noted that the duration of follow-up for less than or equal to 1 month was more suitable and more convenient for the patients compared with a duration of more than 1 month as regards sex, age, and type of inhaled FB, with a statistically significant difference ( $P=0.037$ , 0.043, and 0.015, respectively). This is in agreement

with the findings of Saquib Mallick *et al.* [16], who followed up 28/128 patients for 6–48 months, especially those presenting late with subsequent complications, and Karakoc *et al.* [17], who followed up 9/32 cases for 21 months.

Fortunately, in this study, 43 patients showed clinical and radiological recovery and hence they did not need to repeat the procedure. Rebronchoscopic assessment was performed in some selected cases depending on persistent clinical and/or radiological findings, especially in cases of complicated organic FBI associated with granulation tissue. Seven patients who needed bronchoscope follow-up once performed within less than 1 month recording highly statistically significant different ( $P<0.001$ ). One (1.70%) case had longstanding (for 8 months) organic FBI complicated with granulation tissue and airway stenosis, and hence rebronchoscopy was performed twice and the patient was managed conservatively (with mucolytic, bronchodilators, inhaled steroids, and antibiotics). However, two cases needed to repeat the procedure thrice as they had residual granulation tissue and airway stenosis. One of the cases showed persistent symptoms and radiological findings, and hence lobectomy was performed. The other case needed bronchoscopic granuloma excision followed by stent replacement.

This is in accordance with the findings of Karakoc *et al.* [17], who followed up nine (28.8%) cases of their

patients for 21 months after bronchoscopic removal of FB; six (18.8%) patients were diagnosed late (at least 3 months duration) and were proved clinically and radiologically as having bronchiectasis and they were treated medically. They showed significant improvement clinically, except for one patient who had retained FB for 11 years and underwent lobectomy.

In the study by Saki *et al.* [14], the bronchoscopy was repeated once and/or twice in 11 (1.08%) patients due to prolongation in the process of removing FB or due to physical and radiological findings after bronchoscopy suggestive of the ongoing presence of FB.

The most common complications of FBI on tracheobronchial tree in this study included bleeding in 37 (62.71%) patients, granulation tissue in 28 (47.46%) patients, purulent secretion in 24 (40.68%) patients, and airway stenosis in 17 (28.81%) patients. This is in accordance with the findings of Sehgal *et al.* [18], who also recorded complications, which included bleeding in 18/45 (4%) cases, hypoxia in 2/45 (4.4%) cases, migration into another bronchial segment in 4/45 (8.8%) cases, and slipping into the gastrointestinal tract in 5/45 (11.1%). However, Fidkowski *et al.* [19] reported that the most common complications associated were infection in 58/136 (42.6%) patients, followed by severe laryngeal bronchospasm in 43/136 (31.6%) patients, failure of the removal in 37/136 (27.2%) patients, bleeding in 29/136 (21.3%) patients, and cardiac arrest in 11/136 (8%) patients.

The use of systemic and/or local steroids is in consensus with the study by Maddali *et al.* [20], Saquib Mallick *et al.* [16], Hasdiraz *et al.* [21], Saki *et al.* [14], and Sehgal *et al.* [18].

The role of steroid remains controversial as some reported reduction of laryngeal edema with steroid use, whereas others reported increased rate of complications after steroid use. However, their opinion was not conclusive as they stated that the insignificant role of steroids could be due to the use of low doses and the timing of steroid injection [17].

As regards the use of antibiotics, it is in agreement with the study by Saki *et al.* [14], who used the antibiotics prophylactically for 1–3 days in cases of vegetable FBI and/or the presence of infection and illustrated that prolonged use of antibiotics was based on the microbiological studies. In addition, Karakoc *et al.* [17] used antibiotics in 78.2% of cases who presented late with FBI. Moreover, Hasdiraz *et al.*

[21] illustrated in their study that prophylactic antibiotics were administrated before the bronchoscopy as a single dose but not after bronchoscopy.

The limitations in this study are mainly connected to the obstacles the team faced during follow-up. Some of the patients or their caregivers were not aware of the importance of the follow-up, although it was explained to them. Moreover, transportation difficulties were one of the reasons, as many patients were referred from cities away from Cairo, and hence they preferred follow-up with the nearest physician either in a clinic or at hospitals.

## Conclusion

Although follow-up of the patients with FBI is not an easy job, it is an essential step to complete the management and ensure no residual complications.

## Financial support and sponsorship

Nil.

## Conflicts of interest

There are no conflicts of interest.

## References

- Martin EW, Stephen PP, Francisco T, Timothy D, Zab M. Foreign body aspiration. *Medscape* 6 June 2012; article no. 29.
- Baharloo F, Veyckemans F, Francis C, Bietlot MP, Rodenstein DO. Tracheobronchial foreign bodies, presentation and management in children and adults. *Chest* 1999; **115**:7–62.
- Limper AH, Parakash UB. Tracheobronchial foreign bodies in adults. *Ann Intern Med* 1990; **112**:604–609.
- Lan RS, Lee CH, Chiang YC, Wang WJ. Use of fiberoptic bronchoscopy to remove tracheobronchial foreign bodies in adults. *Am Rev Respir Dis* 1994; **140**:1734–1737.
- Chen CH, Lai CL, Tsai TT, Lee YC. Perng RP Foreign body aspiration into the lower airway in Chinese adults. *Chest* 1997; **112**:129–133.
- Sirmali M, Turut H, Kisacik E, Findik G, Kaya S, Tastede I. The relationship between time of admission and complications in pediatric tracheobronchial foreign body aspiration. *Acta Chir Belg* 2005; **105**:631–634.
- Foltran F, Ballali S, Passali FM, Kern E, Morra B, Passali GC, *et al.* Foreign body in the airways: a meta-analysis of published papers. *Int J Pediatr Otorhinolaryngol* 2012; **76**:S12–S19.
- Madkour A, Al Halfawy A, Sharkawy S, Zakzouk Z. Survey of adult flexible bronchoscopy practice in Cairo. *J Bronchol* 2008; **15**:27–32.
- Du Rand IA, Blaikley J, Booton R, Chaudhuri N, Gupta V, Khalid S, *et al.* British Thoracic Society guidelines for diagnostic bronchoscopy. *Thorax* 2013; **68**:i1–i44.
- Gurpinar A, Kilic N, Dogruyol H. Foreign body aspiration in children. *Turk Respir J* 2003; **4**:131–134.
- Foltran F, Ballali S, Rodriguez H, Sebastian van As AB, Passali D, Gulati A, Gregori D. Inhaled foreign bodies in children: a global perspective on their epidemiological, clinical, and preventive aspects. *Pediatr Pulmonol* 2013; **48**:344–351.
- Srinivasan Rajasekaran, Krishnamoorthy Bala Chandran, Subramanian Anbalagan, Paramasivan Satish Kumar, Venkata Jagannathan Vikram. Management of tracheobronchial foreign bodies in children – a retrospective study of series of 50 cases. *Otolaryngology* 2013; **3**:2250–2259.

- 13 Hugo R, Giselle C, Dario G, Simonetta B, Solidea B, *et al.* Foreign bodies in the airway in children: experience in Argentina. *Prensa Med Argent*; 2015; **101**:2.
- 14 Saki N, Nikakhlagh S, Rahim F, Abshirini H. Foreign body aspirations in infancy: a 20-year experience. *Int J Med Sci* 2009; **6**:322–328.
- 15 Korraa E, Madkour A, Wagieh K, Nafae A. Bronchoscopic foreign body extraction in a pulmonary medicine department: a retrospective review of Egyptian experience. *J Bronchol Interv Pulmonol* 2010; **17**:39–44.
- 16 Saquib Mallick M, Rauf Khan A, Al-Bassam A. Late presentation of tracheobronchial foreign body aspiration in children. *J Trop Pediatr* 2005; **51**:145–148.
- 17 Karakoc F, Cakir E, Ersu R, Uyan ZS, Colak B, *et al.* Late diagnosis of foreign body aspiration in children with chronic respiratory symptoms. *Int J Pediatr Otorhinolaryngol* 2007; **71**:241–246.
- 18 Sehgal IS, Dhooira S, Ram B, Singh N, Aggarwal AN, Gupta D, *et al.* Foreign body inhalation in the adult population: experience of 25,998 bronchoscopies and systematic review of the literature. *Respir Care* 2015; **60**:1438–1448.
- 19 Fidkowski CW, Zheng H, Firth PG. The anesthetic considerations of tracheobronchial foreign bodies in children: a literature review of 12,979 cases. *Anesth Analg* 2010; **111**:1016–1025.
- 20 Maddali MM, Mathew M, Juhi C, Mohammed JA, Shyam SG. Outcome after rigid bronchoscopy in children with suspected or confirmed foreign body aspiration: a retrospective study. *J Cardiothorac Vasc Anesth* 2011; **25**:1005–1008.
- 21 Hasdiraz L, Oguzkaya F, Biglin M, Bicer C. Complications of bronchoscopy for foreign body removal: experience in 1035 cases. *Ann Saudi Med* 2006; **26**:283–287.