

# Immunohistochemical staining and computed tomography in early detection of lung cancer among heavy smokers: A pilot study

Nesrien M. Shalabi<sup>a</sup>, Mohammad K. El-Badrawy<sup>b</sup>, Ahmad S. El-Morsy<sup>b</sup>, Khalied R. Zalata<sup>c</sup>, Amina Soltan<sup>d</sup>, Abdel-Hady EL-Gilany<sup>e</sup>

**Objectives** Early diagnosis of lung cancer carries a good prognosis. The aim of the present study was early detection of lung cancer among heavy smokers using immunohistochemical staining and chest computed tomography (CT).

**Patients and methods** This descriptive cross-sectional study comprised 80 heavy smokers with smoking index more than 40 pack-years. They were recruited from the Smoking Cessation Clinic, Mansoura University Hospital. All participants were subjected to (a) chest radiography followed by high-resolution chest CT, (b) sputum sample collection, and (c) fiberoptic bronchoscopy evaluation of bronchoalveolar lavage (BAL) and bronchial mucosal biopsies from suspicious areas. All pathological samples were stained with hematoxylin and eosin followed by immunostaining using antibodies for p53 and thyroid transcription factor-1 (TTF-1). Data were analyzed using statistical package for social sciences, version 16.

**Results** The majority of heavy smokers were male, with a mean age of 53.42±11.30 years. A solitary pulmonary nodule was detected in 1.3% of cases with chest radiography and in 5% with high-resolution CT. Hematoxylin and eosin staining of sputum, BAL, and mucosal biopsies was positive for premalignant changes in 35, 27, and 17.56% of cases, respectively. Sputum, BAL, and mucosal biopsies showed expression of p53 in 30, 37.8, and 35.1% of cases, respectively. Sputum, BAL, and

mucosal biopsy showed expression of TTF-1 in 12.5, 10.8, and 14.9% of cases, respectively.

**Conclusion** The immunohistochemical technique using p53 and TTF-1 is useful in the early detection of bronchial mucosal changes in heavy smokers. There is still need for a large-scale study to highlight its validity and acceptability. Meanwhile, chest CT is beneficial for the detection of peripheral small lesions.

*Egypt J Bronchol* 2017 11:149–153

© 2017 Egyptian Journal of Bronchology

*Egyptian Journal of Bronchology* 2017 11:149–153

**Keywords:** chest computed tomography, lung cancer screening, lung cancer, monoclonal antibody p53, protein p53, sputum cytology, thyroid transcription factor-1

<sup>a</sup>Assistant Professor of Chest Medicine, Faculty of Medicine, Mansoura University, <sup>b</sup>Professor of Chest Medicine, Faculty of Medicine, Mansoura University, <sup>c</sup>Professor of Pathology Faculty of Medicine, Mansoura University, <sup>d</sup>Professor of Diagnostic Radiology Faculty of Medicine, Mansoura University, <sup>e</sup>Public Health and Preventive Medicine Department, Mansoura University

Correspondence to Nesrien M. Shalabi, MD, 14 Mokhtar El-Masry Street, Mansoura, 35111, Egypt; Tel: 0127931334; e-mail: nesrien@mans.edu.eg

**Received** 21 August 2016 **Accepted** 23 November 2016

## Introduction

Smoking is a public health problem in Egypt, with about 19.4% of adults being smokers [1]. Cigarette smoking is accountable for up to 90% of lung cancer cases [2]. Lung cancer screening helps early diagnosis and in reducing mortality [3]. There are histopathological changes that precede the development of lung cancer [4]. The use of monoclonal antibody staining for certain proteins in the malignant cells of sputum and mucosal biopsies allows early detection [5]. p53 immunostaining was positive in dysplastic and metaplastic lesions [6]. Thyroid transcription factor-1 (TTF-1) expression has been observed in small cell carcinoma and in adenocarcinoma [7]. Computed tomography (CT) has the potential for early detection of lung cancer [8].

## Aim of work

The aim of the present study was early detection of lung cancer among heavy smokers using immunohistochemical staining and chest CT.

## Patients and methods

This descriptive cross-sectional study was carried out at Chest Medicine Departments, Mansoura University Hospitals, from January 2008 to January 2014.

The study included a convenient sample of 80 apparently healthy heavy smokers recruited from the Smoking Cessation Clinic of Chest Medicine Department.

## Inclusion criteria

Heavy smokers who agreed to participate in this study were eligible for inclusion.

## Exclusion criteria

Patients with a definite diagnosis of lung cancer of any cause were excluded.

All participants were subjected to the following:

- (1) History taking and clinical evaluation.
- (2) Calculation of smoking index: Participants were classified as heavy smoker based on their cumulative smoking exposure in terms of pack-years. This was determined by dividing the number of cigarettes

This is an open access article distributed under the terms of the Creative Commons Attribution-NonCommercial-ShareAlike 3.0 License, which allows others to remix, tweak, and build upon the work noncommercially, as long as the author is credited and the new creations are licensed under the identical terms.

consumed/day by 20 and then multiplying the results by the number of years of smoking. The participants were classified as mild smokers (0.1–20.0 pack-years), moderate smokers (20.1–40.0 pack-years), and heavy smokers (>40 pack-years). Only heavy smokers were included in this study [9].

- (3) Laboratory investigations such as complete blood picture, erythrocyte sedimentation rate, liver function, renal function tests, and spirometry.
- (4) Radiological study including chest X-ray (CXR) followed by high-resolution computed tomography (HRCT) of the chest.
- (5) Sample collection:
  - (a) Sputum samples were collected on three successive days in the morning after teeth brushing in clean dry containers.
  - (b) Bronchoalveolar lavage (BAL) and bronchial mucosal biopsies were taken by means of fiberoptic bronchoscopy (FOB) for 74 out of 80 patients (six patients refused). FOB was carried out under local anesthesia with lidocaine 2% instillation and conscious sedation of 5–10 mg midazolam using Pentax FB 19 TV (Hoya Corporation, Tokyo, Japan), having a porcelain tip and inner channel diameter of 3.2 mm. BAL was done by using 100 mL of normal saline and three to five bronchial mucosal biopsies that were taken from the suspicious areas with the use of biopsy forceps through white light bronchoscopy (we did not use the autofluorescence).
- (6) Staining of all samples with hematoxylin and eosin (H&E) and immunostaining using monoclonal antibodies for p53 and TTF-1.

#### Technique of immunohistochemical staining

All specimens collected in this study were 4- $\mu$ m-thick paraffin blocks. The presence of p53 and TTF-1 was searched for using mouse monoclonal antibodies from Dako (Glostrup, Denmark). Immunostaining was performed using the Dako detection cytometation LASB2 system-HRP. Slides were deparaffinized and blocked for endogenous peroxidase with 1.75% hydrogen peroxide in methanol for 20 min. Antigen retrieval was performed using citrate solution in a 90°C water bath for 30 min. The slides were then allowed to cool for 20 min, and then blocked with normal horse serum for 5 min at 37°C. The monoclonal antibody was applied for 1 h at room temperature, followed by a biotinylated secondary antibody for 15 min at 37°C and then the streptavidine complex for 15 min at 37°C. 3,3-Diaminobenzidine for 20 min at room temperature was

used as chromogen. Slides were counterstained with Meyer's hematoxylin, dehydrated, and coverslipped. In negative control slides the same system was applied with replacement of the monoclonal antibody by diluted normal bovine serum. All negative control slides were strictly negative according to the protocol of Moldvay *et al.* [7].

The expression of TTF-1 was strictly nuclear. The degree and distribution of TTF-1 expression was classified into four categories by semiquantitative estimation of the proportion of positive staining of the tumor cells on the entire slide (absent staining, 0; faint or weak staining, i.e. <30% positive tumor cells=1; moderate staining, i.e. 30–60%=2; strong, i.e. >60% positive tumor cells=3) according to Myong [10].

The expression of p53 was nuclear. It was considered positive when seen in more than 5% of neoplastic cells. It was considered either focal or diffuse positive reaction according to Mitsudomi *et al.* [11].

Data were analyzed using statistical package for social sciences, version 16 (SPSS Inc. Released 2007, SPSS for Windows, Version 16.0, Chicago, SPSS Inc.).

Qualitative data were presented as number and percentage and quantitative variables as mean $\pm$ SD.

#### Ethical consideration

Informed verbal consent to participate in the study was obtained before the start of the work. Discovered cases were referred to Cardio Thoracic Surgery Departments. This study was supported by grants from Research Unit Account of Mansoura University as a project for early lung cancer detection And its proposal revised by 3 reviewer from 3 different universities before acceptance. The project started in 2008 before starting of the IRB/Ethics committee.

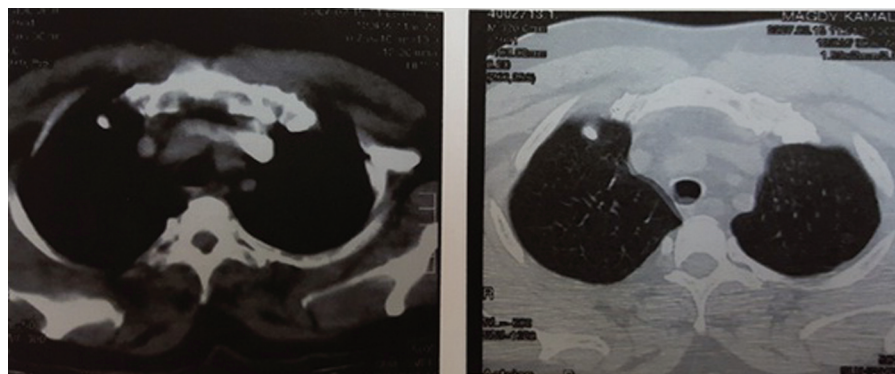
#### Results

Male sex represented 92.5% of participants, with a mean age of 53.42 $\pm$ 11.30 years. All of them were heavy smokers with a smoking index of 64.80 $\pm$ 31.53 (Table 1).

**Table 1 Characteristics of heavy smokers**

Items	Heavy smokers (n=80) [n (%)]
Sex	
Male	74 (92.5)
Female	6 (7.5)
Age (mean $\pm$ SD) (years)	53.42 $\pm$ 11.30
Smoking index (pack-year index) (mean $\pm$ SD)	64.80 $\pm$ 31.53

Figure 1



Postcontrast chest CT scan revealed right upper lobe solitary nodule in a 47-year-old male current heavy smoker with hyperinflation in CXR. FOB showed nodular mucosa. Sputum, BAL, and mucosal biopsy were positive on H&E staining. Positive expression of p53 was also seen. BAL, bronchoalveolar lavage; CT, computed tomography; CXR, chest X-ray; FOB, fiberoptic bronchoscopy; H&E, hematoxylin and eosin.

Solitary pulmonary nodules were detected by CXR in one (1.3%) case and with HRCT in four (5%) cases; they were confirmed to be malignant by transthoracic CT-guided biopsy (Table 2 and Fig. 1).

The endobronchial morphology as detected by FOB was hyperemic mucosa, irregular mucosa, and bronchial stenosis in 31.08, 32.43, and 0.4% of cases, respectively (Table 3).

Sputum cytology, from H&E staining, was positive for abnormal cells in 35% of cases. On the other hand, p53 and TTF-1 factor showed positive expression in 30 and 12.5% of cases, respectively (Table 4).

BAL cytology, from H&E staining, was positive for abnormal cells in 27% of cases. BAL showed positive expression of p53 and TTF-1 in 37.8 and 10.8% of cases, respectively (Table 4).

Staining of mucosal biopsies with H&E was positive in 17.56% of cases. Mucosal biopsies showed positive expression of p53 and TTF-1 in 35.1 and 14.9% of cases, respectively (Table 4).

## Discussion

The presentation of lung cancer is often insidious, producing minimal or no clinical symptoms until the disease is far advanced and no longer curable by surgical resection. In fact, most lung cancer patients already have locally advanced or metastatic disease at their first clinical presentation [12].

The aim of the present study was to assess the role of immunostaining for early detection of bronchial mucosal changes that may occur in heavy smokers.

**Table 2 Chest radiography and high-resolution computed tomographic findings among heavy smokers**

	Heavy smokers [n (%)]
Chest radiography	
Normal	18 (22.5)
Hyperinflation	55 (68.8)
Heterogeneous opacity	4 (5)
Solitary nodule	1 (1.3)
Bronchiectetic area	2 (2.5)
Chest computed tomographic findings	
Normal	23 (28.7)
Hyperinflation	51 (63.8)
Solitary nodule	4 (5)
Bronchiectetic area	2 (2.5)

**Table 3 Endobronchial morphology of heavy smokers**

Items	High-risk group (N=74) [n (%)]
Normal	24 (32.43)
Hyperemic mucosa	23 (31.08)
Irregular mucosa	24 (32.43)
Bronchial stenosis	3 (0.40)

The heavy smoker participants in this study were predominantly men, with a mean age of  $53.42 \pm 11.30$  years. Smokers had a higher prevalence of lung cancer than did never smokers, as active smoking is the dominant risk factor for lung cancer [13]. Chronic and intermittent exposure to cigarette smoke causes morphological alterations to the epithelium of the entire respiratory tract, from hyperplasia in lower concentrations to loss of cilia and metaplasia with keratinization in higher concentrations, and also submucosal thickening and inflammation with neutrophilic and mononuclear inflammatory cell infiltrate [14].

## Radiological study

Normal CXR in smokers does not exclude lung cancer [15]. Screening studies were planned in which

**Table 4 Sputum, bronchoalveolar lavage, and mucosal biopsy stained with hematoxylin and eosin, p53, and thyroid transcription factor-1**

Staining	Sputum (N=80) [n (%)]	BAL (N=74) [n (%)]	Mucosal biopsy (N=74) [n (%)]
Hematoxylin and eosin			
Positive	28 (35)	20 (27)	13 (17.56)
p53 immunostaining			
Positive	24 (30)	28 (37.8)	26 (35.1)
TTF-1 immunostaining			
Positive	10 (12.5)	8 (10.8)	11 (14.9)

Positive=metaplastic changes. BAL, bronchoalveolar lavage; TTF-1, thyroid transcription factor-1.

individuals were randomized to either low-dose CT or CXR. In all, 39% of participants in the LDCT group and 16% of those in the CXR group had at least one positive screening result [16]. HRCT ultimately identified nodules in 29 persons; 13 of them were diagnosed as malignant by biopsy [17]. Becker *et al.* [18] used CT for screening of 2029 high-risk individuals; 40 of them showed nodules that were confirmed by biopsy to be malignant but in the early stage. During this study solitary nodules were detected in 1.3 and 5% of cases by CXR and HRCT, respectively. CXR may be beneficial in detection of tumors but does not identify the disease in the early stage.

#### Endobronchial morphology

Estarriol *et al.* [19] studied 164 patients at high risk for bronchogenic carcinoma by FOB. They found endoscopic abnormalities as stenosis, hyperemia, and localized extrinsic compression in 113 (69%) out of 164 high-risk patients. FOB was performed by Fuso *et al.* [20]; they detected bronchial mucosa hyperemia and nodular changes in 93 of 166 smokers. Bronchial biopsies were positive for cancer in 80 patients and showed dysplasia in 13 patients. In the present study the endobronchial morphology of the heavy smokers was 32.43% normal, 31.08% hyperemic mucosa, 32.43% irregular mucosa, and 0.40% bronchial stenosis.

#### Hematoxylin and eosin staining

In this study H&E staining for sputum was positive for abnormal cells in 35% of group I. Sputum atypia is associated with a higher risk for lung cancer than is normal sputum cytology [6]. Gregory *et al.* [21] detected squamous metaplasia in 66% of 169 high-risk participants. Seok *et al.* [22] followed up 601 patients with atypical cells in the sputum for many years, about 90.2% of whom developed evident lung cancer later on. BAL and mucosal biopsy in this study were positive for abnormal cells in 27 and 17.56% of cases, respectively. This indicates occult central cancer in high-risk patients. The detection of exfoliated abnormal cells by routine cytopathology is often limited because of relatively few

atypical cells. Also, there is considerable interobserver variation in the classification of preinvasive lesions [23].

#### Immunohistochemical staining

Sputum staining by p53 in the current study showed positive expression in 30% of heavy smokers. Chandrika *et al.* [24] suggested that p53 accumulation is an early event in lung carcinogenesis and could be potentially useful in the identification of smokers at risk for developing squamous cell carcinoma. Feng *et al.* [25] detected positive p53 expression in 11 (44%) of 25 smokers. Keohavong *et al.* [26] reported that p53 immunoreactivity was positive in 6.5% of sputum samples with evidence of chronic bronchitis and in 23.9% of sputum samples of smokers without evidence of chronic bronchitis.

BAL and mucosal biopsy showed positive expression of p53 in 37.8 and 35.1% of heavy smokers, respectively.

Bentte *et al.* [27] could detect positive p53 expression in 41.3% of dysplastic lung lesions among 46 cases. Walker *et al.* [28] found that 28 (46.7%) out of 60 dysplastic bronchial biopsies were p53 positive. Kalomenidis *et al.* [29] recorded positive p53 immunoreactivity in 33.3% of preneoplastic lesions. Ponticello *et al.* [5] found that 41% (nine out of 22) of bronchial dysplastic lesions obtained by FOB were p53 positive. El-Gammal *et al.* [30] showed p53 positivity in 25% of bronchial dysplasia specimens. Nanguzgambo *et al.* [31] stated that p53 immunomarkers may be useful to establish the preinvasive process and correlated with the degree of dysplasia.

TTF-1 showed positive expression in sputum, BAL, and mucosal biopsy in 12.5, 10.8, and 14.9% of cases in group 1, respectively.

Hyperplastic alveolar type II was strongly positive for TTF-1. Therefore, it is now used to identify neoplasms of lung origin [32].

Myong [10] indicates that TTF-1 is expressed almost exclusively by adenocarcinomas and small cell carcinomas,

and thus this transcription protein is likely to be involved in the growth of adenocarcinomas and small cell carcinomas. Stenhouse *et al.* [32] confirmed that positive TTF-1 was a useful lineage marker for tumors arising from the peripheral airway of the alveolar epithelium.

The considerable positive expression of p53 and TTF-1 in this study could be attributed to the good selection of high-risk patients in this study. Good selection of cases lowers the cost effectiveness of early detection of lung cancer.

## Conclusion

Immunohistochemical technique using p53 and TTF-1 is useful for the early detection of bronchial mucosal changes in heavy smokers. There is still need for a large-scale study to highlight its validity and acceptability. Meanwhile, chest CT is beneficial for the detection of small peripheral lesions.

## Limitation

This study covered one risk factor of lung cancer in a relatively small sample in a single center.

## Financial support and sponsorship

This study was supported by grants from Research Unit Account of Mansoura University as a project for early lung cancer detection.

## Conflicts of interest

There are no conflicts of interest.

## References

- World Health Organization (WHO) Regional Office for the Eastern Mediterranean. *Report on Global Adult Tobacco Survey (GATS)*, Egypt; 2009. Available at: [http://www.who.int/tobacco/surveillance/gats\\_rep\\_egypt.pdf?ua=1](http://www.who.int/tobacco/surveillance/gats_rep_egypt.pdf?ua=1).
- Cornfield J, Haenszel W, Hammond E, Lilienfeld A, Shimkin M, *et al.* Smoking and lung cancer: recent evidence and a discussion of some questions. *Int J Epidemiol* 2009; **38**:1175–1191.
- Van Klaveren RJ. Is CT screening for lung cancer ready for prime time? *J Thorac Imaging* 2011; **26**:4–6.
- Jemal A, Siegel R, Ward E. Cancer statistics. *CA Cancer J Clin* 2006; **56**:106–130.
- Ponticello A, Barra E, Giani U. P53 immunohistochemistry can identify bronchial dysplastic lesions proceeding to lung cancer: a prospective study. *Eur Respir J* 2004; **15**:547–552.
- Fan YG, HU P, Jiang Y, Chang RS, Yao SX, Wang W, *et al.* Association between sputum atypia and lung cancer risk in an occupational cohort in Yunnan, China. *Chest* 2009; **3**:778–785.
- Moldvay J, Jackel M, Bogos K, Soltez I, Agoes L. The role of TTF-1 in differentiating primary and metastatic lung adenocarcinoma. *Pathol Oncol Res* 2004; **2**:85–88.
- Byers T, Wolf HJ, Franklin WA, Braudrick S, Merrick DT, Shroyer KR, *et al.* Sputum cytologic atypia predicts incidence lung cancer defining latency and histologic specificity. *Cancer Epidemiol Biomarkers Prev* 2008; **17**:158–162.
- National Cancer Institute. *Definition of pack year*. Available at: <http://www.cancer.gov/dictionary?Cdrid=306510>.
- Myong NH. Thyroid transcription factor-1 (TTF-1) expression in human lung carcinomas: its prognostic implication and relationship with expressions of P53 ki-67 proteins. *J Korean Med Sci* 2003; **4**:494–500.
- Mitsudomi T, Yatube Y, Takahashi T. TTF-1 expression in pulmonary adenocarcinomas. *Am J Surg Pathol* 2002; **26**:767–773.
- Corner J, Hopkinson J, Fitzsimmons D, Barclay S, Muers M. Is late diagnosis of lung cancer inevitable? Interview study of patients' recollections of symptoms before diagnosis. *Thorax* 2005; **60**:314–319.
- Agaku IT, King BA, Dube SR. Current cigarette smoking among adults – United States, 2005–2012. *Morb Mortal Wkly Rep* 2014; **2**:29–34.
- Gaworski CL, Dozier MM, Eldridge SR, Morrissey R, Rajendran N, Gerhart JM. Cigarette smoke vapor-phase effects in the rat upper respiratory tract. *Inhal Toxicol* 1998; **10**:857–873.
- Sethi S. COPD X-ray changes. *Indian J Radiol* 2004; **18**:122–128.
- National Lung Screening Trial Research Team, Church TR, Black WC, Aberle DR, Berg CD, Clingan KL, Duan F, *et al.* Results of initial low-dose computed tomographic screening for lung cancer. *N Engl J Med* 2013; **368**:1980–1991.
- Swensen SJ, Jell JR, Hartman TE, Midhun DE, Sloan JA, Sykes AM, Aughenbaugh GL, *et al.* Lung cancer screening with CT. Mayo Clinic Experience. *Radiology* 2003; **113**:25–45.
- Becker N, Motsch E, Gross ML, Eigentopf A, Heussel CP, Dienemann H, *et al.* Randomized study on early detection of lung cancer with MSCT in Germany: study design and results of the first screening round. *J Cancer Res Clin Oncol* 2012; **9**:1475–1486.
- Estarriol MH, Godoy MR, Sanchez MV, Sot MTC. Bronchoscopic lung biopsy with fluoroscopy to study 164 localized pulmonary lesions. *Arch Bronconeumol* 2004; **40**:483–488.
- Fuso L, Pagliari G, Boniello V, Trove A, Varone F. Autofluorescence bronchoscopy to identify precancerous bronchial lesions. *Monaldi Arch Chest Dis* 2005; **3**:124–128.
- Gregory L, Nachimuthu N, Tan D, Enriqueta N, Martin M, *et al.* Autofluorescence bronchoscopy of lung cancer surveillance based on risk assessment. *Chest* 2007; **4**:335–340.
- Seok D, Chul K, Hyun D, Yong IL, Young W, Koo S, *et al.* Clinical implication of atypical cells from sputum in patients without lung cancer. *Respirology* 2006; **44**:462–466.
- Nicholson AG, Perry LJ, Cury OM, Jackson P, McCormick CM, Corrin B, *et al.* Reproducibility of the WHO/IASLC grading system for pre-invasive squamous lesions of the bronchus: a study of inter-observer and intra-observer variation. *Histopathology* 2001; **38**:202–208.
- Chandrika J, Piyathilake BPS, Andro A, Heidi W, Douglas C. Nuclear accumulation of p53 is potential marker for development of squamous cell lung cancer in smokers. *Cancer* 2003; **93**:330–336.
- Feng Z, Tian D, Lan Q, Mumford J. A sensitive immunofluorescence assay for detection of p53 protein accumulation in sputum. *Anticancer Res* 1999; **9**:3847–3852.
- Keohavong PH, Lan Q, Gao W, Zheng K, Mady H, Methem M, Mamford J. Detection of p53 and R-ras mutations in sputum of individuals exposed to smoky coal emission in Xu and Wei country. *China Carcinogenesis* 2005; **2**:303–308.
- Bennett WP, Alvanja MC, Blomeke B. Environmental tobacco smoke, genetic susceptibility, and risk of lung cancer in never-smoking women. *J Natl Cancer Inst* 1999; **91**:2009–2014.
- Walker C, Robertson J, Myskow W, Pendleton N, Dixon G. p53 expression in normal and dysplastic bronchial epithelium and in lung carcinoma. *Br J Cancer* 1994; **2**:297–303.
- Kalomenidis J, Orfanidou D, Rasidakis A, Papamichails G, Toumbis M, Labaditis J, *et al.* Immunohistochemical detection of p53 protein in neoplastic, preneoplastic and normal bronchial mucosa specimens obtained during diagnostic bronchoscopy. *Oncol Rep* 1998; **3**:763–769.
- El-Gammal M, Nafee R, Ghoneim A, Abd El-Salam H, Ramadan M. p53 gene mutations in lung cancer patients. *Egypt J Chest Dis* 2003; **2**:237–250.
- Nanguzgambo AB, Razack R, Louw M, Bolliger CT. Immunohistochemistry and lung cancer: application in diagnosis, prognosis and targeted therapy. *Oncology* 2011; **80**:247–256.
- Stenhouse G, Fyfe N, King G, Chapman A, Kerr KM. Thyroid transcription factor-1 in pulmonary adenocarcinoma. *J Clin Pathol* 2004; **4**:383–387.