Role of transthoracic ultrasound in differentiation of the causes of pleural thickening

Khaled M. Kamel, Yasmine H. El-Hinnawy

Objectives Pleural thickening is defined as the increase in thickness of the pleura of more than 3 mm and can be caused by a wide range of diseases, either nonmalignant or malignant. Thoracic ultrasound has high sensitivity in assessing the pleura.

Aim The aim of this study was to assess the role of thoracic ultrasound in differentiation of the causes of pleural thickening.

Design A prospective study included 48 patients selected from the inpatient Chest Department, Kasr Al-Ainy Hospital, from January 2016 till October 2017. Patients diagnosed as having pleural thickening underwent thoracic ultrasound as well as ultrasound-guided pleural biopsy by Tru-cut needle. Descriptive data were obtained including age and sex of the patients. Thoracic ultrasound was done for the side of pleural thickening. The distribution of pleural thickness, either localized or diffuse; the surface; invasion of chest wall or diaphragm; the echogenicity and vascularity; and the presence of pleural effusion and its pattern were determined. The patients were classified into two main groups: nonmalignant (subclassified as tuberculous and nonspecific infection) and malignant cases (subclassified as mesothelioma and metastatic cases).

Results There was a statistically significant relation between the distribution either localized, diffuse, unilateral, or bilateral; the surface of the thickness; invasion of chest wall or diaphragm; the echogenicity; vascularity of the pleural thickness; and the presence of pleural effusion and its pattern on one hand and the diagnosis of pleural thickening on the other hand. There was insignificant statistical difference between pleural mesothelioma and pleural metastatic cases, and also there was insignificant statistical difference between tuberculous and nonspecific infection cases.

Conclusion The transthoracic ultrasound had a very good predilection for the diagnosis of pleural thickening etiology whether malignant or nonmalignant.

Egypt J Bronchol 2018 12:260–265

Egyptian Journal of Bronchology 2018 12:260–265

Keywords: benign, malignant, pleural thickening, ultrasound

Chest Department, Faculty of Medicine, Cairo University, Giza, Egypt

Correspondence to Yasmine H. El-Hinnawy, MD, 16 El-Tayaran Street, Nasr City, Cairo, 11759, Egypt. Tel: +20 122 233 7683; e-mail: jasminehamdy@yahoo.com

Received 2 November 2017 **Accepted** 4 December 2017

Introduction

Pleura is a serous membrane. It consists of parietal pleura and visceral pleura. Pleural thickening is defined as the increase in thickness of the pleura of more than 3 mm [1].

There is quite a wide range of diseases that can cause pleural thickening. It can be either benign or malignant [2]. Benign pleural thickening can occur in pleuro-pulmonary infection by either a specific organism as in tuberculosis [3] or a nonspecific organism causing empyema [4]. Transthoracic ultrasound is now considered a gold standard radiological technique in studying the pleural diseases such as pleural thickening [5] with or without pleural effusion of different etiologies [6]. It is the most sensitive and safe technique in detecting minimal pleural thickening or effusion [7].

The aim of this study was to assess the role of transthoracic ultrasound in differentiation of the causes of pleural thickening.

Patients and methods

A prospective study included 48 patients who were selected from the Chest Department inpatients, Kasr Al-Ainy Hospital, from January 2016 till October 2017.

Inclusion criteria

Patients diagnosed as having pleural thickening and undergoing transthoracic ultrasound as well as ultrasound-guided pleural biopsy by Tru-cut needle were included.

Exclusion criteria

The exclusion criteria were the presence of contraindication for pleural biopsy.

Descriptive data of the study population were obtained including age and sex of the patients.

Examination was performed using a real-time ultrasound scanner (Hitachi EUB-7000 with 3.5 MHz convex probe transducer and 13 MHz linear probe transducer, Hitachi, Tokyo, Japan). All patients were examined in an upright sitting position or the lateral decubitus position.

 DOI: 10.4103/ejb.ejb_109_17

We searched by transthoracic ultrasound for side of pleural thickening. The distribution of pleural thickness either localized or diffuse, the surface, invasion of either chest wall or diaphragm, the echogenicity, vascularity, and the presence of pleural effusion and its pattern were evaluated.

We classified the patients into two main groups (nonmalignant and malignant). The nonmalignant cases were subclassified as tuberculous and nonspecific infection, whereas malignant cases were subclassified as mesothelioma and metastatic cases.

Statistical methods

Coding and entering of the data was done using the statistical package statistical package for the social sciences, version 23 (SPSS; SPSS Inc., Chicago, Illinois, USA).

Data were summarized using mean and SD for quantitative variables and frequencies (number of cases).

Comparisons between groups were done using unpaired *t*-test [8].

Comparison of numerical variables between more than two groups was done using one-way analysis of variance test with post-hoc multiple two-group comparisons in normal data [9]. Statistical significant was considered when *P* value was less than 0.05.

Results

The descriptive data among the two main groups (nonmalignant and malignant) are shown in Table 1. A total of 48 patients formed the study population.

The nonmalignant cases were 22, whereas the malignant cases were 26. The mean±SD age was 44.045±18.574 in nonmalignant group, and it was 57.423±11.503 in malignant group, with statistically significant difference (*P*=0.0058). The sex distribution did not show any statistical significance. The pleural thickening mean±SD was 8.995±3.22 in nonmalignant cases, and it was 21.826±14.022 in malignant cases, with statistically significant difference (*P*=0.0001). All cases were unilateral in the malignant group, and a majority in the nonmalignant group, with statistically significant difference (*P*=0.0231).

The distribution was statistically significant (*P*=0.036). The pleural surface was smooth in all nonmalignant cases (Figs 1 and 2) and irregular in all malignant cases, with statistically significant difference (*P*=0.00001). There was no invasion to the chest wall or diaphragm in all nonmalignant cases whereas seven malignant cases showed invasion (Fig. 3), and it was statistically significant (*P*=0.00001).

All the nonmalignant cases showed echogenic pleural thickening, and 22 of the malignant cases showed hypoechogenic pleural thickening, with statistically significant difference (*P*=0.00001).

The pleural thickening in the nonmalignant cases can be avascular (3/22), scanty (16/22), and vascular (3/22) unlike malignant cases (18/26), which it was vascular

Table 1 Descriptive data of the study population in the two main groups

	Nonmalignant group (*N*=22)	Malignant group (*N*=26)	*P*-value
Age (years)			
Mean	44.045	57.423	0.0058*
SD	18.574	11.503	
Sex			
Male	15	17	0.8376
Female	7	9	
Pleural thickening (mm)			
Mean	8.995	21.826	0.0001*
SD	3.220	14.022	
Side			
Unilateral	18	26	0.0231*
Bilateral	4	0	
Distribution			
Localized	2	9	0.0360*
Diffuse	20	17	
Surface			
Smooth	22	0	0.00001*
Irregular	0	26	
Invasion			
Yes	0	19	0.00001*
No	22	7	
Echogenicity			
Echogenic	22	4	0.00001*
Hypoechogenic	0	22	
Vascularity			
Avascular	3	0	0.0021*
Scanty	16	8	
Vascular	3	18	
Pleural effusion			
No	0	10	0.0073*
Mild	10	5	
Moderate	12	7	
Massive	0	4	
Pleural effusion pattern			
No	0	10	0.0078*
Complex septated	20	12	
Complex nonseptated	2	4	

*Statistically significant.

Figure 1

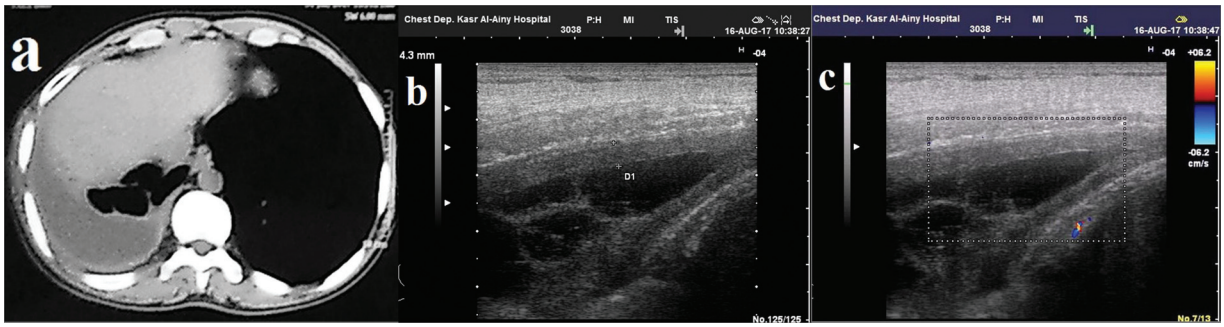

A case of chronic nonspecific pleural inflammation and thickening. (a) Computed tomography chest mediastinal window showed right pleural effusion with pleural thickening. (b) High-frequency linear probe transthoracic ultrasound B-mode image showed complex septated pleural effusion with diffuse smooth pleural thickening. (c) High-frequency linear probe transthoracic ultrasound B-mode image with Doppler study showed poor vasculature in pleural thickening.

Figure 2

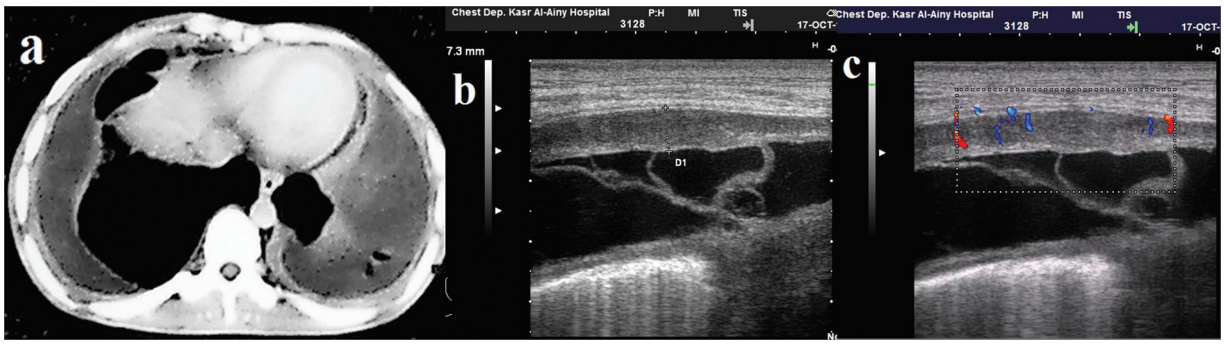

A case of tuberculous pleural inflammation and thickening. (a) Computed tomography chest mediastinal window showed bilateral pleural effusion with pleural thickening. (b) High-frequency linear probe transthoracic ultrasound B-mode image showed complex septated pleural effusion with diffuse smooth pleural thickening. (c) High-frequency linear probe transthoracic ultrasound B-mode image with Doppler study showed good vasculature in pleural thickening.

Figure 3

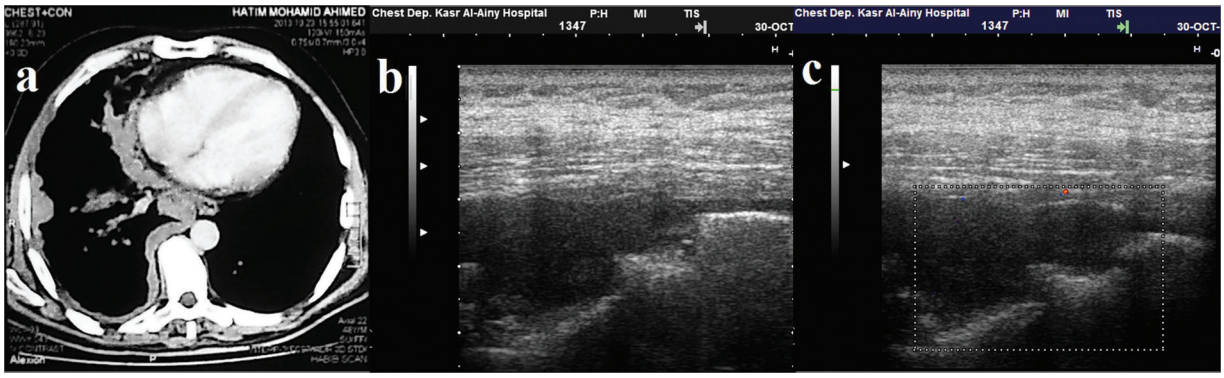

A case of right-sided mesothelioma. (a) Computed tomography chest mediastinal window showed right irregular pleural thickening. (b) High-frequency linear probe transthoracic ultrasound B-mode image showed irregular pleural thickening with sites of chest wall invasion. (c) High-frequency linear probe transthoracic ultrasound B-mode image with Doppler study showed poor vasculature in pleural thickening.

(Fig. 4) with no avascular cases, with statistically significant difference (P=0.0021).

All nonmalignant cases were associated with pleural effusion either mild or moderate amount, with statistically significant difference (P=0.0073) in comparison with malignant cases, which show absence of pleural effusion in 10 cases.

There was statistically significant difference between nonmalignant and malignant cases regarding the pattern of pleural effusion (P=0.0078).

Figure 4

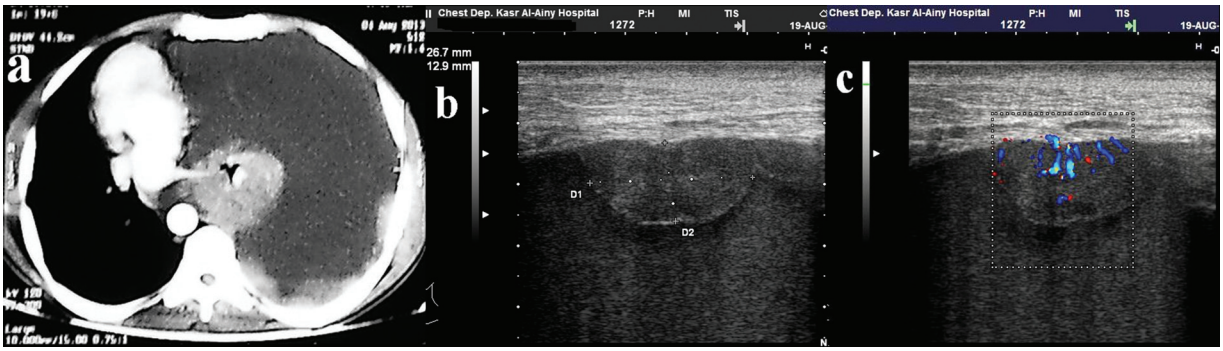

A case of left pleural effusion with pleural metastasis. (a) Computed tomography chest mediastinal window showed left massive pleural effusion with pleural deposits. (b) High-frequency linear probe transthoracic ultrasound B-mode image showed irregular pleural thickening and nodulations. (c) High-frequency linear probe transthoracic ultrasound B-mode image with Doppler study showed good vascularized pleural nodule.

The descriptive analysis within the nonmalignant cases is shown in Table 2. The nonmalignant group was subclassified into two groups: one with tuberculous infection group and another with nonspecific infection group. There was statistically significant difference regarding age and sex distribution between the two subgroups (P=0.0001 and 0.0467, respectively).

There was no statistical significance regarding the thickness of the pleura, side, distribution, surface, invasion, echogenicity, vascularity, and pleural effusion between tuberculous infection group and the nonspecific infection group.

The descriptive analysis within the malignant cases is shown in Table 3. The malignant group was subclassified into two groups: one with mesothelioma and another group with metastasis to the pleura. There was no statistical significance regarding the age, sex, thickness of the pleura, side, distribution, surface, invasion, echogenicity, vascularity, and pleural effusion between mesothelioma group and the metastatic group.

Discussion

Thoracic ultrasound is a very important radiological technique in assessing the nature of pleural opacities and effusions [10] and it also helps in distinguishing pleural thickening from minimal pleural effusion [5,11].

The mean±SD of the pleural thickness was 8.995±3.22 in nonmalignant cases and 21.826±14.022 in malignant cases, with statistically significant difference (P=0.0001). This can be explained by the more proliferation of malignant tissues. Tsai and Yang [5], considered that there was pleural thickening if it measured more than 3 mm.

The pleural thickening was unilateral in all cases of the malignant group and majority in nonmalignant group, with statistically significant difference (P=0.0231), so bilateral pleural thickening is more with nonmalignant etiology. This goes with the fact that bilateral malignant pleural affection is uncommon [12].

Regarding the distribution of pleural thickening, localized pleural thickening was more common in malignant group with statistically significant difference (P=0.036).

The pleural surface was smooth in all nonmalignant cases and irregular in all malignant cases, with statistically significant difference (P=0.00001). This is agreed by Qureshi *et al.* [13] who stated that the surface in malignant cases is irregular. Moreover, Kao *et al.* [14] considered pleural nodularity as a sign of malignancy, which agreed with our study.

There was no invasion to the chest wall or diaphragm in all nonmalignant cases whereas seven malignant cases showed invasion of either chest wall or diaphragm, and it was statistically significant (P=0.00001). This finding agreed with Wernacke [15].

All the nonmalignant cases showed echogenic pleural thickening and 22 of the malignant cases showed hypoechogenic pleural thickening, with statistically significant difference (P=0.00001). This difference may be owing to presence of more fibrous tissue in the thickened pleura of nonmalignant cases. This also agrees with Dietrich *et al.* [16], who described that postinflammatory pleural thickening is echogenic.

The pleural thickening in the nonmalignant cases can be avascular (3/22), scanty (16/22), and vascular (3/22) unlike malignant cases, where it was vascularize in 18/26, with no avascular case, with statistically significant difference

Table 2 Descriptive data of the study population in the nonmalignant group

	Tuberculous infection group (*N*=9)	Nonspecific infection group (*N*=13)	*P*-value
Age (years)			
Mean	28	55.153	0.00001*
SD	10.331	14.345	
Sex			
Male	4	11	0.0467*
Female	5	2	
Pleural thickening (mm)			
Mean	8.2	9.546	0.4087
SD	4.284	2.260	
Side			
Unilateral	6	12	0.1252
Bilateral	3	1	
Distribution			
Localized	1	1	0.7838
Diffuse	8	12	
Surface			
Smooth	9	13	0.9999
Irregular	0	0	
Invasion			
Yes	0	0	1
No	9	13	
Echogenicity			
Echogenic	9	13	0.9999
Hypoechogenic	0	0	
Vascularity			
Avascular	1	2	0.9021
Scanty	6	10	
Vascular	2	1	
Pleural effusion			
No	0	0	0.60670
Mild	3	7	
Moderate	6	6	
Massive	0	0	
Pleural effusion pattern			
No	0	0	0.63152
Complex septated	8	12	
Complex nonseptated	1	1	

*Statistically significant.

Table 3 Descriptive data of the study population in the malignant group

	Mesothelioma group (*N*=22)	Metastatic group (*N*=4)	*P*-value
Age (years)			
Mean	56.545	62.25	0.6523
SD	9.179	21.823	
Sex			
Male	14	3	0.6603
Female	8	1	
Pleural thickening (mm)			
Mean	23.113	14.75	0.32
SD	14.165	12.446	
Site			
Unilateral	22	4	0.9999
Bilateral	0	0	
Distribution			
Localized	5	4	0.0028*
Diffuse	17	0	
Surface			
Smooth	0	0	1
Irregular	22	4	
Invasion			
Yes	17	2	0.2579
No	5	2	
Echogenicity			
Echogenic	3	1	0.5622
Hypoechogenic	19	3	
Vascularity			
Avascular	0	0	0.14720
Scanty	8	0	
Vascular	14	4	
Pleural effusion			
No	10	0	0.32625
Mild	4	1	
Moderate	5	2	
Massive	3	1	
Pleural effusion pattern			
No	10	0	0.06345
Complex septated	10	2	
Complex nonseptated	2	2	

*Stastically significant.

(*P*=0.0021). The high vasculature in thickened pleura of malignant cases is mostly owing to neoangiogenesis which is a characteristic of malignancy. Koh *et al.* [17] described the vascularity of malignant pleural masses as being tortious and irregular. Not all vascularized pleural thickening is considered to be malignant. Malignant issues depend on blood vessels for their growth, so it is either of the host or by neovascularization [18].

The descriptive analysis within the nonmalignant cases showed that tuberculous pleural thickening was more common in relatively younger age patients in comparison with cases with pleural thickening owing to nonspecific infection (*P*=0.00001). Moreover, pleural thickening owing to nonspecific infection was more common in males, with statistically significant difference (*P*=0.0467). Otherwise no other feature can differentiate between pleural thickening due to tuberculosis or nonspecific infection.

The descriptive analysis within the nonmalignant cases showed that the localized pleural thickening was the usual presentation of pleural metastasis (*P*=0.0028) in comparison with mesothelioma which may present with diffuse or localized pleural affection. Otherwise we cannot differentiate between pleural thickening owing to mesothelioma and pleural

thickening because of pleural metastasis except by tissue pathology.

Conclusion

The transthoracic ultrasound has a very good predilection for the diagnosis of pleural thickening etiology whether malignant or nonmalignant.

Financial support and sponsorship

Nil.

Conflicts of interest

There are no conflicts of interest.

References

1 Sureka B, Thukral BB, Mittal MK, Mittal A, Sinha M. Radiological review of pleural tumors. *Indian J Radiol Imaging* 2013; **23**:313–320.

2 Downer NJ, Ali NJ, Au-Yong LTH. Investigating pleural thickening. *BMJ* 2013; **346**:e8376.

3 Vorster MJ, Allwood BW, Diacon AH, Koegelenberg CFN. Tuberculous pleural effusions: advances and controversies. *J Thorac Dis* 2015; **7**:981–991.

4 Karkhanis VS, Joshi JM. Pleural effusion: diagnosis, treatment, and management. *Emerg Med* 2012; **4**:31–52.

5 Tsai TH, Yang PC. Ultrasound in the diagnosis and management of pleural disease. *Curr Opin Pulm Med* 2003; **9**:282–290.

6 Soni NJ, Franco R, Velez MI, Schnobrich D, Dancel R, Restrepo MI, *et al.* Ultrasound in the diagnosis & management of pleural effusions. *J Hosp Med* 2015; **10**:811–816.

7 Mercer RM, Psallidas I, Rahman NM. Ultrasound in the management of pleural disease. *Expert Rev Respir Med* 2017; **11**:323–331.

8 Chan YH. Biostatistics 102: quantitative data–parametric & non-parametrictests. *Singapore Med J* 2003; **44**:391–396.

9 Rosner B. *Fundamentals of biostatistics*. Belmont: Duxbury Press 2006. pp. 557–558.

10 Rosenberg ER. Ultrasound in the assessment of pleural densities. *Chest* 1983; **84**:283–285.

11 Kalokairinou-Motogna M, Maratou K, Paianid I, Soldatos T, Antipa E, Tsikkini A, *et al.* Application of color Doppler ultrasound in the study of small pleural effusion. *Med Ultrason* 2010; **12**:12–16.

12 Bugalho A, Ferreira D, Dias SS, Schuhmann M, Branco JC, Marques Gomes MJ, *et al.* The diagnostic value of transthoracic ultrasonographic features in predicting malignancy in undiagnosed pleural effusions: a prospective observational study. *Respiration* 2014; **87**:270–278.

13 Qureshi NR, Rahman NM, Gleeson FV. Thoracic ultrasound in the diagnosis of malignant pleural effusion. *Thorax* 2009; **64**:139–143.

14 Kao S, Yen A, Nakanote K, Brouha S. Silver lining: imaging manifestations of pleural pathology. *Appl Radiol* 2016; **45**:9–23.

15 Wernecke K. Ultrasound study of the pleura. *Eur Radiol* 2006; **10**:1515–1523.

16 Dietrich CF, Mathis G, Cui XW, Ignee A, Hocke M, Hirche TO. Ultrasound of the pleurae and lungs. *Ultrasound Med Biol* 2015; **41**:351–365.

17 Koh DM, Burke S, Davies N, Padley SPG. Transthoracic US of the chest: clinical uses and applications. *Radiographics* 2002; **22**:e1.

18 Nagy JA, Chang SH, Dvorak AM, Dvorak HF. Why are tumour blood vessels abnormal and why is it important to know?. *Br J Cancer* 2009; **100**:865–869.