

# Spontaneous resolution of persistent lymphadenitis: a case of Kikuchi–Fujimoto disease

Divya Ramachandran, Rajesh Venkitakrishnan, Jolsana Augustine, Melcy Cleetus

Cervical lymphadenopathy is common in all age groups. Persistently enlarged cervical lymph nodes often pose a diagnostic challenge and necessitate focused clinical evaluation with targeted investigations. Pathological examination of excised node yields conclusive answer in the vast majority of cases with unsettled diagnosis. We present a case of a young man with persistent posterior cervical lymphadenopathy which on excision biopsy turned out to be Kikuchi–Fujimoto disease. With watchful follow-up, he had a self-limiting clinical course in the next few months.

*Egypt J Bronchol* 2019 13:778–780

© 2020 Egyptian Journal of Bronchology

*Egyptian Journal of Bronchology* 2019 13:778–780

**Keywords:** cervical lymphadenopathy, histiocytic necrotizing lymphadenitis, Kikuchi–Fujimoto disease, lymph node biopsy, systemic lupus erythematosus

Department of Pulmonary Medicine, Rajagiri Hospital, Kochi, Kerala, India

Correspondence to Jolsana Augustine, DNB, Rajagiri Hospital, Chunangamvely, Aluva, Kochi 683112, Kerala, India. Tel: +0484 665 5039; e-mail: jolsana.augustine@rajagirihospital.com

**Received:** 20 March 2019 **Accepted:** 27 August 2019

**Published:** 21 January 2020

## Introduction

Persistent and enlarged cervical lymph nodes more than 6 weeks can be owing to infective, malignant, and immunologic etiologies. A proper and detailed systemic examination and laboratory and histopathological evaluation may be necessary to establish a correct diagnosis in a case of persistent adenopathy. Kikuchi–Fujimoto disease (KFD), an entity of unknown etiology, is an uncommon cause of cervical lymphadenopathy in young adults, which usually has a self-limiting clinical course. The histopathological changes in the surgically resected nodes are characteristic enough to yield a conclusive diagnosis. Herein, we aim to provide a brief presentation of a patient with persistent cervical lymphadenopathy who turned out to be having KFD on histopathological analysis.

## Case summary

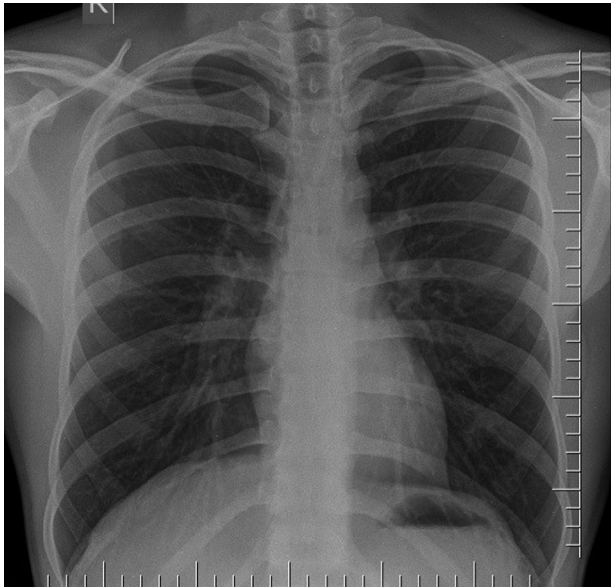
A 24-year-old male student, resident of Ernakulam urban area, with atopic background presented with a history of fever, cough, and swelling in the neck for 6 weeks. His history was remarkable for intermittent sneezing, rhinorrhea, and wheeze associated with respiratory infections. There was history of loss of weight of 4 kg in 6 months without any alteration of bowel and bladder habits. He had no addictions. He was a chemistry student and had history of exposure to chemical fumes in the laboratory. He denied any history of contact with patients with tuberculosis or sexual exposure. Physical evaluation revealed multiple firm left-sided posterior cervical lymph nodes of varying size, the largest being 2×2 cm in size. The nodes were nontender, discrete, and mobile. There was no inflammation of the overlying skin.

Respiratory system examination finding was normal. Abdomen examination revealed no clinically appreciable enlargement of liver or spleen. No lymph node enlargement at any other site was appreciated. Skin and joint examination was essentially unremarkable.

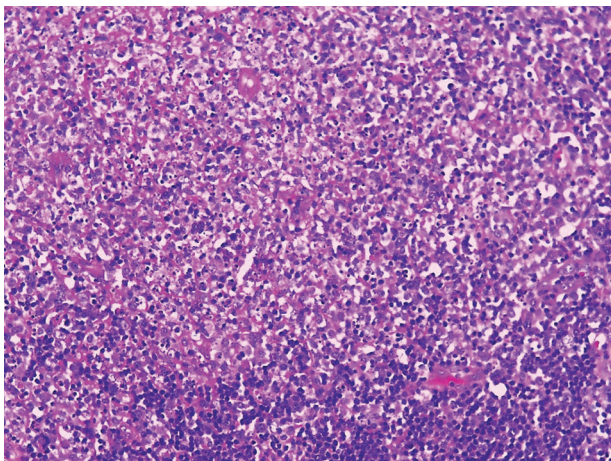
Blood examination revealed a normal hemoglobin and leukocyte count (hemoglobin 13.5 g/dl, total cholesterol 7600/mm<sup>3</sup>). Erythrocyte sedimentation rate at the end of first hour was 58 mm. An ELISA test result for HIV infection was negative. Mantoux test was nonreactive with no induration. Serum low-density lipoprotein level was within normal range. Chest radiograph (Fig. 1) and ultrasonography of the abdomen were unremarkable. With the clinical and investigation reports, the diagnosis remained elusive. The differentials entertained were chronic suppurative lymphadenitis, tuberculous lymphadenitis, lymphoma, autoimmune diseases, etc.

As the diagnosis was not settled with the available investigations, an excision biopsy of the left cervical lymph node was done and subjected to histopathological examination. Microbial tests including bacterial and fungal culture and gene Xpert for mycobacterium tuberculosis were also sent. Biopsy sample for histopathology examination revealed histiocytic infiltration of the node with confluent necrosis, karyorrhexic nuclear debris, and pyknosis

This is an open access journal, and articles are distributed under the terms of the Creative Commons Attribution-NonCommercial-ShareAlike 4.0 License, which allows others to remix, tweak, and build upon the work non-commercially, as long as appropriate credit is given and the new creations are licensed under the identical terms.

**Figure 1**

Chest radiograph showing no obvious shadow.

**Figure 2**

Histopathological image of lymph node.

characteristic of KFD (Fig. 2). Microbial tests returned negative. Virology tests to exclude EBV and cytomegalovirus involvement were not done owing to nonaffordability. HIV card test was nonreactive. Tests for autoimmune diseases were also asked for (ANA screening by immunofluorescence, anti-ds DNA), which were negative. He was initiated on symptomatic measures (antipyretics and supportive measures) and was kept on close follow-up. He became afebrile in 2 weeks with total resolution of lymph nodes in 5 months.

## Discussion

KFD is also known as 'histiocytic necrotizing lymphadenitis.' It was first described in Japan in

1972 by Kikuchi and Fujimoto independently [1]. It is relatively common among people of Asian origin. The etiology is largely unknown, although viral infections and immunological factors have been postulated. HHV-6, HHV-8, HTLV-1, EBV, and cytomegalovirus are postulated to be associated with KFD [2].

Affected patients are typically young, with a mean age of diagnosis of 21 years. Female predisposition has been noted with a female to male ratio of 4 : 1. Lymphadenopathy usually involves one or more of posterior cervical lymph node group [3]. The disease is often associated with fever, myalgias, arthralgias, and weight loss. Diarrhea, chills, and sweating are uncommon, and rarely, hepatosplenomegaly may be seen [4].

Systemic lupus is a mimicker of KFD, and both of them share similar histologic features, which warrants detailed evaluation to differentiate between them [5]. KFD is essentially a histological diagnosis characterized by paracortical necrosis, histiocytes (crescentic nuclei), and karyorrhexis. The clinical and immunological features required for diagnosis of systemic lupus erythematosus (SLE) are well documented and specific. Lupus lymphadenitis has been reported in between 12% and 59% of patients with SLE, but in contrast to KFD, is rarely the presenting feature. ANA is usually negative in KFD.

Other differential diagnosis include lymphoid malignancies like non-Hodgkin lymphomas and reactive lymphadenopathy owing to infectious etiologies, such as EBV, herpes simplex virus, and toxoplasmosis. As their management protocols differ from KFD, these entities need to be excluded before a final diagnosis of KFD is committed. Patients with KFD should be followed up regularly for years to detect possible evolution of SLE [6] and lymphoma [7].

Although the natural history can occasionally be unpredictable regarding severity and complications, most cases are self-limiting, improving within 6 months. Lymph node enlargement usually subsides in few weeks to maximum 6 months. Treatment is mainly symptomatic and supportive. NSAIDs and corticosteroids can be used to reduce inflammation depending on severity. Hydroxychloroquine has also shown some benefit in treating the disease, and antibiotics are not found to be beneficial [8]. There is a 3% risk of recurrence. Recurrences usually occur within a few weeks of the first episode [7]. Death from Kikuchi disease is extremely rare (2.1%) and usually

occurs owing to liver, pulmonary hemorrhage, DIC, fatal hemophagocytic syndrome, or heart failure [4].

### Conclusion

To conclude, KFD should be considered in the differential diagnosis of any patient presenting with unexplained lymphadenopathy with or without constitutional features. Reaching an appropriate diagnosis is especially important as it can be mistaken for complicated diagnosis like SLE, tuberculosis, or even lymphoma. Even though self-limiting illness, follow-up should be observed to detect recurrence or associated conditions such as SLE and lymphoma.

### Acknowledgements

Dr Divya helped in collecting data of the patient, Dr Rajesh identified this patient and contributed to writing, Dr Melcy in collecting images and helping with pathology aspect.

### Financial support and sponsorship

Nil.

### Conflicts of interest

There are no conflicts of interest.

### References

- 1 Kikuchi M. Lymphadenitis showing focal reticulum cell hyperplasia with nuclear debris and phagocytes: a clinicopathological study. *Acta Hematol Jpn Nippon Ketsueki Gakkai Zasshi* 1972; **35**: 379–380.
- 2 Maeda N, Yamashita Y, Kimura H, Hara S, Mori N. Quantitative analysis of herpesvirus load in the lymph nodes of patients with histiocytic necrotizing lymphadenitis using a real-time PCR assay. *Diagn Mol Pathol* 2006; **15**:49–55.
- 3 Pepe F, Disma S, Teodoro C, Pepe P, Magro G. Kikuchi-Fujimoto disease: a clinicopathologic update. *Pathologica* 2016; **108**:120–129.
- 4 Kucukardali Y, Solmazgul E, Kunter E, Oncul O, Yildirim S, Kaplan M. Kikuchi-Fujimoto Disease: analysis of 244 cases. *Clin Rheumatol* 2007; **26**:50–54.
- 5 Ruaro B, Sulli A, Alessandri E, Fraternali-Orcioni G, Cutolo M. Kikuchi-Fujimoto's disease associated with systemic lupus erythematosus: difficult case report and literature review. *Lupus* 2014; **23**: 939–944.
- 6 Sopeña B, Rivera A, Vázquez-Triñanes C, et al. Autoimmune manifestations of Kikuchi disease. *Semin Arthritis Rheum* 2012; **41**:900–906.
- 7 Kuo TT. Kikuchi's disease (histiocytic necrotizing lymphadenitis). A clinicopathologic study of 79 cases with an analysis of histologic subtypes, immunohistology, and DNA ploidy. *Am J Surg Pathol* 1995; **19**:798–809.
- 8 Rezai K, Kuchipudi S, Chundi V, Ariga R, Loew J, Sha BE. Kikuchi-Fujimoto disease: hydroxychloroquine as a treatment. *Clin Infect Dis* 2004; **39**: e124–e126.