

# Histopathological findings in patients with refractory nonfibrotic hypersensitivity pneumonitis

Yosri M.K. Akl<sup>a</sup>, Raef H. Emam<sup>a</sup>, Ahmed H. El-Habashi<sup>b</sup>, Mohamed S. Ismail<sup>a</sup>, Hossam Abdallah<sup>a</sup>

**Background** The course of hypersensitivity pneumonitis (HP) is characterized by variable patterns of disease progression. Refractory HP is defined as poor or lack of response to different modalities of treatment with worsening of the functional status.

**Aim** To assess the causes of refractory HP and to evaluate the correlation between disease progression and different histopathologic findings in patients with HP.

**Patients and methods** We included 20 patients who were diagnosed primarily as HP and proved to be refractory to treatment. All patients were subjected to the following: complete history taking and clinical examination, spirometry, 6-min walk test, high-resolution CT chest, echocardiography, and transbronchial lung biopsy.

**Results** Female sex was predominant among the studied patients. The mean age of our patients was 39.9±13.49 years. Overall, 65% of these patients were raising birds, but the offending agent was not identified in 30% of patients. Almost all patients presented with restrictive lung functions (mean forced vital capacity=59±10%), and radiologically, they mainly presented with centrilobular ground-glass and nodular opacities. Histopathological results showed that there was

isolated HP pathology in 40% of patients and HP with associated pathologies in 60% of cases without significant fibrotic changes.

**Conclusion** HP is more common in women and middle ages. Histopathological findings revealed no significant fibrotic changes in most of the cases, so other mechanisms may be involved in disease progression and may affect treatment response.

*Egypt J Bronchol* 2019 13:660–665

© 2020 Egyptian Journal of Bronchology

*Egyptian Journal of Bronchology* 2019 13:660–665

**Keywords:** fibrosis, forced vital capacity, refractory hypersensitivity pneumonitis, transbronchial lung biopsy

<sup>a</sup>Department of Pulmonary Medicine, <sup>b</sup>Department of Pathology, National Cancer Institute, Cairo University, Giza, Egypt

Correspondence to Mohamed S. Ismail, MD, Tiba Gardens, 6th October city, Giza12566, Egypt. Tel/fax: +20 111 001 4998; e-mail: mohammed.hassan@kasralainy.edu.eg

**Received:** 2 April 2019 **Accepted:** 5 May 2019

**Published:** 21 January 2020

## Introduction

Hypersensitivity pneumonitis (HP) is an increasingly recognized form of diffuse parenchymal lung disease [1]. It is an immunologically induced inflammation of the lung parenchyma that occurs in susceptible individuals in response to a variety of antigens [2]. Lung biopsy should be considered in patients with refractory HP after radiographic diagnosis using high-resolution computed tomography (HRCT) and assessment of disease progression. Clinicians must be aware that an acute exacerbation can complicate a surgical lung biopsy; therefore, if it is possible and feasible, bronchoscopic biopsy, either a classic transbronchial biopsy or, even better, a cryobiopsy, should be performed [3].

The histopathologic patterns are diverse and multifaceted and depend on the stage of the disease including non-necrotizing loosely formed granuloma, organizing pneumonia (OP), bronchiolitis, and different patterns of fibroproliferation and/or emphysema [3].

## Aim

The aim was to assess the possible causes of refractory HP and to evaluate the correlation between disease progression and different histopathologic findings in patients with HP.

## Patients and methods

This prospective study was held at Chest Department, Kasr Al Ainy Hospital, Cairo University during the period from May 2018 to February 2019. Twenty patients who were diagnosed primarily as having HP and were refractory to treatment were included in the study after obtaining an informed consent. This work was approved by the departmental ethical committee.

## Inclusion criteria

The following were the inclusion criteria:

- (1) Age from 15 to 60 years.
- (2) Both sexes.
- (3) Patients who were diagnosed primarily as nonfibrotic HP and were not responding after 6 months of treatment.

## Exclusion criteria

The following were the exclusion criteria:

- (1) Age less than 15 more than 60 years.

This is an open access journal, and articles are distributed under the terms of the Creative Commons Attribution-NonCommercial-ShareAlike 4.0 License, which allows others to remix, tweak, and build upon the work non-commercially, as long as appropriate credit is given and the new creations are licensed under the identical terms.

- (2) Patients who were diagnosed as having fibrotic HP by HRCT, which includes the following patterns: reticulation, traction bronchiectasis, and volume loss, with or without evidence of honeycombing [4].
- (3) Patients with respiratory failure type II.
- (4) Contraindications to bronchoscopy [5] as follows:
  - (a) Unstable cardiac status.
  - (b) Refractory hypoxemia.
  - (c) Bleeding diathesis or severe thrombocytopenia.
- (5) Patients with pulmonary artery systolic pressure more than 40 mmHg by echocardiography for fear of bleeding.

All patients were subjected to history taking with special concern on exposure to antigens that can cause HP, assessment of dyspnea by using modified medical research council, full clinical examination, and routine laboratory examinations, including arterial blood gases, echocardiography, and HRCT chest scan.

HRCT findings suggestive of nonfibrotic HP included centrilobular ground-glass (GGO) or nodular opacities, evidence of air-trapping in the mid to upper portion of the lung lobes, head-cheese sign (combination of GGO and mosaic parenchyma), consolidations, and cystic changes [6,7].

Pulmonary function test in the form of spirometry was performed for all of our patients by Master screen PFT 2012 (CareFusion 234 GmbH, Baesweiler, Germany). Moreover, 6-min walk test was performed using the methodology specified by the American Thoracic Society [8].

Fiberoptic bronchoscopy with transbronchial lung biopsy was done for each patient. Procedures were performed using a bronchoscope (Ymm-0025; Pentax Medical Systems, Tokyo, Japan). A thorough airway examination preceded the transbronchial lung biopsy. Adequate control of cough with topical application of lidocaine 2% (4–5 mg/kg) was done for optimal biopsy procedure and to reduce the risk of pneumothorax.

The choice of biopsy site depended on the radiological findings, preferably from the dependent parts of the lungs, right or left lower lobes. Control of bleeding, if any, was done by wedging of the bronchoscopy into the segmental bronchus in addition of instillation of cold saline or epinephrine (20 ml of 1 : 20 000) if needed [9].

Once the biopsy site was chosen, the distal end of the bronchoscope was wedged into the specific segmental bronchus, and then the forceps was introduced and gently advanced through the working channel.

Approximately five samples were obtained in each case, preserved in formalin, processed, and then examined microscopically.

Chest radiographs were performed within 6 h of the procedure in patients with chest pain or unexplained hypoxia to rule out pneumothorax [10].

### Statistical methods

The data collected were tabulated and statistically analyzed using Minitab 17.1.0.0 for Windows (Minitab Inc., State College, Pennsylvania, USA), by the following methods:

### Descriptive statistics

Continuous data were represented as mean and SD, whereas non-numerical data as number and percentage.

#### (1) Analytic statistics:

- (a) One-way analysis of variance test with multiple comparison methods (Tukey test) was used to compare between more than two groups of numerical origin.

All statistical tests were two sided. *P* considered significant if less than 0.05.

### Results

A total of 20 patients who met the inclusion criteria were recruited in our study. The mean age of the studied patients was  $39.9 \pm 13.49$  years, and most of them were females (70%) (Table 1). Regarding their occupation and exposure to HP risk factors, most of them were housewives (55%), more than half of the patients (65%) gave a history of raising birds, and 40% of them had been exposed to biomass fuel for prolonged duration, 35% of them showed mixed exposures, whereas 30% of the patients did not show any history of exposure to offending agents. Only one (5%) patient was a smoker.

Almost all patients presented with dyspnea and cough, whether dry or productive, and mild and moderate grades of dyspnea were presented in 90% of patients (45% for each).

Restrictive pattern of spirometry was present in almost all the cases, with mean forced vital capacity of  $59 \pm 10\%$ . The majority of them (65%) presented with mild restriction, the mean  $\pm$  SD distance walked in 6-min walk test was  $278 \pm 54$  m, and there was desaturation after exercise performance, with mean difference of  $11 \pm 4\%$ .

**Table 1 Patients' demography**

Variables	Total (n=20)
Age [mean (SD)]	39.9 (13.49)
Sex [n (%)]	
Female	14 (70)
Male	6 (30)
Smoking status [n (%)]	
Yes	1 (5)
No	19 (95)
Occupation [n (%)]	
Housewife	11 (55)
Student	3 (15)
Teacher	1 (5)
Traffic secretary	1 (5)
Plastic factory	1 (5)
Carpenter	1 (5)
Building worker	1 (5)
Textile factory	1 (5)

**Table 2 Radiological patterns in high-resolution computed tomography of patients**

Radiologic pattern in high-resolution computed tomography	N=20 [n (%)]
Ground-glass opacities	20 (100)
Pulmonary nodules	20 (100)
Air trapping	18 (90)
Cystic changes	8 (40)
Interlobular septal thickening	1 (5)
Consolidation	2 (10)

HRCT findings of our patients showed that all the patients had ground-glass opacities and pulmonary nodules. Consolidation and interlobular septal thickening were the less frequent patterns in HRCT (10 and 5%, respectively; Table 2).

Table 3 shows the histopathological findings. All of our patients were confirmed to have pathological findings of HP, either isolated HP pathology in 40% of cases or associated with other different pathologies like OP, nonspecific interstitial pneumonia, usual interstitial pneumonia (UIP), or alveolar hemosiderosis in 60%.

Infrequent complications were observed during the procedure, where only two patients developed controllable bleeding, which was stopped after the usage of ice-cold saline.

For statistical purposes, patients were grouped according to their HRCT findings into four patterns. The D pattern of HRCT (patients with ground glass, nodules, air trapping, and cystic changes, plus one of the following: consolidation or interseptal thickening) showed significant lower mean forced vital capacity (41%) (Fig. 1), in comparison

**Table 3 Histopathological findings of the patients**

Results	N=20 [n (%)]
Isolated HP	8 (40)
HP+OP	5 (25)
HP+NSIP	3 (15)
HP+UIP	2 (10)
HP+alveolar hemosiderosis	2 (10)

HP, hypersensitivity pneumonitis; NSIP, nonspecific interstitial pneumonia; OP, organizing pneumonia; UIP, usual interstitial pneumonia.

with other radiological patterns, with a *P* value of 0.02. This was not the case regarding forced expiratory volume in first second, where there was no significant statistical difference among all radiological patterns (*P*=0.7).

Figure 2, owing to limited number of cases, there was no test of significance to evaluate the association between patient's radiological pattern and their final histological results, but we can say that patients with HP only or HP plus UIP had B and C patterns in HRCT (either ground-glass and nodulation or ground glass, nodulation, and cystic changes). In patients with HP and OP, the D pattern took the upper hand (OP added another radiological finding in patient's HRCT as consolidation).

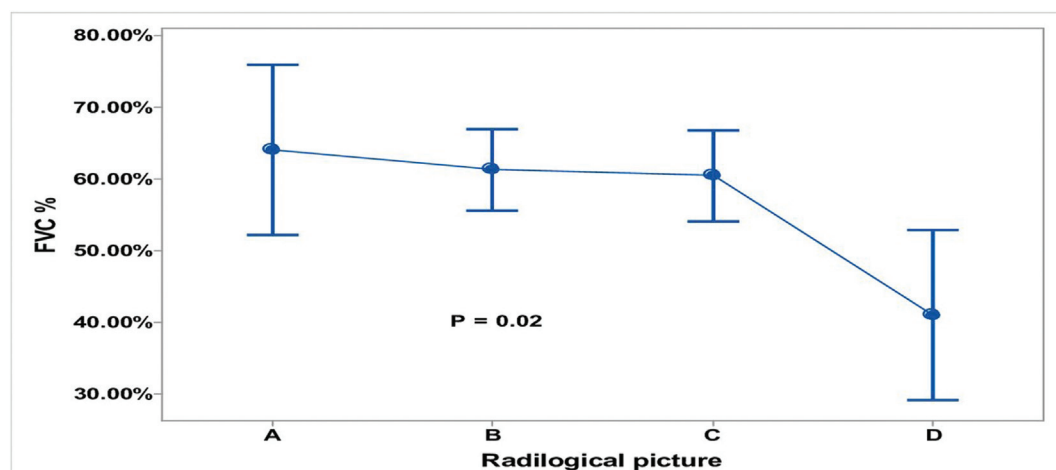
## Discussion

HP is a cascade of immune-mediated processes resulting from repeated exposure to inducing environmental agents (HP inducers). This exposure can occur anywhere. It is likely that a mixture of antigens, rather than a single antigen, contributes to the sensitization and evolution of HP [11].

The aim of this study was to assess possible causes of refractory HP and to evaluate the correlation between disease progression and different histopathologic findings in that group of patients. This work was held at Chest Department, Kasr Al Ainy Hospital, Cairo University. The study included 20 patients who were diagnosed primarily as HP and were refractory to the usual treatment regimens.

Demographic data of patients involved in this study showed that 14 (70%) patients were females and six (30%) were males, as shown in Table 1, with females : males ratio of ~1.5 : 1. We found that 55% of our study patients were housewives, and this may raise the attention to prolonged exposure of women at homes to various HP causative agents like molds and birds [12].

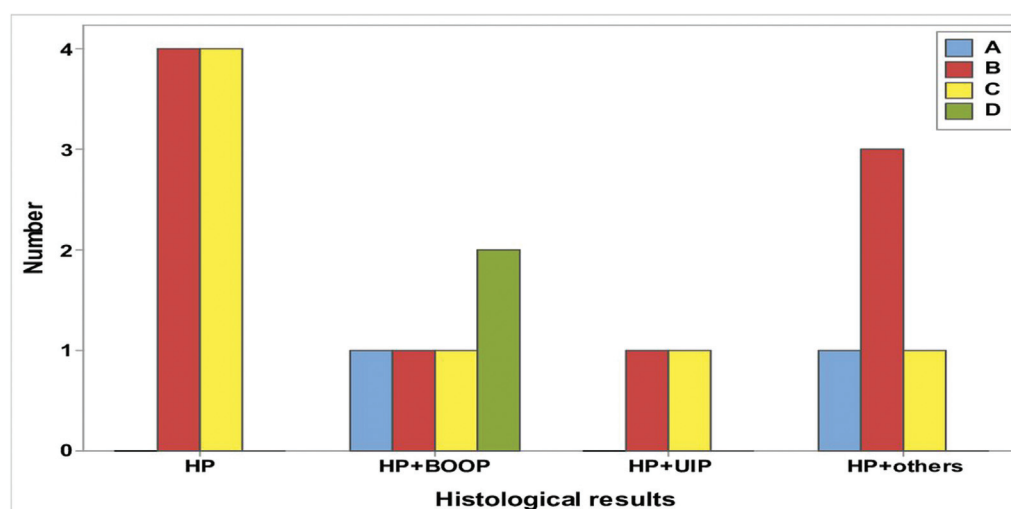
Figure 1



**A pattern:** Patients with only ground glass and nodules in HRCT, **B pattern:** Patients with A pattern plus air trapping, **C pattern:** Patients with B pattern plus cystic changes, **D pattern:** patients with C pattern plus one of the following (consolidation or interseptal thickening).

Correlation between the radiological patterns and pulmonary functions.

Figure 2



**A pattern:** Patients with only ground glass and nodules in HRCT, **B pattern:** Patients with A pattern plus air trapping, **C pattern:** Patients with B pattern plus cystic changes, **D pattern:** patients with C pattern plus one of the following (consolidation or interseptal thickening)

Correlation between the radiological patterns and histopathological results.

Our results are matched with the previous studies conducted in Egypt, in which females were found to be affected 10 times more than males, with a ratio of 10 : 1 [13,14]. Similar results showing female predominance regarding HP affection were also observed in different regions of the world [15,16]. However, other studies did not show significant sex differences between patients with HP [17,18].

Mean age of this study patients was  $39.9 \pm 13.49$  years (middle age), which is likely to reflect the characteristics of the exposed working population [19]; however, it could affect any age group [20]. This finding is consistent with the study that was conducted by Akl and colleagues, in which the mean age of affection was  $42.72 \pm 12.54$  years, but this is not correlated with others, in which the mean age at time of diagnosis was higher [17,21].



We found that 95% of our patients were nonsmokers, and this finding matches with what is well known about the relation between smoking and HP, where smokers are less commonly affected by HP, which can be explained by impaired macrophage function in smokers and less immunologic reactions [19].

When we investigated the possible causative agents of HP, we found that 70% of our patients presented with history of exposure to different hazards either occupational or domestic. Furthermore, 65% of our patients had the history of raising birds, and this matches to some extent with the results of an Egyptian study conducted recently where most of the patients were bird breeders, especially pigeon breeders (78.12%) [13].

As far as we know, depending only on the history taken from the patients, we found that 30% of our patients with HP did not show significant exposure to an obvious known causative agent, and we did not search for the presence of such offending agents by visiting their work or home places. This percentage of patients with HP without a known cause was relatively lower than that was found in the previous Egyptian studies, where more than half of their patients were with nonidentifiable causative agents (72.88 and 60.5%, respectively) [13,14]. However, our findings are consistent with the works of others [21,22].

The most predominant HRCT features of our patients were GGOs and centrilobular nodules, which were shown in all of our cases. This is consistent with other studies in which the most predominant patterns were isolated GGO or in combination with either nodules or air trapping [14,23]. As we excluded patients with fibrotic HP, so our study is not in line with the study conducted by Baqira *et al.* [22], in which cystic changes were the predominant features (91%).

Far from our expectations we got from the lack of treatment response, fibrotic changes were almost absent within the different pathological patterns in the histopathological-examined specimens of our study patients. Furthermore, HP pathology was not the sole finding in 60% of our cases, where it was associated with other different pathologies (Table 3). This was in concordance with numerous studies that revealed the presence of different pathologies associated with HP such as OP, nonspecific interstitial pneumonia, and UIP [14,16]. The lack of response to treatment in these patients with nonfibrotic HP was not explained by the

histopathological findings, as we did not find fibrotic changes in most of the cases, and this maximizes the role of HRCT scan in detection of early fibrotic changes [24].

This can be explained mainly by the persistence of exposure to antigens even at undetectable level may lead to poor response to treatment, as complete antigen avoidance is an essential step in management of HP [25].

In addition, many exposed individuals develop a mild lymphocytic alveolitis but remain asymptomatic, suggesting the development of a tolerant response to HP antigens [26], but some of them exhibit an exaggerated immune response upon exposure to the offending agents associated with nonstopable immunologic cascade owing to defective regulatory T-cell function [27].

Inherited and acquired genetic variations between patients may play a role in determining their response to treatment, so genetic biomarkers should be searched for, and this could be achieved by studying the pharmacogenetics of patients [28].

**Financial support and sponsorship**  
Nil.

#### Conflicts of interest

There are no conflicts of interest.

#### References

- 1 Lacasse Y, Girard M, Cormier Y. Recent advances in hypersensitivity pneumonitis. *Chest* 2012; **142**:208–217.
- 2 Spagnolo P, Rossi G, Cavazza A, Bonifazi M, Paladini I, Bonella F, *et al.* Hypersensitivity pneumonitis: a comprehensive review. *J Investig Allergol Clin Immunol* 2015; **25**:237–250.
- 3 Smith M, Dalurzo M, Panse P, Parish J, Leslie K. Usual interstitial pneumonia-pattern fibrosis in surgical lung biopsies. Clinical, radiological and histopathological clues to aetiology. *J Clin Pathol* 2013; **66**:896–903.
- 4 Walsh SL, Sverzellati N, Devaraj A, Wells AU, Hansell DM. Chronic hypersensitivity pneumonitis: high resolution computed tomography patterns and pulmonary function indices as prognostic determinants. *Eur Radiol* 2012; **22**:1672–1679.
- 5 Ernst A, Silvestri GA, Johnstone D. American College of Chest Physicians. Interventional pulmonary procedures: Guidelines from the American College of Chest Physicians. *Chest* 2003; **123**:1693–1717.
- 6 Rival G, Manzoni P, Lacasse Y, Polio JC, Westeel V, Dubiez A, *et al.* High-resolution CT predictors of hypersensitivity pneumonitis. *Sarcoidosis Vasc Diffuse Lung Dis* 2016; **33**:117–123.
- 7 Hanak V, Golbin JM, Hartman TE, Ryu JH. High-resolution CT findings of parenchymal fibrosis correlate with prognosis in hypersensitivity pneumonitis. *Chest* 2008; **134**:133–138.
- 8 ATS Committee on Proficiency Standards for Clinical Pulmonary Function Laboratories. ATS Statement: Guidelines for the six-minute walk test. *Am J Respir Crit Care Med* 2002; **166**:111–117.
- 9 Khoo KL, Lee P. Endobronchial epinephrine. Confusion is in the air. *Am J Respir Crit Care Med* 2013; **187**:1137–1138.

- 10 Izbicki G, Shitrit D, Yarmolovsky A, Bendayan D, Miller G, Fink G, *et al.* Is routine chest radiography after transbronchial biopsy necessary? A prospective study of 350 cases. *Chest* 2006; **129**:1561–1564.
- 11 Sterclova M, Paulik M, Skibova J, Vasakova M. Inhalation antigens sensitisation in Czech hypersensitivity pneumonitis patients [abstract]. *Am J Respir Crit Care Med* 2016; **193**:A6273.
- 12 Pereira CAC, Gimenez A, Kuranishi L, Storrer K. Chronic hypersensitivity pneumonitis. *J Asthma Allergy* 2016; **9**:171–181.
- 13 Akl Y, Soliman YMA, El-Korashy RI, El-Hennawi YH. Demographic study of hypersensitivity pneumonitis in egypt: a single center experience [abstract]. *Am J Respir Crit Care Med* 2017; **195**:A1566.
- 14 El-Kareem DA, Akl YM, Nakhla GA, Elhindawi AA, Eltorkey MA. Clinico-pathologic presentation of hypersensitivity pneumonitis in Egyptian patients: a multidisciplinary study. *Multidiscip Respir Med* 2017; **12**:10.
- 15 Fernández Pérez ER, Kong AM, Raimundo K, Kulkarni R, Cole AL. Epidemiology of hypersensitivity pneumonitis among an insured population in the United States: a claims-based cohort analysis. *Ann Am Thorac Soc* 2018; **15**:460–469.
- 16 Lima MS, Coletta ENAM, Ferreira RG, Jasinowodolinski D, Arakaki JSO, Rodrigues SCS, *et al.* Subacute and chronic hypersensitivity pneumonitis: histopathological patterns and survival. *Respir Med* 2009; **103**:508–515.
- 17 Adams TN, Newton CA, Batra K, Abu-Hijleh M, Barbera T, Torrealba J, *et al.* Utility of bronchoalveolar lavage and transbronchial biopsy in patients with hypersensitivity pneumonitis. *Lung* 2018; **196**:617–622.
- 18 De Sadeleer LJ, Hermans F, De Dycker E, Yserbyt J, Verschakelen JA, Verbeken EK, *et al.* Effects of corticosteroid treatment and antigen avoidance in a large hypersensitivity pneumonitis cohort: a single-centre cohort study. *J Clin Med* 2019; **8**:14.
- 19 Quirce S, Vandenplas O, Campo P, Cruz MJ, De Blay F, Koschel D, *et al.* Occupational hypersensitivity pneumonitis: an EAACI position paper. *Allergy* 2016; **71**:765–779.
- 20 Chapela R, Selman M, Salas J, Teran L, Fortul T, Barquin N. Effect of the pregnancy and the puerperium on the development of extrinsic allergic alveolitis. *Allergol Immunopathol (Madr)* 1985; **13**:305–309.
- 21 Chung JH, Montner SM, Adegunsoye A, Oldham JM, Husain AN, Vij R, *et al.* CT findings associated with survival in chronic hypersensitivity pneumonitis. *Eur Radiol* 2017; **27**:5127–5135.
- 22 Baqira M, Whiteb D, Ryua JH. Emphysematous changes in hypersensitivity pneumonitis: a retrospective analysis of 12 patients. *Respir Med Case Rep* 2018; **24**:25–29.
- 23 Chung JH, Zhan X, Cao M, Koelsch TL, Manjarres DCG, Brown KK, *et al.* Presence of air trapping and mosaic attenuation on chest computed tomography predicts survival in chronic hypersensitivity pneumonitis. *Ann Am Thorac Soc* 2017; **14**:1533–1538.
- 24 Ayush M, Jakhanwal I. Assessment of high resolution CT in the diagnosis of interstitial lung disease. *Int J Res Med Sci* 2018; **6**:2251–2255.
- 25 Agache IO, Rogozea L. Management of hypersensitivity pneumonitis. *Clin Transl Allergy* 2013; **3**:5.
- 26 Kim JM, Rasmussen JP, Rudensky AY. Regulatory T cells prevent catastrophic autoimmunity throughout the lifespan of mice. *Nat Immunol* 2007; **8**:191–197.
- 27 Girard M, Israël-Assayag E, Cormier Y. Impaired function of regulatory T-cells in hypersensitivity pneumonitis. *Eur Respir J* 2011; **37**:632–639.
- 28 Mroziewicz M, Tyndale RF. Pharmacogenetics: a tool for identifying genetic factors in drug dependence and response to treatment. *Addict Sci Clin Pract* 2010; **5**:17–29.