

# Mediastinal lesions, spectrum, and modalities of diagnosis: a retrospective multicenter-based experience

Mohamed S. Abdelrahman Hantera<sup>a</sup>, Hamed A.H. Abdalla<sup>b</sup>,  
Mohammed A. Ibrahim<sup>c</sup>

**Context** Diagnosis of mediastinal lesions start with clinical evaluation combined with specific laboratory investigation and different imaging modalities till biopsy that can be obtained by percutaneous approach, endoscopic approach, or finally open approach.

**Aims** A retrospective assessment of different mediastinal lesions was performed of the diagnosis and the different modalities of sampling used in three different Egyptian centers (Cairo, Mansoura, and Tanta universities) during the period 2017–2018.

**Settings and design** This was a retrospective study.

**Patients and methods** Study enrolled 92 patients with mediastinal lesions, collected from medical records of the three chest department during the period 2017–2018, were retrospectively analyzed. Data included clinical presentation, diagnostic methods, and diagnostic outcome.

**Results** Mediastinal lymphadenopathies were the most common lesions. Endobronchial ultrasound was the sampling modality most used successfully (39.13%) to achieve the final diagnosis, followed by computed tomography-guided trucut

biopsy (25%). The most frequent pathological finding was lymphomas, 34.78%, followed by adenocarcinomas, 26%.

**Conclusion** Malignancy was the commonest diagnosis among cases enrolled in our study.

*Egypt J Bronchol* 2019 13:370–376

© 2019 Egyptian Journal of Bronchology

*Egyptian Journal of Bronchology* 2019 13:370–376

**Keywords:** conventional transbronchial needle aspirate, endobronchial ultrasound-transbronchial needle aspirate, endobronchial ultrasound, mediastinal lymph nodes, percutaneous sampling, transbronchial needle aspirate

<sup>a</sup>Department of Chest Medicine, Tanta University, Tanta, <sup>b</sup>Department of Chest Medicine, Cairo university, Cairo, <sup>c</sup>Department of Chest Medicine, Mansoura University, Mansoura, Egypt

Correspondence to Mohamed S. Abdelrahman Hantera, MD Assistant Prof of Chest Medicine, Tanta University; Tanta Al Geish st, Tanta Faculty of Medicine, Tanta, 31527, Egypt. Tel: +20 114 114 6700; e-mail: dr\_mohamed\_hantera@hotmail.com

**Received** 27 April 2019 **Accepted** 6 May 2019

## Introduction

The mediastinum is an extremely complex region of the human body. Mediastinal lesions are variable, ranging from tumors, cystic lesions, vascular anomalies, lymphadenopathy, mediastinitis, mediastinal fibrosis, to pneumomediastinum [1]. Also, the diagnosis is complex and often requires tissue sampling including percutaneous mediastinal biopsies, computed tomographic (CT) and ultrasonographic (US) guidance [2], transbronchial needle aspiration (TBNA) [conventional and endobronchial ultrasound (EBUS) guided], which is an effective technique that takes bronchoscopic sampling beyond visible abnormalities [3], endoscopic ultrasound (EUS)-guided needle aspiration, which enables excellent lymph node evaluation mainly of the lower mediastinum [4], mediastinoscopy, which is considered the gold standard by which all other methods are evaluated [5], and finally open surgical biopsy if necessary [6]. The aim of the present study was to retrospectively assess different mediastinal lesions in terms of the presenting features, location, diagnostic methods used, and pathology in three different Egyptian chest centers (Cairo, Mansoura, and Tanta universities) during the period 2017–2018.

## Patients and methods

We carried out a retrospective analysis of ninety two patients with mediastinal lesions who presented at our

involved institutes during the period 2017–2018. The inclusion criteria included all patients with mediastinal lymph nodes and/or lesions; we only excluded cases that were lost to follow-up before diagnosis. Metastatic lesions were not excluded. Data included patients' demographic details, clinical presentations, biopsy methods, and the final diagnosis. All available patient data in medical records were analyzed (we would point that not all the presented cases during the studied period were enrolled due to some defective medical recording). The study protocol was approved by the ethical committee. Consent was not required as this was a retrospective study.

## Statistical analysis

The statistical analysis of data was carried out using excel and the SPSS programs statistical package for social science, version 17 (Microsoft Cooperation, Redmond, Washington, USA). The quantitative data were described as median (minimum–maximum). An analysis of the data was carried out to test statistically significant differences

This is an open access journal, and articles are distributed under the terms of the Creative Commons Attribution-NonCommercial-ShareAlike 4.0 License, which allows others to remix, tweak, and build upon the work non-commercially, as long as appropriate credit is given and the new creations are licensed under the identical terms.

between groups. Quantitative data were presented as mean $\pm$ SD and the Student *t* test was used to compare between two groups.

## Results

This retrospective study analyzed 92 patients with mediastinal lesions (share of each center is 30 patients from Cairo Center, the same share from Tanta Center and 32 patients from Mansoura). The majority of patients were men (69 men and 23 women) and the age ranged from 18 to 66 years, mean $\pm$ SD 46.03 $\pm$ 15.08. Clinical presentations were heterogeneous, varying from symptomless up to signs of superior vena caval obstruction, but dry cough was present in most cases (Table 1); also, the sites of lesions varied between anterior, middle, and posterior mediastinal regions (Tables 2–4) at which mediastinal lymphadenopathies were the prime lesions, especially at subcarinal sites. Modalities of tissue sampling included percutaneous sampling in anterior and posterior mediastinal lesions, especially CT-guided trucut core biopsy, conventional bronchoscopic TBNA, and EBUS-guided TBNA in middle mediastinal lesions and EUS-guided needle aspiration in posterior mediastinal lesions. In some cases, more than one sampling modality was used. Mediastinoscopy and surgery were a final resort with failed minimally invasive procedures. All the cases were finally diagnosed by one or more sampling modalities (the single biopsy modality was used in most cases ( $n=64$ )). EBUS was the sampling modality most used successfully (39.13%) to achieve the final diagnosis, followed by CT-guided trucut biopsy (25%), whereas each of conventional TBNA and mediastinoscopy were used successfully in 10.87% of diagnosed cases, followed by EUS (4.34%), CT-guided fine-needle aspiration cytology (FNAC) sampling (3.26%), US core sampling (3.26%), and open surgery (2.17%), and the least used modality was US FNAC (1.08%) as it is difficult and the least applicable (Fig. 1).

**Table 1 Presenting symptoms and signs of the cases studied**

	<i>n</i> (%)
Symptomless	4 (4.34)
Dry cough	74 (80.43)
Breathlessness	68 (73.91)
Dull aching chest pain	51 (55.43)
Fever	32 (34.78)
Anorexia	19 (20.65)
Dysphagia	17 (18.47)
Superior vena caval obstruction	6 (6.52)
Myasthenia symptoms	3 (3.26)
Horner syndrome	1 (1.08)

Complications were recorded in CT-guided trucut biopsy in three cases (pneumothorax); there were no other recorded complications related to any other

**Table 2 Mediastinal lesions among the cases studied and the corresponding diagnostic procedure**

Lesion	Diagnostic procedure
Anterior mediastinal mass ( <i>N</i> =25)	CT-guided FNAC ( <i>N</i> =3) CT-guided trucut ( <i>N</i> =18) US-guided FNAC ( <i>N</i> =1) US-guided trucut ( <i>N</i> =2) Mediastinoscopy ( <i>N</i> =1)
Middle mediastinal mass ( <i>N</i> =13)	EBUS ( <i>N</i> =7) Conventional TBNA ( <i>N</i> =4) Mediastinoscopy ( <i>N</i> =2)
Posterior mediastinal mass ( <i>N</i> =5)	CT-guided trucut ( <i>N</i> =3) US-guided trucut ( <i>N</i> =1) EUS ( <i>N</i> =1)
Anterior and middle mediastinal masses ( <i>N</i> =4)	CT-guided trucut ( <i>N</i> =2) EBUS ( <i>N</i> =1) Mediastinoscopy ( <i>N</i> =1)
Mediastinal lymphadenopathy ( <i>N</i> =39)	EBUS ( <i>N</i> =24) Conventional TBNA ( <i>N</i> =6) EUS ( <i>N</i> =3) Mediastinoscopy ( <i>N</i> =4) Open ( <i>N</i> =2) EBUS ( <i>N</i> =4)
Combined lymphadenopathy and masses ( <i>N</i> =6)	Mediastinoscopy ( <i>N</i> =2)

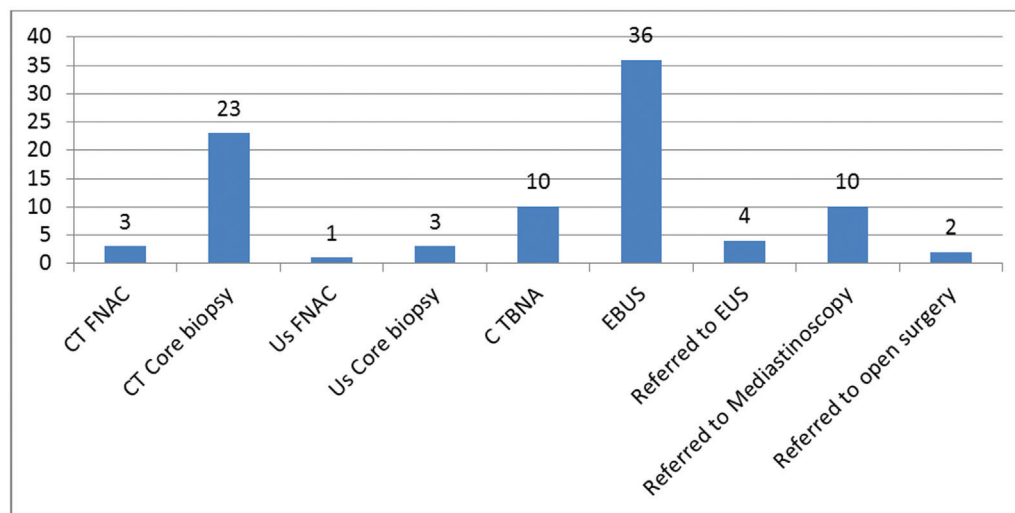
CT, computed tomography; C TBNA, conventional transbronchial needle aspirate; EBUS, endobronchial ultrasound; EUS, endoscopic ultrasound; FNAC, fine-needle aspiration cytology; US, ultrasound.

**Table 3 Distribution of enlarged mediastinal and hilar lymph nodes among the cases involved**

Lesion	<i>n</i> (%)
2R (upper right paratracheal group)	13
2L (upper left paratracheal group)	2
3 (prevascular, retrocaval group)	17
4R (lower right paratracheal group)	16
4L (lower left paratracheal group)	4
5 (subaortic group)	5
6 (paraaortic group)	5
7 (subcarinal group)	37
8 (paraesophageal group)	3
10R (right hilar group)	21
10 L (left hilar group)	14

**Table 4** Distribution of different pathological findings in different mediastinal regions

	Middle mediastinal mass	Posterior mediastinal mass	Anterior and middle mediastinal masses	Mediastinal lymphadenopathy	Combined lymphadenopathy and masses
Lymphoma	N=4	N=2	N=4	N=9	N=1
Adenocarcinoma	N=7	N=0	N=0	N=15	N=2
Sarciodosis	N=1	N=0	N=0	N=12	N=3
Small cell carcinoma	N=0	N=0	N=0	N=2	N=0
Seminoma	N=0	N=0	N=0	N=0	N=0
Thymoma	N=0	N=0	N=0	N=0	N=0
Retrosternal goiter	N=0	N=0	N=0	N=0	N=0
Neurofibroma	N=0	N=2	N=0	N=0	N=0
TB	N=1	N=0	N=0	N=0	N=0
Sarcoma	N=0	N=1	N=0	N=0	N=0
Large cell carcinoma	N=0	N=0	N=0	N=1	N=0
Thymic carcinoma	N=0	N=0	N=0	N=0	N=0
Carcinoid tumor of the thymus	N=0	N=0	N=0	N=0	N=0
Undifferentiated thymic tumor	N=0	N=0	N=0	N=0	N=0

**Figure 1**

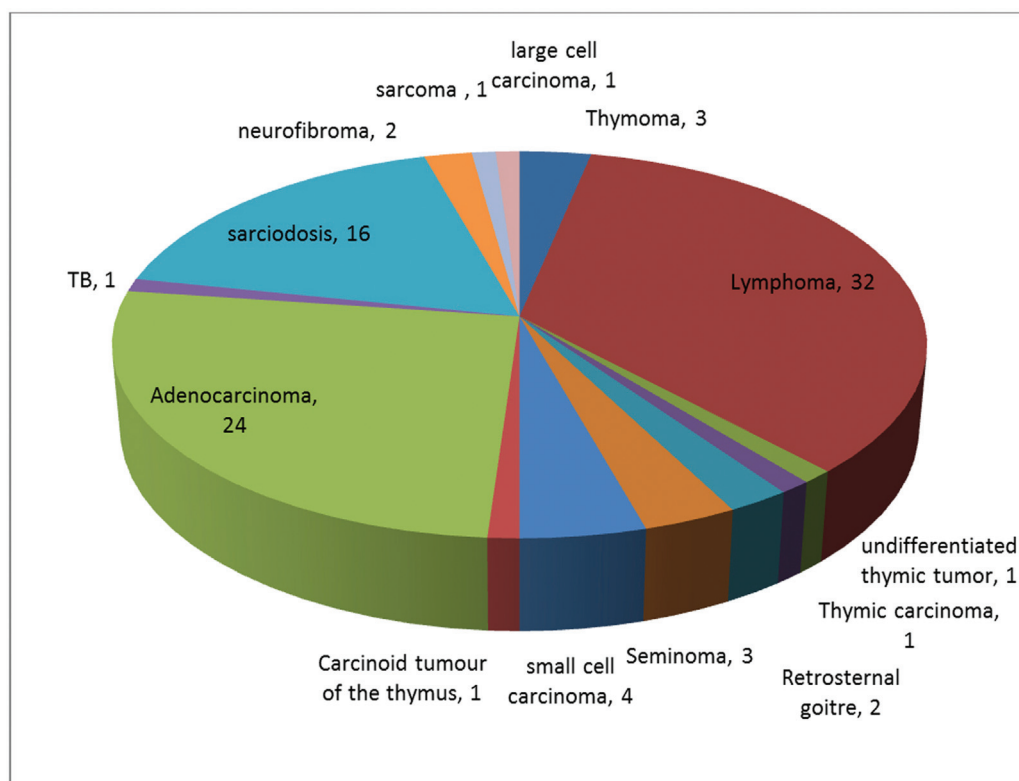
Different modalities of sampling used and number of cases diagnosed by each modality. CT, computed tomography; C TBNA, conventional transbronchial needle aspirate; EBUS, endobronchial ultrasound; EUS, endoscopic ultrasound; FNAC, fine-needle aspiration cytology; US, ultrasound.

sampling technique. Pathological data are shown in Fig. 2. The most frequent pathological finding was lymphomas, 34.78%, followed by adenocarcinomas, 26%; other findings included sarciodosis (17.39%), small cell carcinoma (4.34%), seminomas (3.26%), thymomas (3.26%), retrosternal goiter (2.17%), and neurofibroma (2.17%), and 1.08% each of tuberculosis, sarcoma, large cell carcinoma, thymic carcinoma, carcinoid tumor of the thymus, and undifferentiated thymic tumor. Malignant conditions were found in all age groups, with no significant differences between the different age groups in terms of the frequency of neoplasms. Cases are shown in Figs 3–5.

## Discussion

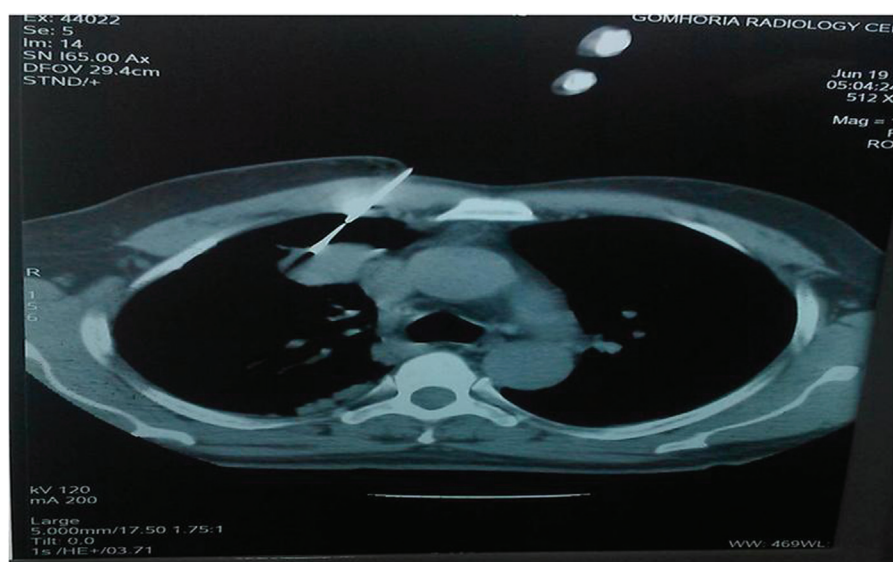
Establishing the diagnosis of mediastinal pathologies is a stepwise process that starts with clinical symptoms (usually cough, chest pain, fever/chills and dyspnea, paralysis of the limbs, hoarsness of voice, Horner syndrome, and superior vena caval obstruction syndrome) [7] to selected laboratory investigation such as anti-acetylcholine receptor antibodies, alpha-fetoprotein, beta-human chorionic gonadotropin, and lactate dehydrogenase [8,9]. Plus chest imaging techniques like chest radiography, CT films and MRI reaching novel modalities like

Figure 2



Spectrum of pathological diagnosis.

Figure 3



Fifty-four-year-old man diagnosed by CT-guided trucut biopsy (small cell carcinoma). CT, computed tomography.

[<sup>18</sup>F] 2-Fluoro-2-deoxy-D-glucose positron emission tomography/CT which proved efficacy in diagnosis of mediastinal masses [10]. But definite diagnosis usually need tissue sampling.

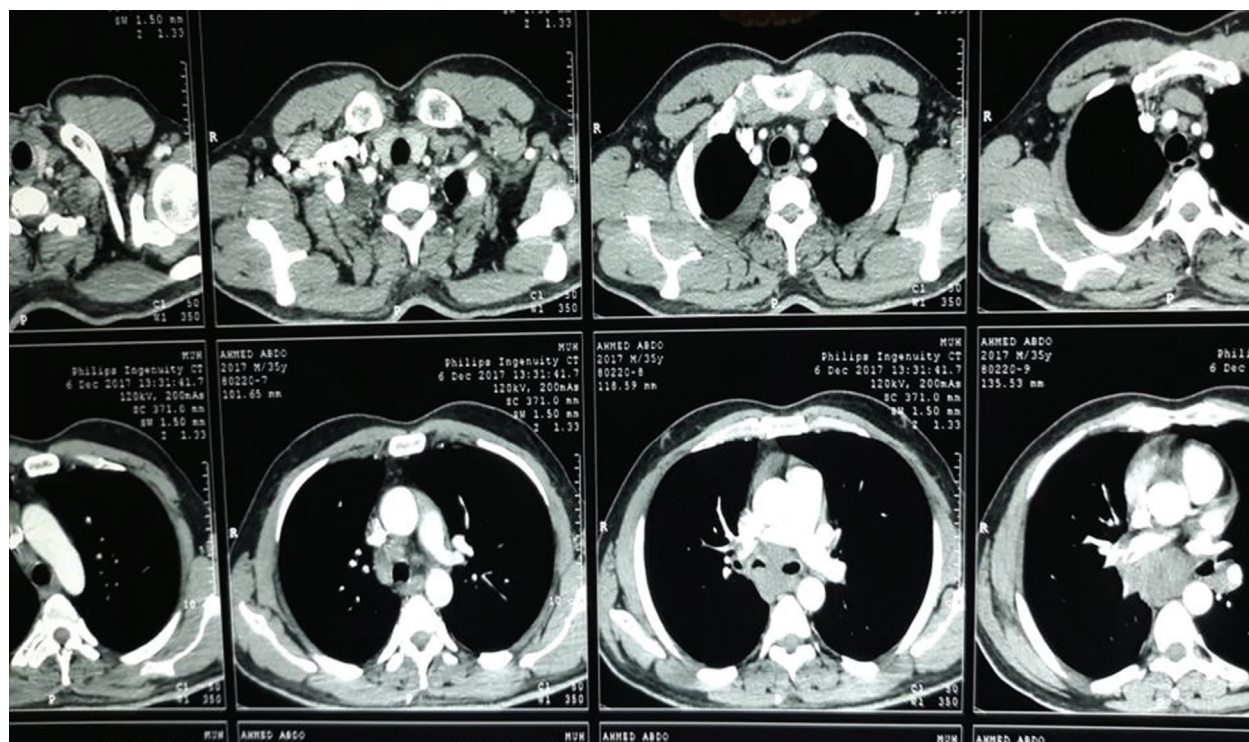
In our current retrospective analysis, we focused on sampling techniques and the final pathological data.

Three Egyptian centers were involved because of the relative rarity of mediastinal tumors.

We enrolled 92 patients; other similar studies such as Devi *et al.* [11], Karki and Chalise [12], Aroor *et al.* [13], and Dixit *et al.* [14] enrolled 20, 27, 35, and 144 patients, respectively, and the last one was

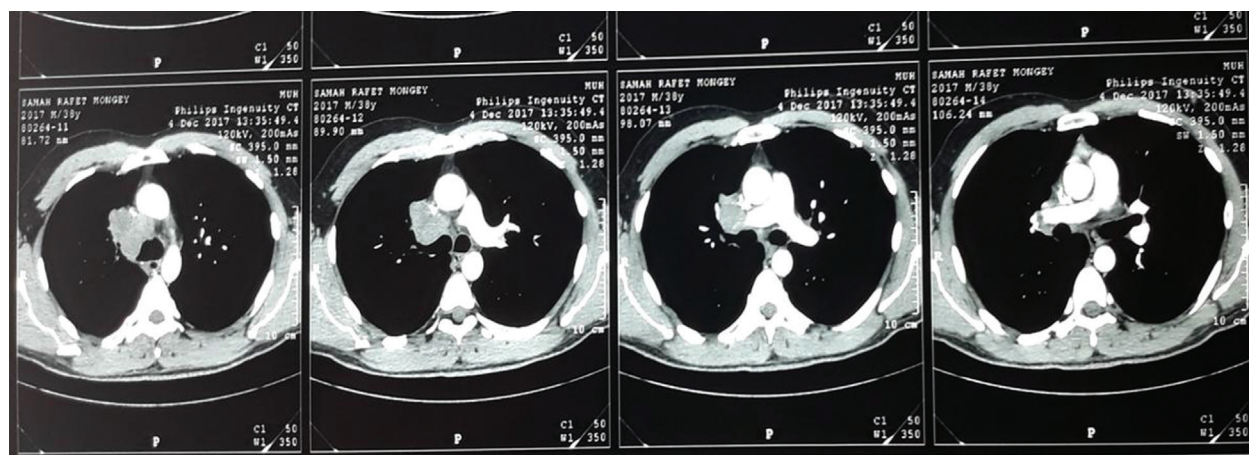


Figure 4



Adenocarcinoma in a 50-year-old man diagnosed by EBUS sampling of subcarinal mass. EBUS, endobronchial ultrasound.

Figure 5



Right paratracheal mass approached by mediastinoscopy and diagnosed as Hodgkin lymphoma.

carried out over 8 years. The majority of our patients were men, and this was in agreement with Devi *et al.* [11], Karki and Chalise [12], Aroor *et al.* [13], and Dixit *et al.* [14]. Thirteen were male and seven were female, 13 were males and 7 were females, two-third of cases (24; 68.57%) were males and 11 cases (31.43%) were females and 116 patients were males and 23 patients were females, respectively.

The age group in the current study ranged from 18 to 66 years, which was a narrower range than most of the

other studies such as Devi *et al.* [11], Karki and Chalise [12], Aroor *et al.* [13], and Dixit *et al.* [14]: 10–73 years, 4 months to 70 years, mean age of 35.5 years, 17–68 years, mean age 45.4 years, and 14 and 76 years, mean age 45.5 years, respectively.

Dry cough was the most common complaint, followed by dyspnea and chest pain; this was in agreement with Aroor *et al.* [13], who reported that cough and weight loss were the most common symptoms, found in 20 (57.14%) cases, followed by dyspnea (16; 45.71%). Also, Dixit *et al.* [14] reported cough as the primary

symptom [cough as the prominent symptom found in 91.3% of cases, followed by shortness of breath (83.4%), chest pain (60.4%), fever (31.6%), dysphasia (13.6%), and dysphonia (10.7%)], whereas chest pain was the most common symptom in Devi *et al.* [11], followed by dyspnea, cough, and dysphagia. Heterogenicity in age group, sex, and symptomatology may be explained by the wide range of lesions affecting the mediastinum.

In Karki and Chalise [12], most of the cases were localized in the anterior mediastinum. In Dixit *et al.* [14], in 95 (68.3%) cases, the anterior mediastinum was affected, in 23 (16.5%) cases, the middle mediastinum was affected, and in 11 (2.5%) cases, the posterior mediastinum was affected. In 10 (7.1%) cases, two or more than two compartments of the mediastinum were simultaneously affected, whereas in our current analysis, mediastinal lymphadenopathies were the primary lesions, especially at subcarinal sites, followed by anterior mediastinal masses in 25 cases and middle mediastinal masses in 13 cases.

Sampling modalities in our study were variable including percutaneous sampling in anterior and posterior mediastinal lesions, especially CT-guided trucut core biopsy, conventional bronchoscopic TBNA, and EBUS-guided TBNA in middle mediastinal lesions and EUS-guided needle aspiration in posterior mediastinal lesions. In some cases, more than one sampling modality was used. Mediastinoscopy and surgery were a final resort with failed minimally invasive procedures. All the cases were finally diagnosed by one or more sampling modality [a single biopsy modality were used in most cases ( $n=64$ )]. EBUS was the sampling modality most used successfully to achieve the final diagnosis, followed by CT-guided trucut biopsy. Other studies showed fewer used sampling techniques as in Devi *et al.* [11], FNAC was used in three cases and CT-guided biopsy in five cases. Thoracotomy and median sternotomy were performed in six cases each without attempting FNAC/CT-guided biopsy; in Karki and Chalise [12], only FNAC and surgery were used. We reported three cases of pneumothorax and no biopsy-related deaths. In Dixit *et al.* [14], there was no procedure-related mortality. Among the complications, local self-limiting chest pain was experienced by 34 (24.5%) patients, small pneumothorax developed in 18 (13.6%) patients that required no intervention and managed conservatively, large pneumothorax was encountered in two (1.4%) cases, which was managed by intercostal chest tube drainage with underwater seal system, and scanty hemothorax was noted in 13 (9.3%) cases.

In terms of the final diagnosis, the most frequent pathological finding was lymphomas, followed by adenocarcinomas. In Devi *et al.* [11], thymic tumors were the most common, with eight cases of thymoma and one case of high-grade undifferentiated carcinoma. In Karki and Chalise [12], there were eight cases of thymoma, one case of thymic carcinoma, and one case of involutational changes. In the anterior mediastinum, there were two cases of non-Hodgkin lymphoma and two cases of metastatic carcinoma (squamous cell carcinoma and small cell carcinoma). One case showed necrotizing granulomatous lymphadenitis and was suspected to have tuberculosis, whereas two other cases were inconclusive. In the middle mediastinum, one case of a bronchogenic cyst was diagnosed. In the posterior mediastinum, there was one case of mixed germ cell tumor (teratoma with embryonal carcinoma), two cases of schwannoma and lymphangioma, and one case each of neurofibroma and benign fibrous histiocytoma. In Aroor *et al.* [13], there were 12 (44.44%) cases of lymphoma, five (18.52%) cases of mediastinal tuberculosis, seven (25.93%) cases of bronchogenic carcinoma, and three (11.11%) cases of poorly differentiated metastatic carcinoma. In Dixit *et al.* [14], among the primary mediastinal lesions, the lymphomas (Hodgkin's and non-Hodgkin's lymphoma) were the most common diagnosis in 27 (19.4%) cases, followed by thymic lesions in five (3.5%) cases in the study. Among the nonneoplastic conditions, tuberculosis was the most common (28 cases, 20.1%).

## Conclusion

Malignant conditions (lymphomas and adenocarcinomas) are the most frequently found pathologies of the mediastinum in our locality, followed by sarcoidosis, whereas other pathologies were found rarely. Also, EBUS practice in our locality is increasing beside percutaneous sampling.

## Financial support and sponsorship

Nil.

## Conflicts of interest

There are no conflicts of interest.

## References

- 1 Johnson D, Shah P, Collins P, Wingley C. Heart and mediastinum. In: Standring S. *Gray's anatomy. Chapter 59.* 39th ed. New York: Churchill Livingstone; 2008. 976-977.
- 2 Gupta S, Seaberg K, Wallace MJ, Madoff DC, Morello FA, Ahrar K, *et al.* Imaging-guided percutaneous biopsy of mediastinal lesions: different

- approaches and anatomic considerations. *Radiographics* 2005; **25**:763–786.
- 3 Diacon AH, Schuurmans MM, Theron J, Brundyn K, Louw M, Wright CA, *et al.* Transbronchial needle aspirates: how many passes per target site? *Eur Respir J* 2007; **29**:112–116.
  - 4 Liberman M, Duranceau A, Grunenwald E, Thiffault V, Khreba M, Ferraro P, *et al.* Initial experience with a new technique of endoscopic and ultrasonographic access for biopsy of para-aortic (station 6) mediastinal lymph nodes without traversing the aorta. *J Thorac Cardiovasc Surg* 2012; **144**:787–792.
  - 5 Onat S, Ates G, Avci A, Yildiz T, Birak A, Ozmen A, *et al.* The role of mediastinoscopy in the diagnosis of non-lung cancer diseases. *Therap Clin Risk Manage* 2017; **13**:939–943.
  - 6 Thomsen RW. Mediastinoscopy and video-assisted thoracoscopic surgery: anesthetic pitfalls and complications. *Semin Cardiothorac Vasc Anesth* 2008; **12**:128–132.
  - 7 Juanpere S, Cañete N, Ortuño P, Martínez S, Sanchez G, Bernado L. A diagnostic approach to the mediastinal masses. *Insights Imaging* 2012; **4**:29–52.
  - 8 Stover DG, Eisenberg R, Johnson DH. Anti-N-methyl-D-aspartate receptor encephalitis in a young woman with a mature mediastinal teratoma. *J Thorac Oncol* 2010; **5**:1872.
  - 9 Kawahara K, Miyawaki M, Anami K, Moroga T, Yamamoto S, Tokuiishi K, *et al.* A patient with mediastinal mature teratoma presenting with paraneoplastic limbic encephalitis. *J Thorac Oncol* 2012; **7**:258.
  - 10 Rankin S. [18F]2-Fluoro-2-deoxy-D-glucose PET/CT in mediastinal masses. *Cancer Imaging* 2010; **10**(1A):S156–S160.
  - 11 Devi HJG, Das JK, Pasha M, Prathima KM. Retrospective analysis of mediastinal lesions – tertiary care center experience. *SSRG Int J Med Sci* 2015; **2**:5–11.
  - 12 Karki S, Chalise S. Analysis of mediastinal lesions: a study of 27 cases. *J Pathol Nepal* 2011; **1**:114–117.
  - 13 Aroor AR, Prakasha R, Seshadri S, Teerthanath S, Raghura U. A study of clinical characteristics of mediastinal mass. *J Clin Diagn Res* 2014; **8**:77–80.
  - 14 Dixit R, Shah NS, Goya M, Patil CB, Panjab M, Gupta RC, *et al.* Diagnostic evaluation of mediastinal lesions: Analysis of 144 cases. *Lung India* 2017; **34**:341–348.