

Fayoum experience in the ultrasonographic evaluation of diffuse parenchymal lung disease

Sherif Refaat Abd El Fatah^a, Radwa Ahmed Elhefny^b, Randa Ibrahim Ahmed^c, Doaa Mohamed Abd El Tawab^d

Objective Chest ultrasound has many uses, both diagnostic and interventional. It may be used for the diagnosis of multiple pleural diseases (pleural effusion, pleural masses, and pneumothorax). It is also used in the diagnosis of diseases caused by lung parenchymal lesions, such as neoplasms, pulmonary embolism, pneumonia, and lung abscesses.

Aim This study aimed to evaluate the sonographic features of diffuse parenchymal lung disease (DPLD).

Design This was a prospective study.

Setting The study was carried out at Fayoum University Hospital in Egypt during the period spanning from January 2017 to June 2017.

Patients and methods This study included 120 participants. Sixty of them were diagnosed as having DPLD. For the diagnosis of these cases, we need a full medical history, a detailed clinical examination, spirometry, 6 min walk test, arterial blood gases' analysis, high-resolution computed tomography, and chest ultrasound. The other 60 were studied as controls.

Statistical analysis The data were collected and coded to facilitate data manipulation, and they were double entered into Microsoft Access; the data analysis was performed by using SPSS software, version 18 in Windows 7. The simple descriptive analysis was carried out in the form of numbers and percentages for qualitative data and arithmetic means as central tendency measurement, SDs as measure of dispersion for the quantitative parametric data and the inferential statistic test.

Results There was a female predominance with a wide range of age. Most of the cases were nonsmokers,

Introduction

Diffuse parenchymal lung disease (DPLD) is a group of nonmalignant and noninfectious processes caused by multiple causative agents that may be known or unknown [1].

High-resolution computed tomography (HRCT) may be considered as the gold standard technique for the diagnosis of DPLD, and there are also other noninvasive and invasive technique for diagnosis of DPLD, such as laboratory and serological tests, pulmonary function tests, transthoracic ultrasound, bronchoscopy with a bronchoalveolar lavage and the transbronchial lung biopsy [2].

Chest ultrasonography can play an important complementary role, particularly in the critical care setting where conventional radiography is often suboptimal.

breeding birds, and exposed to biomass. All cases had diffuse bilateral B-lines. There was a negative relation between the Warrick score on the one hand and the B-line number, PaO₂, 6 min walk test, and forced vital capacity on the other hand.

In contrast, a positive relation was demonstrated between the Warrick score and B-line distance and pleural thickness. Most of the studied patients (71.6%) had irregular and thickened pleura and (51.6%) had an abolished lung sliding.

Conclusion Chest ultrasound has a significant role in the diagnosis of DPLD and also in estimating the severity of the disease according to the number and the distance between B-lines.

Multiple B-lines in the combination of thickened and irregular pleural line are highly suggestive of DPLD.

Egypt J Bronchol 2019 13:204–213

© 2019 Egyptian Journal of Bronchology

Egyptian Journal of Bronchology 2019 13:204–213

Keywords: chest ultrasonography, diffuse parenchymal lung diseases, Fayoum governorate

^aProfessor of Chest Diseases and Tuberculosis, Faculty of Medicine, Fayoum University, ^bAssociate Professor of Chest Diseases and Tuberculosis, Faculty of Medicine, Fayoum University, ^cLecturer of Chest Diseases and Tuberculosis, Faculty of Medicine, Fayoum University, ^dResident of Chest diseases and Tuberculosis in Fayoum Chest Hospital

Correspondence to Sherif Refaat Abd El Fatah, MD, Professor of Chest Diseases and Tuberculosis, Faculty of Medicine- Fayoum University, Fayoum University Hospital Faculty of Medicine 63514. Tel: 0100997849; e-mail: sherifrefaat@hotmail.com

Received 20 July 2018 **Accepted** 6 February 2019

Its lack of ionizing radiation, bedside availability, and dynamic imaging capacity afford ultrasound certain advantages over other techniques [3].

Aim of this study

This study aimed to evaluate the sonographic findings of DPLD.

Patients and methods

A case–control prospective study was carried out in the Chest Department, Fayoum University, during the period spanning from January 2017 to June 2017. The study included 120 participants: 60 patients who were

This is an open access journal, and articles are distributed under the terms of the Creative Commons Attribution-NonCommercial-ShareAlike 4.0 License, which allows others to remix, tweak, and build upon the work non-commercially, as long as appropriate credit is given and the new creations are licensed under the identical terms.

diagnosed as having DPLD and 60 controls from the Fayoum governorate. The patients were diagnosed according to the diagnostic algorithm of DPLD [4].

The study protocol was approved by the Ethical Committee of Faculty of Medicine in Fayoum University, and informed consent was obtained from all patients.

Inclusion criteria

- (1) Age: 20–75 years old.
- (2) Sex: male and female individuals.
- (3) From Fayoum governorate.

Exclusion criteria

The cases with pulmonary edema of different causes, pneumonia, pulmonary embolism, and atelectasis were excluded from this study because B-lines may be detected in these cases [5].

All participants were submitted for the following:

The history

- (1) Family history.
- (2) History of breeding birds.
- (3) History of biomass exposure.
- (4) History of respiratory symptoms (chest pain, wheezes, cough, expectorations, dyspnea) with the onset, course, and duration of the presenting symptoms.
- (5) History of smoking.
- (6) Occupational history.
- (7) History of systemic disease, that is, collagen vascular disease.

Full clinical examination

This consisted of both general and local examinations.

Spirometry

Spirometry was carried out by using MiniSpir MIP s.r.l. 00155, Roma, Italy. The results were obtained for forced vital capacity (FVC), forced expiratory volume in 1 s (FEV₁), ratio of FEV₁/FVC (FEV₁/FVC%), and forced expiratory flow at 25–75% of vital capacity.

The values were obtained when the patient exerted his maximum effort to avoid any expected error in diagnosis. The absolute values and the percentages of spirometric parameters predicted from the participant's age, sex, and height were calculated. Restrictive ventilatory defect was defined by spirometric findings of FEV₁/FVC greater than 70% predicted and FVC less than 80% predicted [6].

Arterial blood gases' analysis

Arterial blood gases were analyzed by 'rapid lap analyzer 248' (Siemens Medical Solution, 51 Valley Stream Parkway, Malvern, PA, US) apparatus; the values for the following were recorded and then calculated: oxygen saturation%, PaO₂ (mmHg), PaCO₂ (mmHg), HCO₃ (mEq/L and pH).

6-min walk test

It is measurement of the distance that patients can quickly walk on a flat, hard surface in a period of 6 min. Reference values are 576 m for healthy male patients and 494 m for healthy female patients [7]. Before and after the test, oxygen saturation % was measured by a pulse oximeter, and desaturation was defined as a fall in oxygen saturation to 88% or less during the 6 min walk test [8].

High-resolution computed tomography

The device used was Asteion Toshiba four-slice CT scanner (Toshiba, Canon Medical System, California, USA).

In this study, pulmonary involvement is identified and scored according to the semiquantitative modified Warrick score [9].

Modified Warrick scoring was obtained by summation of the point values of parenchymal abnormality pattern (the severity score), which range from 0 (normal) to 15 (all lesions are present), and the extension score was obtained by localization of the number of pulmonary segments involved in both lungs, which ranged from 0 normal to 15, at which more than nine pulmonary segments are involved.

Thus, the results of summation of the total Warrick score ranged from 0 no involvement to 30, which represent the worst involvement.

The results were expressed as follows:

- (1) Normal: 0 point.
- (2) Mild: more than 8 points.
- (3) Moderate: ranged from 8 to 15 points.
- (4) Severe: ranged from 15 to 30 points.

Chest ultrasound

Chest ultrasound was performed for all participants using Philips ClearVue 320 (Philips, Amsterdam, Netherlands) device.

Lung ultrasound was performed using the low frequency (2.5–5 MHz) convex probe for lung examination and the high frequency (7.5–10 MHz) linear probe for pleural examination.

There are different positions during examination:

Supine (ventral images), sitting (dorsal and lateral images), and raising the arms and crossing them behind the head, leading to extension of the intercostal spaces and facilitating access.

Assessment of the following:

(1) B-lines: The predominant bilateral B-lines (vertical hyperechoic lines) arising from the pleural line that spread towards the edge of the screen without fading, causing erasing of A-lines and move with the lung sliding [10].

A distance between two adjacent B-lines close to the pleural line is measured and expressed in milliliters [11].

A positive region is defined through the presence of three or more B-lines in the longitudinal plane between two ribs. The positive examination is defined through the presence of two or more positive regions on both sides.

The number of B-lines is counted per zone [12].

(2) The lung sliding (to-and-fro dynamic movement of the lung during respiration, which was visible at the pleural line).

(3) Assessment of pleura as regards pleural thickness and pleural surface (either smooth, irregular).

The pleural thickening is known as focal or diffuse echogenic lesions arising from visceral or parietal pleura and the width of which is greater than 3 mm with or without the irregular pleural surface [13].

Statistical analysis

The data were collected and coded to facilitate the data manipulation and double entered into Microsoft Access, and the data analysis was performed by using SPSS software (SPSS Inc. Released 2009. PASW Statistics for Windows, Version 18.0. Chicago: SPSS Inc).

The simple descriptive analysis was carried out in the form of numbers and percentages for qualitative data, and arithmetic means as central tendency measurement, SDs as measure of dispersion for quantitative parametric data and inferential statistic test.

In cases of quantitative parametric data

The dependent Student's *t* test was used to compare measures of two independent groups of quantitative data.

One way analysis of variance test was used to compare more than two independent groups of quantitative data.

For qualitative data

χ^2 test was used to compare two or more than two qualitative groups.

The *P* value less than 0.05 was considered the cut-off value for significance.

Results

This study included 60 patients, of whom 54 (90%) were female patients and six (10%) were male patients; the age group ranged from 20 to 75 years, with a mean of 47.5 ± 13.6 years.

Thirty percent of cases presented with dyspnea only, 36.7% presented with dyspnea and cough, and, finally, 33.3% of them presented with dyspnea, cough, and wheezing.

Most of the patients were exposed to biomass and breeding birds (80%), and 90% of patients were nonsmokers (41.6%, $n=25$) having clubbing.

These data are clarified in Table 1, which represents the demographic data of the studied patients.

By HRCT, most patients (50%, $n=30$) were diagnosed as having hypersensitivity pneumonitis and 16.6% ($n=10$) were diagnosed as having idiopathic pulmonary fibrosis. This is clarified by Table 2.

The mean and SD of B-lines' number was 6.3 ± 2.1 . The B-line distance ranged from 3 to 12 mm with mean \pm SD of 7.8 ± 2.7 .

The range of the pleural thickness in all studied patients was from 2 to 19 mm with mean \pm SD of 9.1 ± 5.9 .

Most cases had thickened pleural line (71.7%, $n=43$), whereas 28.3% ($n=17$) had normal pleural thickness with a mean \pm SD of 11.6 ± 5.1 and 2.7 ± 0.33 , respectively.

There was an irregular pleural line in 71.6% ($n=43$), whereas 28.3% ($n=17$) had a regular pleural line. All these data are clarified in Table 3.

The pulmonary involvement is scored according to the semiquantitative HRCT scoring system (modified Warrick score), which is shown in Table 4.

According to this score, the pulmonary involvement was classified into three groups:

Table 1 Illustration of the demographic data of the studied group

Variables	Cases	Control	P value	Significance
Age (years)			0.1	NS
Mean±SD	13.6±47.5	9.4±44.1		
Range	20–75			
Sex [n (%)]			0.8	NS
Male	6 (10)	8 (13.3)		
Female	54 (90)	52 (86.7)		
Smoking [n (%)]			0.9	NS
No	54 (90)	54 (90)		
Yes	6 (10)	6 (10)		
Occupation [n (%)]			0.7	NS
Not risky	56 (93.3)	58 (96.7)		
Risky	4 (6.7)	2 (3.3)		
Biomass [n (%)]			>0.001	NS
Yes	48 (80)	16 (26.7)		
No	12 (20)	44 (73.3)		
Breeding birds [n (%)]			>0.001	NS
Hens, ducks	23 (38.3)	16 (26.7)		
Hens, ducks, pigeons	25 (41.7)	0		
No breeding	12 (20)	44 (73.3)		
Clubbing [n (%)]	25 (41.6)			
Symptoms [n (%)]				
Dyspnea	18 (30)			
Dyspnea and cough	22 (36.7)			
Dyspnea, cough, and wheezing	20 (33.3)			

Table 2 The diagnosis of studied patients

Diagnosis	n (%)
Hypersensitivity pneumonitis	30 (50)
Nonspecific interstitial pneumonia	9 (15)
Idiopathic pulmonary fibrosis	10 (16.6)
Sarcoidosis	5 (8.3)
Lymphangioleiomyomatosis	1 (1.6)
Pleural parenchymal fibroelastosis	1 (1.6)
Rheumatoid arthritis	4 (6.6)

- (1) Mild group (26.7%, $n=16$) with a mean±SD of 6.1 ±0.9.
- (2) Moderate group (38.3%, $n=23$) with a mean±SD of 10.9±2.2.
- (3) Severe group (35%, $n=21$) with a mean±SD of 19.3±2.8.

These data are illustrated in Table 5.

Table 6 illustrates that there is a significant positive relation with P value less than 0.05 between Warrick score and the distance between B-lines; which indicated that an increase in Warrick score was associated with an increase in distance between B-lines. Moreover, there is a significant negative relation between Warrick score and the following: number of B-lines, PaO₂, 6 min walk test, FVC, and pleural line thickness, which indicated that an increase in Warrick score was associated with a decrease in all these variables.

In contrast, there was no relation between Warrick score and duration of symptoms. Figures 1–6 show these relations.

Table 7 illustrates that there is a significant difference between the different degrees of Warrick score according to regularity, plural line thickness, and B-line distance, with a high percentage of irregular and thickened plural line and wide distance being noticed among severe degree followed by moderate degree cases.

There was a statistically significant difference between the different degrees of Warricks score according to B-line numbers, 6 min walk test, and FVC, with a high mean among mild degree of severity cases. This is clarified by Figs 7 and 8.

Discussion

It has been highlighted that chest ultrasound is sensitive to variations of pulmonary content and balance between air and fluids. In the normal lung, the ultrasound waves are completely reflected by the air, whereas, in the lung diseases that impair alveolar air content and increase the interstitial and alveolar fluids, a particular artifact will be created [14].

The ultrasound evaluation of DPLD is determined by the presence and quantification of B-lines, they are

Table 3 Thoracic ultrasound parameters in total studied patients

Sonographic finding	Case (N=60)	Control (N=60)
Pleural line [n (%)]		
Smooth	17 (28.3)	100
Thickened	43 (71.6)	0
Regular	17 (28.3)	100
Irregular	43 (71.6)	
Pleural thickness (mm) in total studied patients (mean±SD)	9.1±5.9	
Pleural thickness for the group with normal pleural thickness (mean±SD)	2.7±0.33	
Pleural thickness for the group with thickened pleural line (mean±SD)	11.6±5.1	
B line		
Number (mean±SD)	2.1±6.3	
Distance (mm) (mean±SD)	7.8±2.7	
Lung sliding [n (%)]		
Present	29 (48.3)	100
Abolished	31 (51.6)	

Table 4 Semiquantitative modified Warrick score

	Grading (points)
Severity score (parenchymal alteration pattern)	
Ground-glass opacities	1
Irregular pleural margins	2
Septal/subpleural lines	3
Honeycombing	4
Subpleural cysts	5
Maximal severity score	15
Extension score (number of bronchopulmonary segments)	
Segments 1–3	1
Segments 4–9	2
9th segment involved	3
Bilateral involvement	4
Maximal extent score	15

Table 5 Classification of diffuse parenchymal lung diseases' severity according to total Warrick score

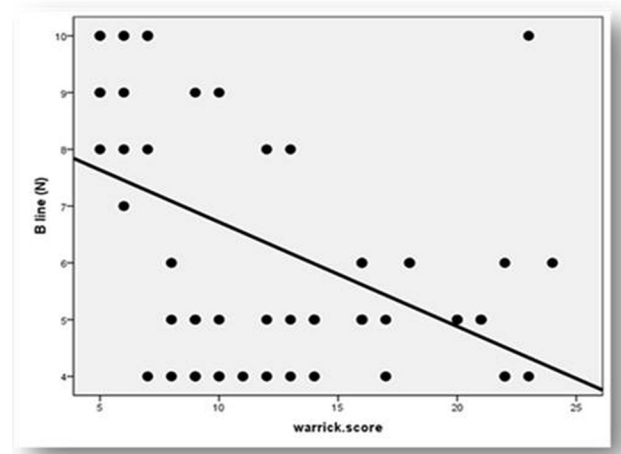
Items	Mild (S≥8)	Moderate (S=8–15)	Severe (S≤15–30)
Total Warrick score (mean±SD)	6.1±0.9	10.9±2.2	19.3±2.8
n (%)	16 (26.7)	23 (38.3)	21 (35)

Table 6 Correlation between Warrick score and other variables among cases

Variables	Warrick score		
	r	P value	Significance
B-lines (n)	-0.49	<0.001	HS
Distance between B-lines (mm)	0.81	<0.001	HS
Symptoms' duration	0.16	0.2	NS
PaO ₂	-0.81	<0.001	HS
6 min walk test (m)	-0.33	0.01	S
Forced vital capacity	-0.74	<0.001	HS
Thickness	0.82	<0.001	HS

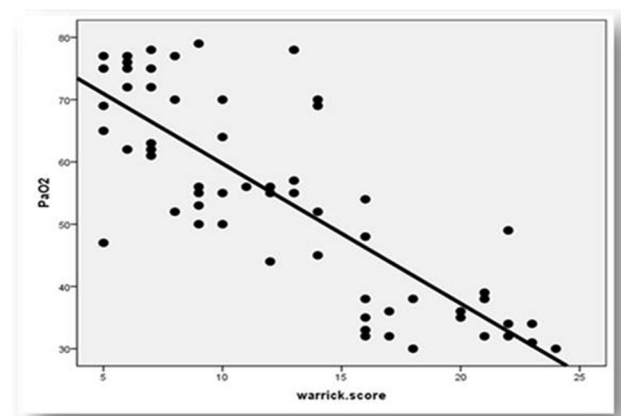
HS, highly significant; S, significant. The bold of (r) value means negative correlation with warrick score, the bold of P value means highly significant.

Figure 1



Illustrates the relation between Warrick score and B-line number.

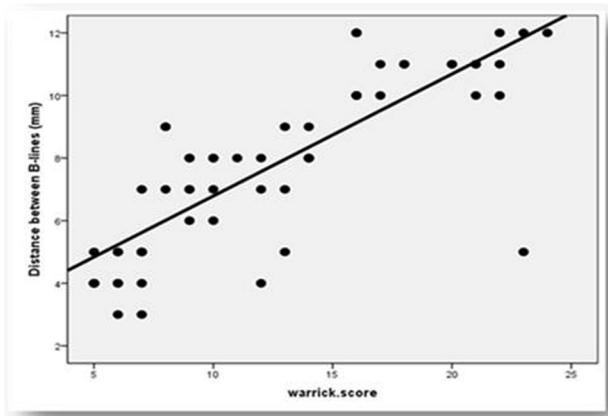
Figure 2



Illustrates the relation between Warrick score and B-line distance.

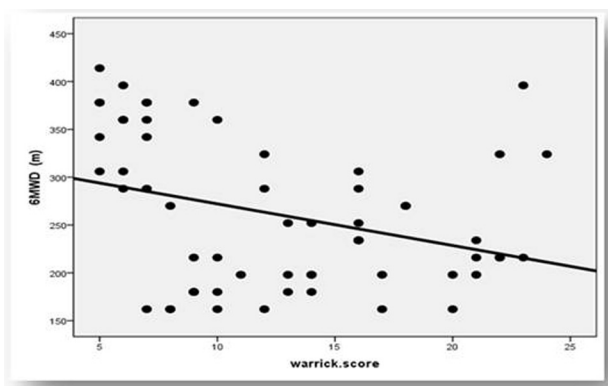
generated by reflection of the ultrasound beams from the thickened subpleural interlobar septa at the lung surface interface [15].

Figure 3



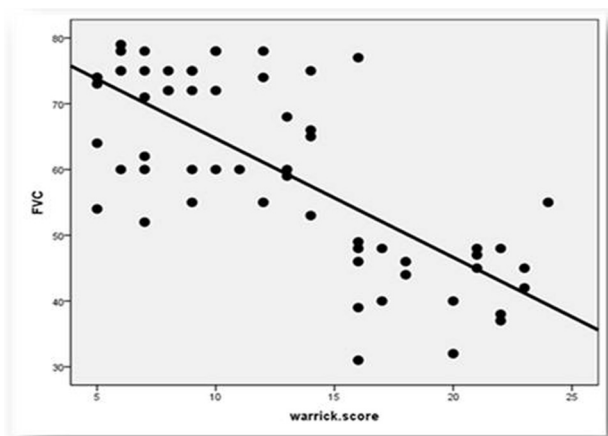
Illustrates the relation between Warrick score and PaO₂.

Figure 4



Illustrates the relation between Warrick score and 6MWT. 6MWT, 6 min walk test.

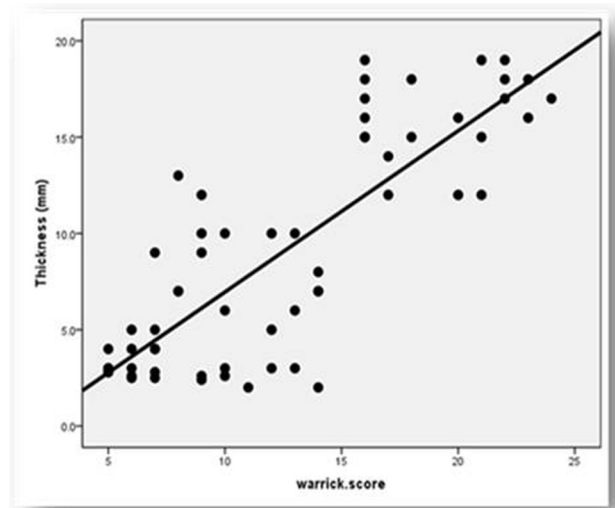
Figure 5



Illustrates the relation between Warrick score and FVC. FVC, forced vital capacity.

In this study, 30% of cases presented with dyspnea only, 36.7% presented with dyspnea and cough, and, finally, 33.3% of them presented with dyspnea, cough, and wheezing. The studied group showed a female

Figure 6



Illustrates the relation between Warrick score and pleural thickness.

predominance with a wide range of age (20–75). Most of them were breeding birds and exposed to biomass (80%, $n=48$), and 90% were nonsmokers.

By HRCT most of them were diagnosed as having hypersensitivity pneumonitis (50%, $n=30$), nine (15%) patients as having nonspecific interstitial pneumonia, 10 (16.6%) patients as having idiopathic pulmonary fibrosis, five (8.3%) patients as having sarcoidosis, one (1.6%) patient as having lymphangioleiomyomatosis, one (1.6%) patient as having pleural parenchymal fibroelastosis, and four (6.6%) patients as having rheumatoid arthritis.

By using transthoracic ultrasound, all patients had diffuse and more than three B-lines bilaterally. The best time to see these B-lines is during the real-time examination, and this seems to be due to some lines being less clarified on frozen sonograms.

In this study, there are at least four B-lines per scan. Mean and SD of the B-lines' number was 6.3 ± 2.1 , whereas the distance between two adjacent B-lines ranged from 3–12 mm, and mean \pm SD was 7.8 ± 2.7 . This is illustrated in Table 3.

In this study, pulmonary involvement is scored according to semiquantitative HRCT score systems (modified Warrick score), which is shown in Table 4.

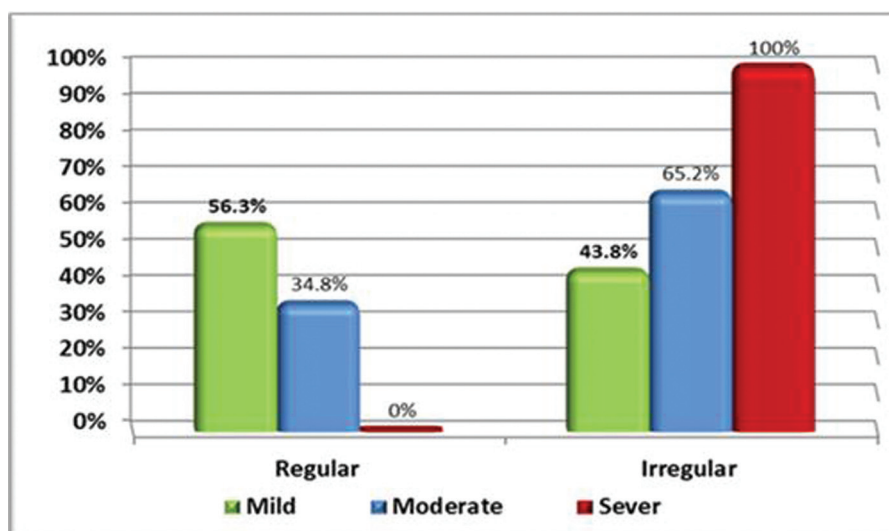
According to this score, the pulmonary involvement was classified into three groups:

- (1) Mild group (26.7%, $n=16$) with a mean \pm SD of 6.1 ± 0.9 .

Table 7 Comparison of pleural line and other findings in different severity degrees among cases

Variables	Warrick score			P value	Significance
	Mild	Moderate	Severe		
Regularity of pleural line [n (%)]					
Regular	9 (56.3)	8 (34.8)	0 (0)	<0.001	HS
Irregular	7 (43.8)	15 (65.2)	21 (100%)		
Plural line thickened [n (%)]					
Not thickened	9 (56.3)	8 (34.8)	0 (0)	<0.001	HS
Thickened	7 (43.8)	15 (65.2)	21 (100)		
Others					
B-line distance (mm)	4.44±0.96	7.43±1.3	10.7±1.5	<0.001	HS
Pleural line thickness	3.8±1.6	6.4±3.4	16.1±2.3	<0.001	HS
Number of B-lines	8.8±1.6	5.3±1.6	5.3±1.3	<0.001	HS
6 min walk test (m)	339.8±60.6	220.7±63.8	245.1±57.6	<0.001	HS
Forced vital capacity	69±8.9	67.7±8.3	45±9.4	<0.001	HS
Warrick score	6.1±0.9	10.9±2.2	19.3±2.8	<0.001	HS
Lung sliding [n (%)]					
Present	16 (26.7)	13 (21.6)		<0.001	HS
Abolished		10 (16.6)	21 (35)		

HS, highly significant. The bold means the highest values and the bold of P value means high significant.

Figure 7

Illustrates the regularity of pleural line between different severity degrees among cases.

- (2) Moderate group (38.3%, $n=23$) with a mean±SD of $10.9±2.2$.
- (3) Severe group (35%, $n=21$) with a mean±SD of $19.3±2.8$.

These data are illustrated in Table 5.

The same results were obtained by Mohammadi *et al.* [16]; they found a relation between the Warrick score and the severity of pulmonary involvement ($r=0.695$, $P<0.001$).

In this study, there was a significant negative relation, with P value less than 0.001, between the Warrick score and number of B-lines (Fig. 1).

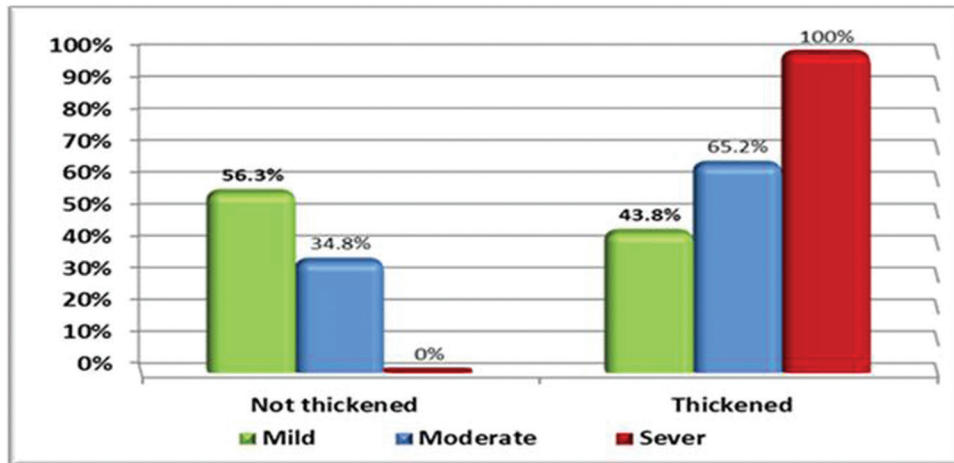
However, there is a significant positive relation, with P value less than 0.05, between Warrick score and B-lines' distance (Fig. 2).

These data are shown in Table 6.

These results were in agreement with Hasan and Makhlof [17], who evaluated 61 patients with DPLD, as they concluded that the B-lines seem numerous, with a narrow distance between them in those with early DPLD.

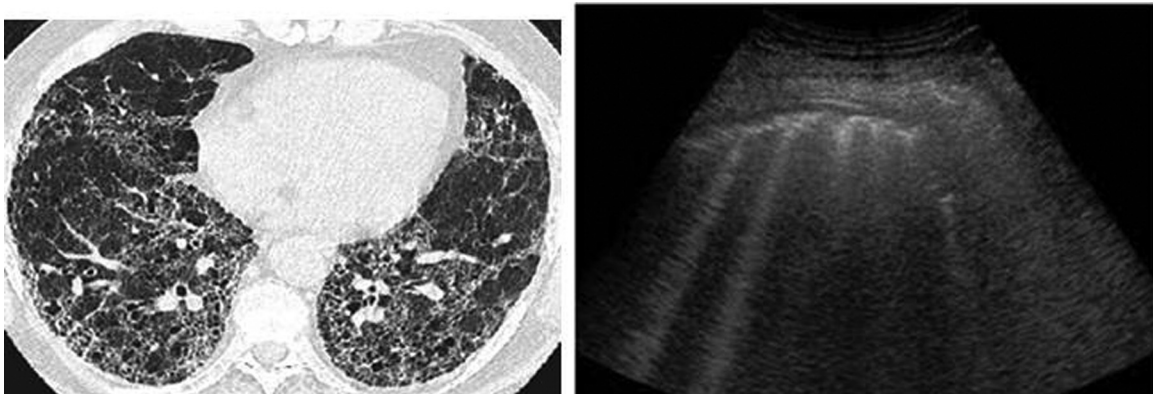
They illustrated that there is a relation between the B-line distance and the severity of the disease on chest HRCT at which B3 (the

Figure 8



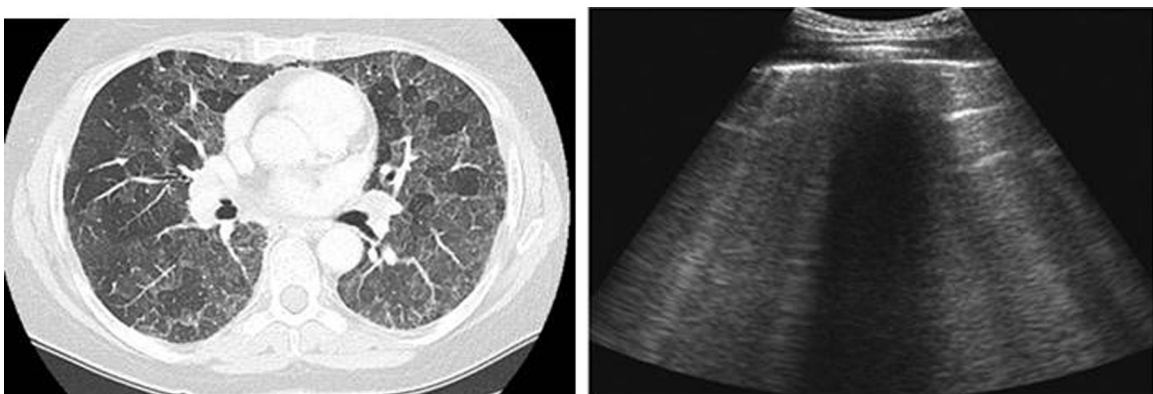
Illustrates the thickness of the pleural line among different severity degrees among cases.

Figure 9



HRCT chest of a patient with HP showed ground-glass opacity. Ultrasound of the same patient showed diffuse B-lines with a narrow distance between them (about 3 mm). HP, hypersensitivity pneumonitis; HRCT, high-resolution computed tomography.

Figure 10



HRCT of the chest showed subpleural reticulation with honeycombing. Ultrasound of the same patient showed diffuse B-lines with a wide distance between them (about 7 mm). HRCT, high-resolution computed tomography.

distance was 3 mm) represents ground-glass opacity (Fig. 9) and B7 (the distance was 7 mm) represents extensive fibrosis and honeycombing (Fig. 10).

Also these results are incompatible with the results of Farag *et al.* [18] who found that the degree of interstitial affection on chest HRCT, which was detected by the modified Warrick score, is inversely

correlated with the total number of B-lines among mild, moderate, and severe groups.

In the current study, there is a significant negative correlation between Warrick score and the following (and they are): PaO₂, 6 min walk test, and FVC% (Figs 3–5), which indicates that the well-established pulmonary fibrosis in HRCT may be associated with more impairment in pulmonary function test (PFTS).

Hence, the severe group has the lowest mean of FVC% (45±9.4), and this is shown in Table 7.

According to the pleural line, the linear probe was used for more details.

In this study, the range of the pleural thickness in all studied patients was from 2 to 19 mm with mean±SD of 9.1±5.9 as shown in Table 3.

Most cases had thickened pleural line (71.7%, n=43), whereas 28.3% (n=17) had normal pleural thickness with a mean±SD of 11.6±5.1 and 2.7±0.33, respectively.

There was an irregular pleural line in 71.6% (n=43), whereas 28.3% (n=17) had a regular pleural line. All these data are clarified in Table 3.

The mild group had pleural thickness with a mean±SD of 3.8±1.6, the moderate group had pleural thickness with a mean±SD of 6.4±3.4, and the severe group had pleural thickness with a mean±SD of 16.1±2.3, and this is clarified in Table 7.

Hence, there is a positive correlation between the Warrick score and pleural thickness (Fig. 6).

This was compatible with the results of Farag *et al.* [18] who found that there was an important significant difference of pleural thickness in millimeter (mean ±SD) between all groups involved.

In this study, 43.8% of the mild group had irregular thickened pleural line, 65.2% of the moderate group had irregular thickened pleura line, whereas 100% of severe cases showed irregular thickened pleural line (Figs 7 and 8).

These data are illustrated in Table 7.

These results were supported by the study of Farag *et al.* [18], as they demonstrated that 44.4% of mild

cases had irregular thickened pleural line just at the lung base, whereas all severe cases showed irregular pleural line over the whole lung (100%), thickened pleura (83.3%), and the moderate group showed less value for irregularity (83.3%) and thickening (54.2%).

Table 7 illustrates that the lung sliding was present in the mild group, whereas it is abolished in severe cases of parenchymal affection in HRCT.

This result was in agreement with Agmy *et al.* [19] who found that abolished lung sliding had a highly significant positive correlation with reticular opacities on multidetector computed tomography (MDCT), and this could be attributed to the fact that fibrosis, which affects the visceral pleura, will be followed by restriction of lung ventilation and expansion, leading to impairment of lung sliding.

Limitations of the study

The diffusion capacity of carbon monoxide and total lung capacity were not measured, and the number of patients (60) is small, because the study was controlled by a specific duration (January 2017 to June 2017).

Conclusion

Chest ultrasound has an important role for the diagnosis and evaluation of DPLD patients. Numerous B-lines that are distributed over the lung surface constitute the most important sonographic feature in combination with a thickened irregular pleural line and the abolished lung sliding.

Chest ultrasound may give an idea about early or advanced DPLD through the number of B-lines and the B-line distance.

Financial support and sponsorship

Nil.

Conflicts of interest

There are no conflicts of interest.

References

- Gomez AD, King TE Jr. Classification of diffuse parenchymal lung disease: in diffuse parenchymal lung disease. *Prog Respir Res Basel, Karger* 2007; **36**:2–10.
- American Thoracic Society/European Respiratory Society. International multidisciplinary consensus classification of the idiopathic interstitial pneumonias. *Am J Respir Crit Care Med* 2002; **165**:277–304.
- Stephens NJ, Pilcher JM. The diagnostic role of ultrasound in the chest. *Ultrasound J* 2007; **15**:148–158.
- Saha K. Review article. Interstitial lung disease: diagnostic approach. *J Assoc Chest Physicians* 2014; **2**:3–15.

- 5 Copetti R, Soldati G, Copetti P. Chest sonography. a useful tool to differentiate acute cardiogenic pulmonary edema from acute respiratory distress syndrome. *Cardiovasc Ultrasound* 2008; **6**:16.
- 6 Aaron SD, Dales RE, Cardinal P. How accurate is spirometry at predicting restrictive pulmonary impairment? *Chest* 1999; **115**:869–873.
- 7 Nici L, ZuWallack R. An official American Thoracic Society Workshop Report: the integrated care of the COPD patient. *Proc Am Thorac Soc* 2012; **9**:9–18.
- 8 American Association for Respiratory Care. Clinical practice guideline: exercise test for evaluation of hypoxemia and/or desaturation. *Respir Care* 2001; **46**:514–522.
- 9 Warrick JH, Bhalla M, Schabel SI, Silver RM. High resolution computed tomography in early scleroderma lung disease. *J Rheumatol* 1991; **18**:1520–1528.
- 10 Bolliger CT, Herth FJ, Mayo PH, Miyazawa T, Beamis JF (Eds). *Clinical chest ultrasound: from the ICU to the bronchoscopy suite, Prog Respir Res*. Switzerland: Karger Medical and Scientific Publishers; 2009. 22–33.
- 11 Lichtenstein D, Mezière G, Biderman P, Gepner A. The comet-tail artifact: an ultrasound sign ruling out pneumothorax. *Intensive Care Med* 1999; **25**:383–388.
- 12 Volpicelli G, Elbarbary M, Blaivas M. International evidence-based recommendations for point of care lung ultrasound. *Intensive Care Med* 2012; **38**:577–591.
- 13 Tsai TH, Yang PC. Ultrasound in the diagnosis and management of pleural disease. *Curr Opin Pulm Med* 2003; **9**:282–290.
- 14 Piette E, Daoust R, Denault A. Basic concepts in the use of thoracic and lung ultrasound. *Curr Opin Anaesthesiol* 2013; **26**:20–30.
- 15 Soldati G, Copetti R, Sher S. Sonographic interstitial syndrome. *The sound of lung water. J Ultrasound Med* 2009; **28**:163–74.
- 16 Mohammadi A, Oshnoei S, Ghasemi-Rad M. Comparison of a new modified lung ultrasonography technique with high-resolution CT in the diagnosis of the alveolo-interstitial syndrome of systemic scleroderma. *Med Ultrasound* 2014; **16**: 27–31.
- 17 Hasan A, Makhoul H. B-lines: trans thoracic chest ultrasound signs useful in assessment of interstitial lung diseases. *Ann Thorac Med* 2014; **9**:99–103.
- 18 Farag T, Adawy Z, Sakb L. Transthoracic ultrasonographic features of diffuse parenchymal lung diseases. *Egypt J Bronchol* 2017; **11**:179–187.
- 19 Agmy G, Sayed S, Said A, Kasem A. Assessment of transthoracic sonography in patients with interstitial lung diseases. *Egypt J Bronchol* 2016; **10**:105–112.