Lung rockets and pulmonary functions

Sherif R.A. El-Fatah, Radwa A. El-Hefny, Randa I. Ahmed, Doaa M.A. El-Tawab

Introduction The ultrasound (US) of the chest is useful in the diagnosis of different parenchymal, pleural, and chest wall diseases. The US is preferred because no radiation is used (safe during pregnancy), is not expensive, is easy portability, provides real-time imaging, and has the ability to make a dynamic imaging.

Aim This study aimed for the correlation between B-lines and spirometry, arterial blood gases, 6-minute walk test (6MWT), and pulmonary artery systolic pressure (PASP) in patients with diffuse parenchymal lung disease (DPLD).

Design A prospective study was conducted.

Setting The study was conducted at Fayoum University Hospital in Egypt between January 2017 and June 2017.

Patients and methods This study was done on 60 patients with DPLD. They were subjected to a full medical history, a detailed clinical examination, high-resolution computed tomography, echocardiography, arterial blood gases analysis, spirometry, 6MWT, and chest US.

Results The studied group showed female predominance, with 54 (90%) patients. They had a wide range of age from 20 to 75 years, and their mean age was 47.5±13.6 years. Most of them were involved in breeding birds, exposed to biomass, and nonsmokers. The studied patients had bilateral B-lines. The number of B-lines was positively correlated with PaO_2, 6MWT, forced vital capacity, and PASP and negatively correlated with high-resolution computed tomography affection, whereas the distance between B-lines was inversely correlated with each of PaO_2, numbers of B-line, 6MWT, forced vital capacity, and PASP. Most of patients had irregular and thickened pleura (71.6%), and abolished lung sliding was seen in 51.6%.

Conclusion Chest US may be used in the evaluation of DPLD. Multiple B-lines with thickened and irregular pleural line are suggestive of DPLD.

Egypt J Bronchol 2019 13:424–434

Egyptian Journal of Bronchology 2019 13:424–434

Keywords: chest ultrasonography, diffuse parenchymal lung diseases, pulmonary artery systolic pressure

Department of Chest Diseases and Tuberculosis, Faculty of Medicine, Fayoum University, Faiyum, Egypt

Correspondence to Prof. Sherif Refaat Abd El Fatah, MD, Professor of Chest Diseases and Tuberculosis, Faculty of Medicine, Fayoum University, Fayoum University Hospital Faculty of Medicine 63514, Faiyum, Egypt. Tel: 01009997849;
e-mail: sherifrefaat@hotmail.com

Received 20 July 2018 **Accepted** 6 February 2019

Introduction

Diffuse parenchymal lung diseases (DPLD) are a collection of diseases that are characterized by combinations of inflammation and fibrosis, which involve the space present between alveolar epithelium and the endothelial basement membrane [1].

The ultrasound (US) of the chest is important in the diagnosis of a different range of parenchymal, pleural, and chest wall diseases [2].

In patients with DPLD, subpleural interlobular septae become thickened by the deposition of collagen and fibrous tissues. By investigating lung surface by transthoracic US, a great impedance gradient between thickened septae and the air in lung leads to deflection of the US beams, which causes appearance of diffuse B-lines all over lung surface [3].

Lung rockets (three or more B-lines) are defined as being strongly hyperechoic, laser and vertical lines, which arise from pleura and extend to bottom of the field of view and move synchronously with the lung sliding [4].

Aim

This study aimed for the relation between the B-lines and spirometry, arterial blood gases, 6-minute walk test (6MWT), and pulmonary artery systolic pressure (PASP) in patients with DPLD.

Patients and methods

A prospective study was conducted in Chest Department, Fayoum University, between January 2017 and June 2017. The study was done on 60 patients with DPLD from Fayoum Governorate.

The study protocol was approved by the Ethics Committee of the Faculty of Medicine Fayoum University, and informed consent was obtained from all patients.

Inclusion criteria

The following were the inclusion criteria:

Figure 1

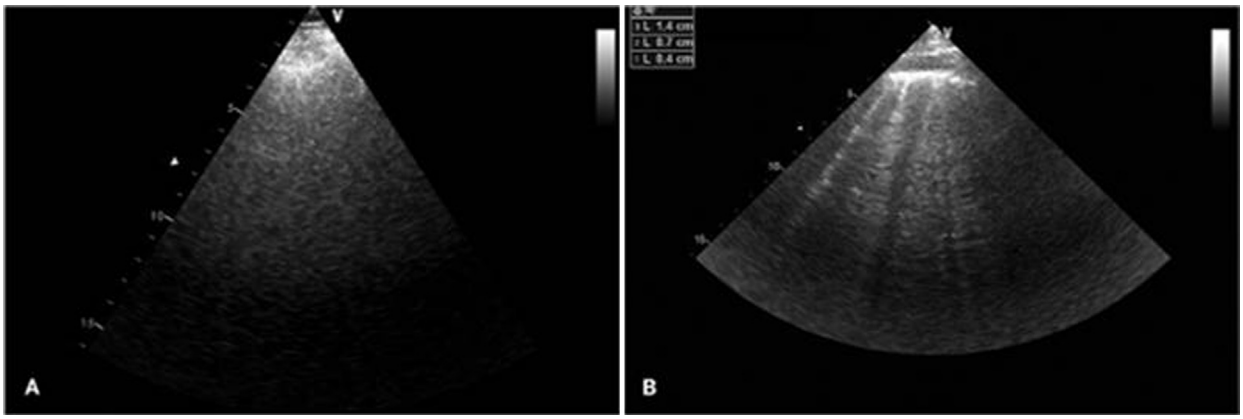

(a) Normal lung without B − lines in a healthy participant. (b) Multiple B − lines in a patient with diffuse parenchymal lung disease.

Age from 20 to 75 years old.
Sex: male and females.
From Fayoum governorate.

The diagnosis of DPLD depends on history, physical examination, high-resolution computed tomography (HRCT), flow-volume loop, and desaturation in 6MWT.

Exclusion criteria

Patients with pulmonary edema of different causes, pneumonia, atelectasis, and pulmonary embolism should be excluded from this study, because B-lines may be detected in these cases [5].

All participants were subjected to the following:

(1) Full history taking:
  (a) History of smoking.
  (b) Occupational history.
  (c) Family history.
  (d) History of breading birds.
  (e) History of biomass exposure.
  (f) History of respiratory symptoms (eg. cough, expectorations, dyspnea, chest pain, and wheezes) with the onset, course, and duration of the presenting symptoms.
  (g) History of systemic disease, that is, collagen vascular disease.
  (h) The history of medication usage.
(2) Full clinical examination: general and local chest examination.
(3) HRCT.
(4) Arterial blood gases analysis.
(5) 6MWT.
(6) Spirometry.
(7) Echocardiography: for estimation of PASP.
(8) Chest US

Lung US was done for all patients using Philips ClearVue 320 (Philips, Amsterdam, Netherlands) device.

Lung US was done by using a low-frequency (2.5–5 MHz) convex probe in the lung examination and the high-frequency (7.5–10 MHz) linear probe in pleural examination.

Patient position

The patients were assessed in the following positions:

(1) Sitting (dorsal and lateral images).
(2) Supine (ventral images).
(3) Raise the arms and crosse them behind the head to make the intercostal spaces extended and to facilitate access.

The important sonographic features in cases of diffuse parenchymal lung disease

B-lines

B-lines, which were previously called the comet-tail artifacts, were generated from thickened interlobular septa at lung wall interface. They were defined as the well-defined, vertical, hyperechoic and dynamic lines that originate from pleural line, and then spreading like laser ray to the edge of screen. This was illustrated by (Fig. 1).

The B-lines are visible under the real-time examination because some of them may appear less clarified on frozen sonograms.

The positive region was defined by the presence of three or more B-lines in the longitudinal plane between the two ribs. The positive examination was defined by the presence of two or more positive areas bilaterally.

The B-lines' number per scan was counted, and the B-lines' distance was measured, and then average was calculated in millimeters [6]. This was illustrated in Table 4.

Pleura

(1) Detection of lung sliding under real-time examination.
(2) Detection whether the pleural line is irregular or smooth.
(3) Estimation of pleural thickness: measure the pleural line thickness in all zones and then calculate the mean value. Pleura was considered thickened if its thickness was more than 3 mm [7].

Statistical analysis

The data are collected and coded to facilitate the data manipulation and double entered to Microsoft Access, and the data analysis is performed by using SPSS software version 18 in Windows 7 (SPSS Inc. Released 2009, PASW Statistics for Windows, Version 18.0. Chicago: SPSS Inc., USA).

The simple descriptive analysis in the form of numbers and percentages for qualitative data, and the arithmetic means as central tendency measurement and SD as the measurement of dispersion for quantitative parametric data and inferential statistic test.

Table 1 Illustrate the demographic data of the studied group

Variables	Cases
Age (years)	
Mean±SD	13.6±47.5
Range	20–75
Sex [*n* (%)]	
Male	6 (10)
Female	54 (90)
Smoking [*n* (%)]	
No	54 (90)
Yes	6 (10)
Occupation [*n* (%)]	
Not risky	56 (93.3)
Risky	4 (6.7)
Biomass [*n* (%)]	
Yes	48 (80)
No	12 (20)
Breeding birds [*n* (%)]	
Hens and ducks	23 (38.3)
Hens, ducks, and pigeons	25 (41.7)
No breading	12 (20)
Clubbing [*n* (%)]	25 (41.6)
Dyspnea [*n* (%)]	18 (30)
Dyspnea and cough [*n* (%)]	22 (36.7)
Dyspnea, cough, and wheezing [*n* (%)]	20 (33.3)

Table 2 Represent high-resolution computed tomography findings in studied patients

HRCT finding	Cases (*n*=60) [*n* (%)]
Reticulation	21 (35)
Traction bronchiectasis	18 (30)
Cystic	17 (28.3)
GGO	15 (25)
Nodular	15 (25)
Mosaic	13 (21.7)
Honey combing	10 (16.7)

GGO, ground glass opacity; HRCT, high-resolution computed tomography.

Table 3 The diagnosis of studied patients

Diagnosis [n (%)]	
Hypersensitivity pneumonitis	30 (50)
Nonspecific interstitial pneumonia	9 (15)
Idiopathic pulmonary fibrosis	10 (16.6)
Sarcoidosis	5 (8.3)
Lymphangioleiomyomatosis	1 (1.6)
Pleural parenchymal fibroelastosis	1 (1.6)
Rheumatoid arthritis	4 (6.6)

Table 4 Thoracic ultrasound parameters in total studied patients

Sonographic finding	Case (*n*=60)
Pleural line [*n* (%)]	
Smooth	17 (28.3)
Thickened	43 (71.6)
Regular	17 (28.3)
Irregular	43 (71.6)
Pleural thickness in mm in total studied patients (mean±SD)	9.1±5.9
Pleural thickness for the group with normal pleural thickness (mean±SD)	2.7±0.33
Pleural thickness for the group with thickened pleural line (mean±SD)	11.6±5.1
B-line	
Number (mean±SD)	2.1±6.3
Distance (mean±SD) (mm)	7.8±2.7
Lung sliding [*n* (%)]	
Present	29 (48.3)
Abolished	31 (51.6)

Table 5 Correlation between numbers of B-lines with other variables among cases

Variables	Numbers B-lines (*n*)		
	R	*P* value	Significant
PaO_2	0.39	0.002	HS
6MWT (m)	0.91	<0.001	HS
FVC	0.36	<0.001	HS
PASP	0.93	<0.001	HS
HRCT findings	-0.49	<0.001	HS

FVC, forced vital capacity; HRCT, high-resolution computed tomography; HS, highly significant; 6MWT, 6-minute walk test; PASP, pulmonary artery systolic pressure.

Figure 2

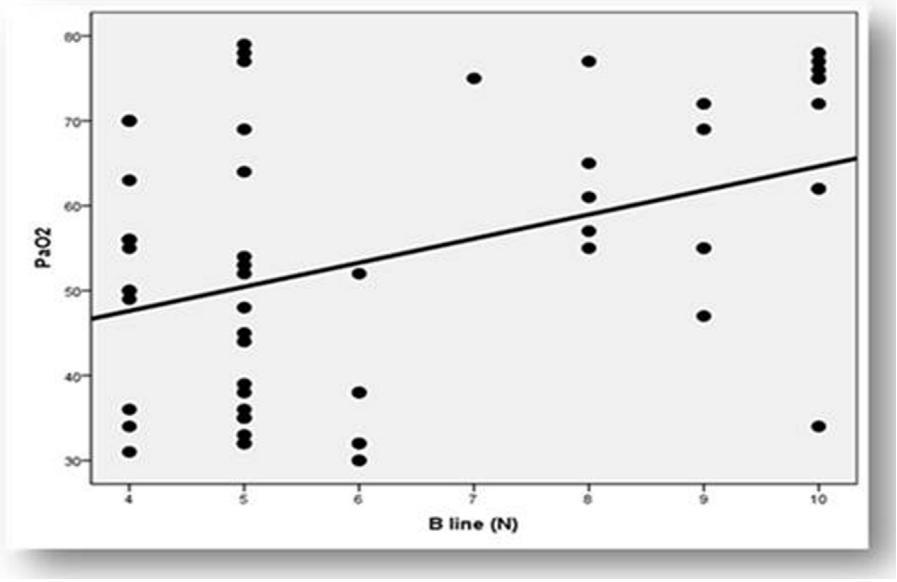

The relation between B-line number and PaO_2.

Figure 3

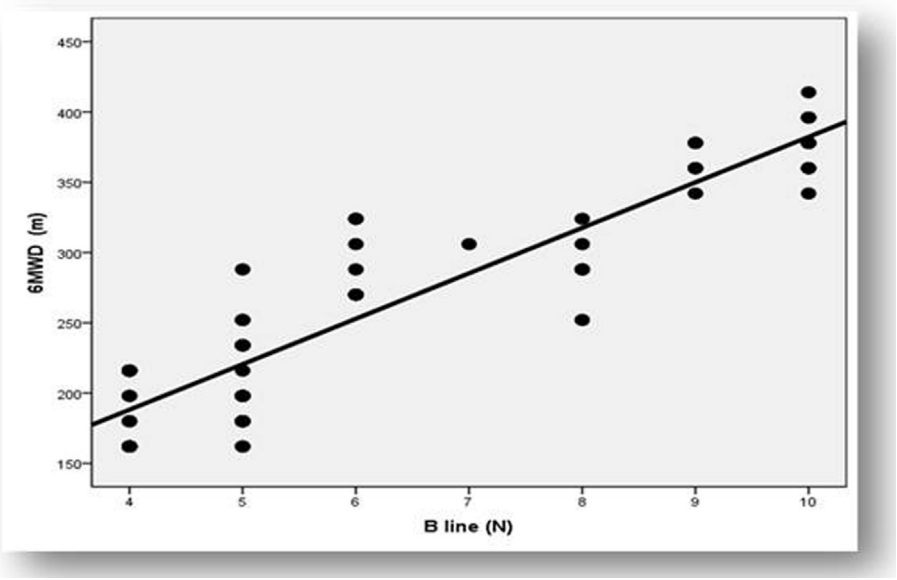

The relation between B-line number and 6-minute walk test (6MWT).

Results

The age range of the patients in the current study was 20–75 years, and their mean was 47.5±13.6 years. They were predominantly females with 54 (90%) patients, and males represented six (10%) patients.

All patients presented with dyspnea, where 30% of cases presented with dyspnea only, 36.7% presented with dyspnea and cough, and 33.3% of them presented with dyspnea, cough, and wheezing.

Most of the patients were into breeding birds and were exposed to biomass (80%), and 90% of patients were nonsmokers. Moreover, clubbing was present in 41.6% (n=25) (Table 1).

This was clarified in Table 1, which represents the demographic data of the studied patients. HRCT findings were illustrated in Table 2.

By HRCT, most patients (50%, n=30) were diagnosed as having hypersensitivity pneumonitis and 16.6% (n=10) were having idiopathic pulmonary fibrosis (IPF), and this is illustrated in Table 3.

Figure 4

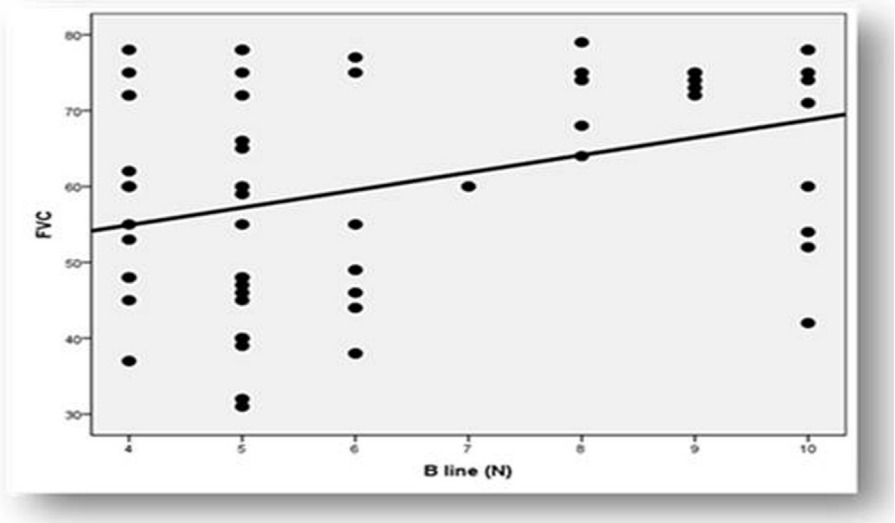

The relation between B-line number and forced vital capacity (FVC).

Figure 5

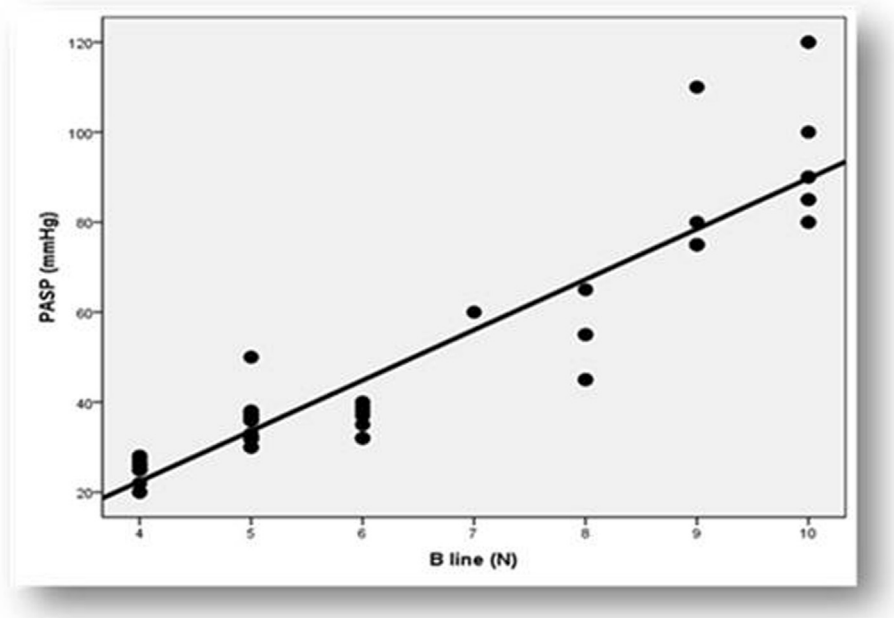

The relation between B-line number and pulmonary artery systolic pressure (PASP).

The mean±SD of B-line number was 6.3±2.1. The B-line distance ranged from 3 to 12 mm, with mean±SD of 7.8±2.7. The range of the pleural thickness in all studied patients was from 2 to19 mm, with mean±SD of 9.1±5.9.

Most cases had irregular thickened pleural line (71.7%, *n*=43), with mean±SD of 11.6±5.1. These data are illustrated in Table 4.

Table 5 clarifies the positive correlation between number of B-lines and each of PaO_2, 6MWT, forced vital capacity (FVC), and PASP level and the negative correlation between B-lines number and HRCT findings. These relations were clarified by Figs 2–6.

Table 6 illustrates the statistically significant negative relation between distance between B-lines and each of PaO_2, numbers of B-line, 6MWT, and FVC and PASP. These relations are clarified by (Figs 7–11).

Table 7 clarifies the degree of respiratory restriction by spirometry among cases.

Figure 6

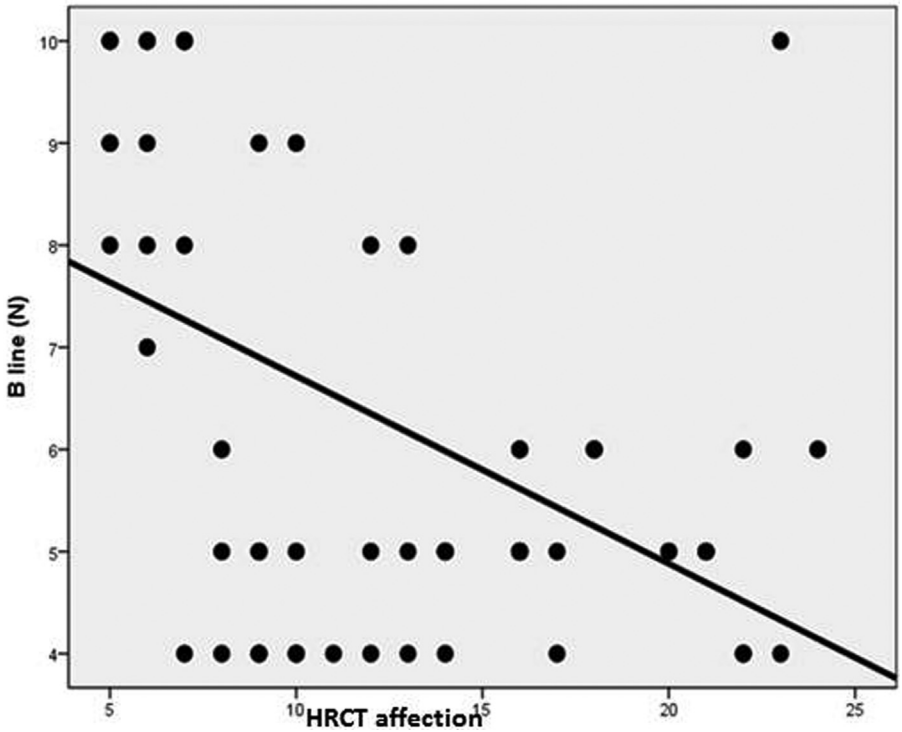

The relation between B-line number and high-resolution computed tomography (HRCT) findings.

Table 8 clarifies the degree of hypoxemia among cases.

Table 9 illustrates the mean and the SD of 6MWT and PASP.

Discussion

The US provides a good view of lung tissue and what above the pleura (e.g. skin & subcutaneous tissue), a real-time imaging of the respiratory movements; it is also low-cost, widely available, and associated with high reproducibility. Owing to these premises, we want to know the possible role of thoracic US in patients with DPLD [8].

All patients presented with dyspnea, where 30% of cases presented with dyspnea only, 36.7% presented with dyspnea and cough, and finally 33.3% of them presented with dyspnea, cough, and wheezing. The studied group showed female predominance, with wide range of age (20–75 years). Most of them were breeding birds and exposed to biomass (80%, n=48) and 90% were nonsmokers.

By HRCT, most of them were diagnosed as having hypersensitivity pneumonitis (50%, n=30), nine (15%) patients had NSIP, 10 (16.6%) patients had IPF, five (8.3%) patients had sarcoidosis, one (1.6%) patient had lymphangioleiomyomatosis, one (1.6%) patient had pleural parenchymal fibroelastosis, and four (6.6%) patients had rheumatoid arthritis.

Table 6 Illustrate correlation of distances between B-lines (mm) and other variables among cases

Variables	Distance between B-line (mm)		
	R	*P* value	Significant
PaO_2	−0.73	<0.001	HS
B-lines (*n*)	−0.69	<0.001	HS
6MWD (m)	−0.53	<0.001	HS
FVC	−0.63	<0.001	HS
PASP	−0.67	<0.001	HS

FVC, forced vital capacity; HS, highly significant; 6MWT, 6-minute walk test; PASP, pulmonary artery systolic pressure.

Pulmonary hypertension (PHT) is one of the complications of DPLD, which affects the exercise tolerance and the survival of these patients [9].

In the current study, there were 53 patients with PHT, and the PASP was ranged from 20 to 120 mmHg, with mean±SD of 47.7±26.3.

These results were in agreement with the study of Zheng *et al.* [10] who found that 134 patients who were diagnosed as having DPLD were complicated with PHT, with mean±SD of 54.67±20.84.

Figure 7

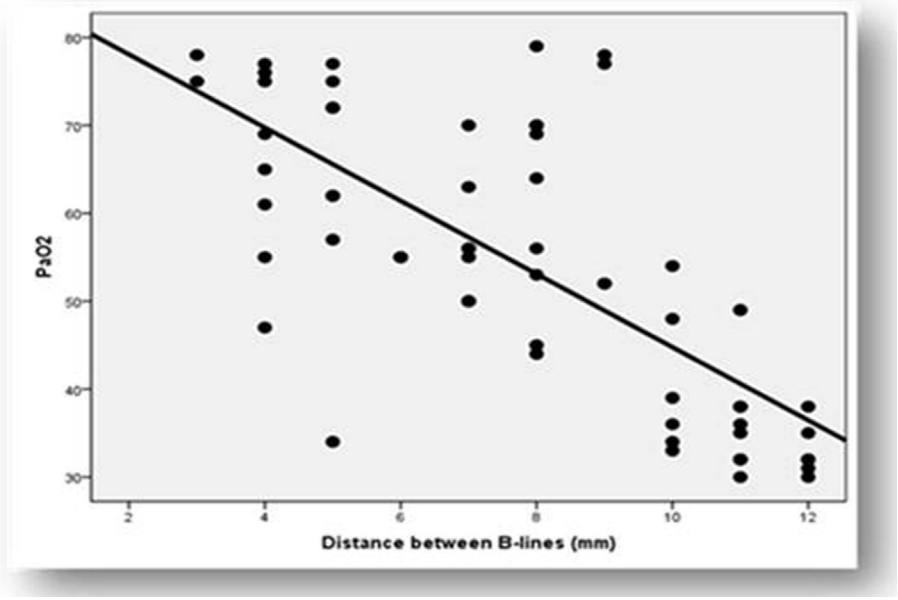

The relation between B-line distance and PaO_2.

Figure 8

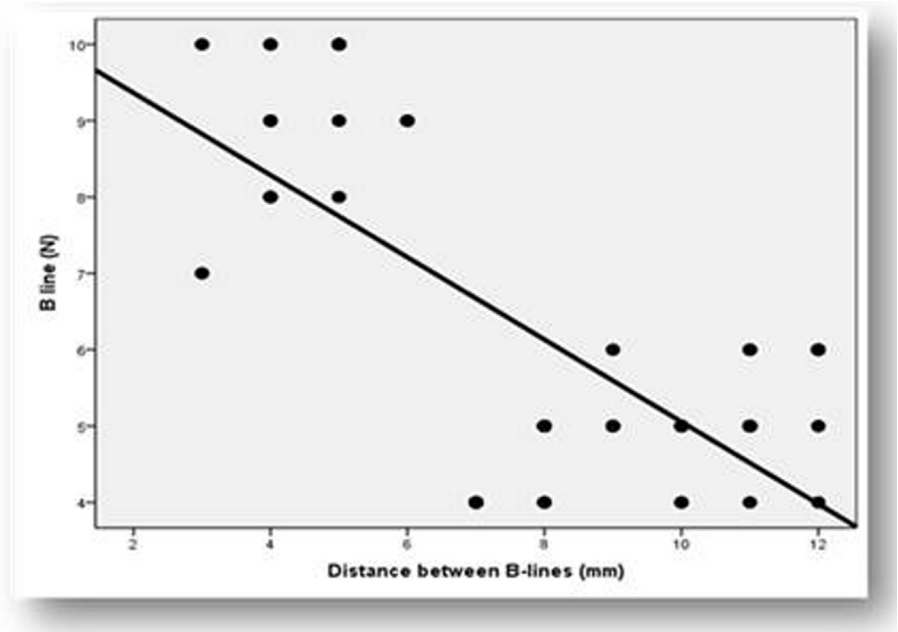

The relation between B-line distance and B-line number.

By using transthoracic ultrasound (TTUS), all patients had diffuse and more than three B-lines bilaterally. The best time to see these B-lines is during the examination, because they were less clarified on the frozen sonograms.

In this study, there are at least four B-lines in each zone. The mean±SD of the number of B-lines was 6.3±2.1. Moreover, the B-line distance ranged from 3 to 12 mm, with mean±SD of 7.8±2.7. This was illustrated in Table 4.

In this study, there is a positive significant relation between B-lines number and PASP, and this is illustrated in Table 5.

This matched with the result of Zheng *et al.* [10] who found a good positive relation between the maximum number of B-lines and PASP.

Moreover, there was a significant positive correlation between the B-lines number and PaO_2, 6MWT, and FVC, which indicates that increase in all these variables

Figure 9

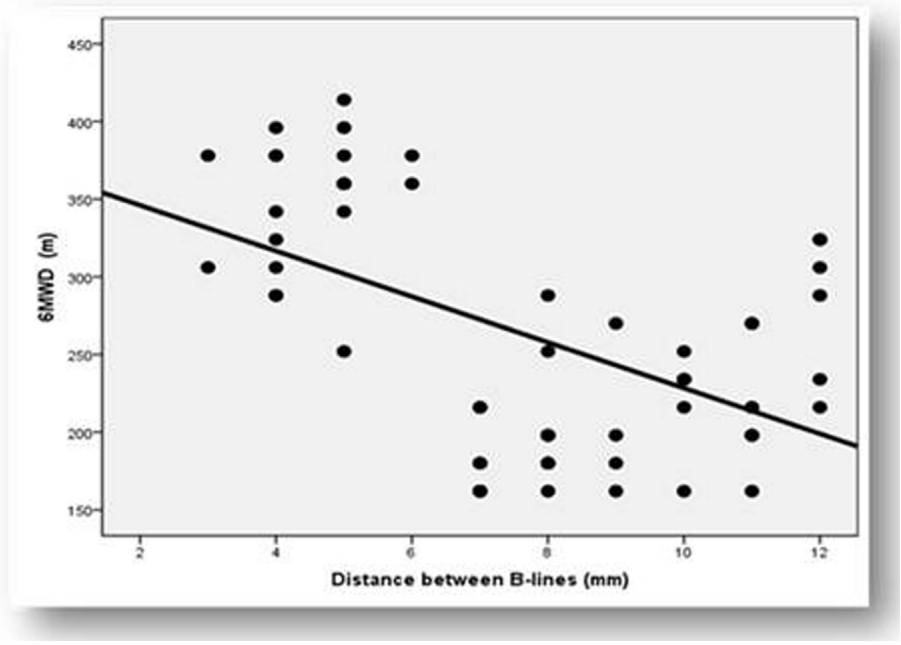

The relation between B-line distance and 6-minute walk test (6MWT).

Figure 10

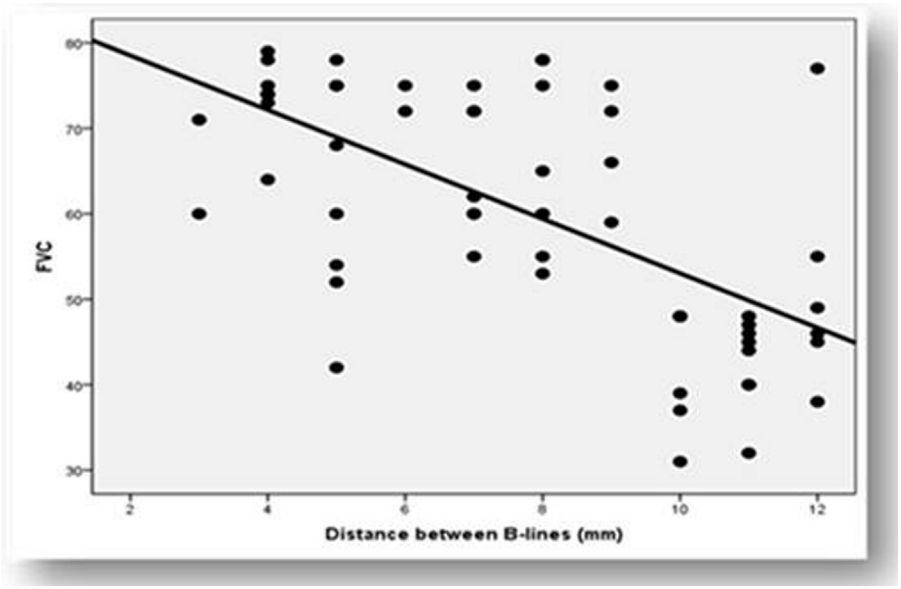

The relation between B-line distance and forced vital capacity (FVC).

will be associated with increasing in numbers of B-lines, and this was illustrated in Table 5. Figure 12 shows US of a patient with mild restriction (numerous B-lines).

This was compatible with the study done by Farag *et al.* [11] who found that B-line number is positively correlated with resting PaO_2 and 6MWT among all patients involved – mild, moderate, and severe groups. However, B-line number is negatively correlated with HRCT findings at which numerous B-lines correlate with ground glass opacity which it always considers as an early stage of the disease, in addition to, with increase in the severity of the disease and appearance of fibrosis in the HRCT, the number of B-line decreases.In the current study, there is a significant negative correlation between B-line distance and PASP as shown in Table 6.

Figure 11

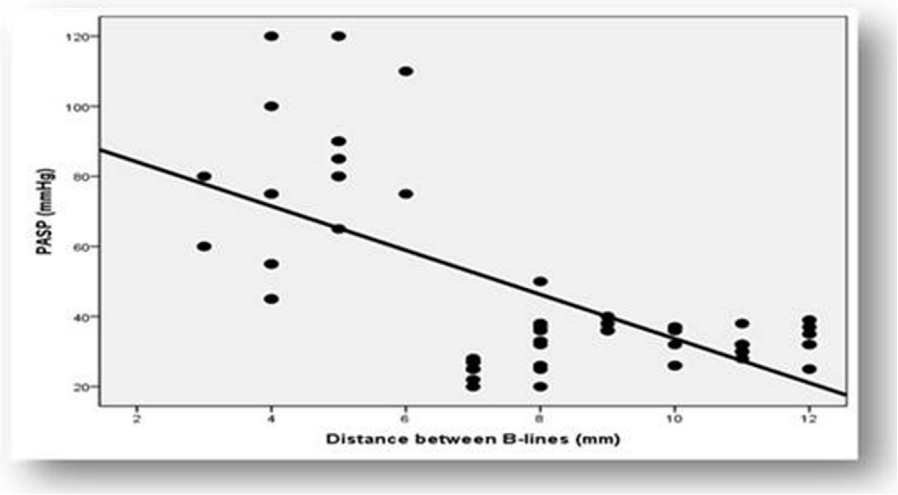

The relation between B-line distance and pulmonary artery systolic pressure (PASP).

Table 7 Illustrate the degree of restriction by spirometery among cases

Normal	0
Obstruction	0
Restriction [*n* (%)]	54 (90)
Mixed [*n* (%)]	6 (10)
Forced vital capacity [*n* (%)]	
Mild restriction	23 (38.3)
Moderate	18 (30)
Severe	19 (31.7)

Table 8 Illustrate the degree of hypoxemia among cases

PaO_2	Cases (*n*=60)
Normal	0
Mild hypoxemia [*n* (%)]	23 (38.3)
Moderate hypoxemia [*n* (%)]	19 (31.6)
Severe hypoxemia [*n* (%)]	18 (30)

Table 9 Illustrate the mean and the SD of six-minute walk test and pulmonary artery systolic pressure

Variables	Cases (*n*=60) (mean±SD)
6MWT (m)	261±77.3
PASP (mmHg)	47.7±26.3

6MWT, 6-minute walk test; PASP, pulmonary artery systolic pressure.

This result was in agreement with the study of Zheng *et al.* [10] who found that the increase in PA systolic pressure was associated with decreased B-line distance, so there was a poor negative relation between the B-line distance and PASP.

Moreover, in the current study, there is a significant negative relation between B-lines distance and FVC %, as shown in Table 6. Figure 13 shows US of a patient with severe restriction (wide distance between B-lines).

This was in agreement with the findings of the study of Agmy *et al.* [12] who found that B-line distance was inversely correlated with FVC%.

Moreover, there is a significant negative relation between B-lines distance and PaO_2, numbers of B-line, and 6MWT, and this was clarified also in Table 6.

This was in agreement with the findings of the study done by Farag *et al.* [11] who found that B-line distance negatively correlated with resting PaO2, number of B lines, and 6MWT among patients with DPLD, and this means that narrow distance between B lines (B3) represents an early alveolar wall affection and a little pulmonary function impairment. On the contrary, the wide distance between B lines (B7) indicates that there are thickened septa and more impairment in the lung function.

According to the pleural line, the linear probe is used for more details.

In this study, the range of the pleural thickness in all studied patients was from 2 to19 mm, with mean±SD of 9.1±5.9, as shown in Table 4.

Most cases had irregular thickened pleural line (71.7%, *n*=43), with mean±SD of 11.6±5.1.

Figure 12

Ultrasound of a patient with mild restriction (numerous B-lines).

Figure 13

Ultrasound of a patient with severe restriction (wide distance between B-lines).

Figure 14 shows irregular pleural line in a patient with IPF.

Limitations of the study

The study has the following limitations:

(1) Small number of patients (60), because the study was conducted for a specific duration (January 2017 to June 2017).
(2) The diffusion capacity of the lung for carbon monoxide and total lung capacity were not measured.
(3) Further investigations for accurate estimation of PASP.

Conclusion

TTUS is a cheap and safe modality that does not need exposure to the ionizing radiation or injection of contrast, as in computed tomography.

It also helps in the diagnosis and detection of disease progression.

Multiple B-lines distributed over the lung surface are an important sonographic sign for the diagnosis of DPLD with thickened and irregular pleural line; the number of B-lines decrease in the advanced stage of the disease with appearance of fibrosis.

Figure 14

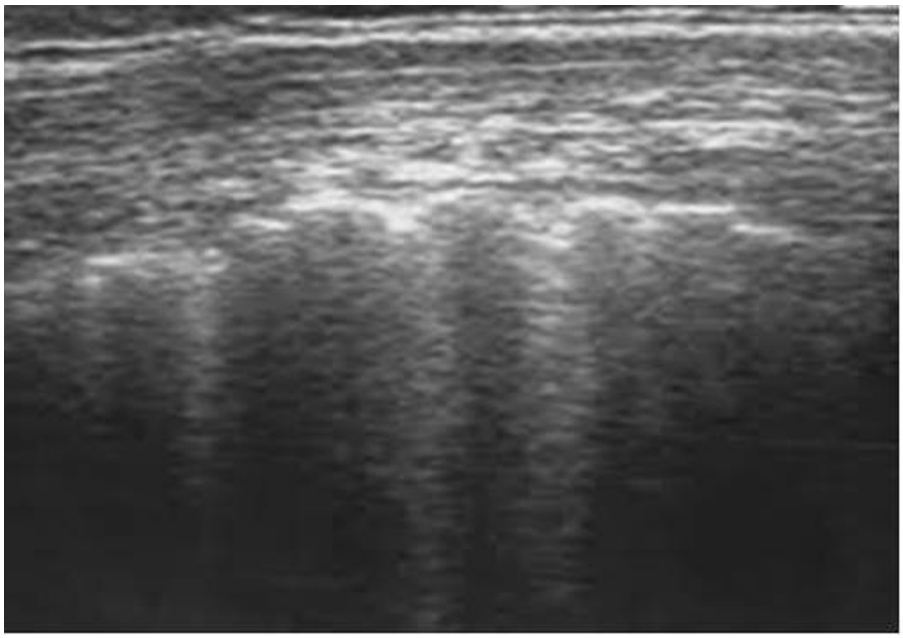

Irregular pleural line in a patient with idiopathic pulmonary fibrosis (IPF).

It may be used in the emergency room when HRCT is not available.

Recommendation

(1) Further studies are recommended to diagnose the underlying type of DPLD by using TTUS to minimize the need of HRCT.
(2) Further studies to evaluate the benefits of TTUS during the assessment of the patient during the course of the treatment and the prognosis of the disease at which we can reduce the frequency of exposure to radiation and decrease the cost for the patient.

Acknowledgements

I would like to express my thanks and gratefulness to Professor Dr Sherif Refaat Abd El-Fatah professor of Chest Diseases and Tuberculosis, Fayoum University, for his close supervision, kind guidance, and his fruitful discussion.

I wish to extend my gratitude to Dr Radwa El-Hefny and Dr Randa Ibrahim Ahmed Assistant Professor of Chest Diseases & Tuberculosis, Fayoum University, for her valuable and excellent remarks and supervision.

Financial support and sponsorship

Nil.

Conflicts of interest

None declared.

References

1 Deconinck B, Verschakelen J, Coolen J, Verbeken E, Verleden G, Wuyts W. Diagnostic workup for diffuse parenchymal lung disease: schematic flowchart, literature review, and pitfalls. *Lung* 2013; **191**:19–25.

2 Koh DM, Burke S, Davies N. Transthoracic US of the chest: clinical uses and applications. *Radiographics* 2002; **22**:e1.

3 Gutierrez M, Salaffi F, Carotti M, Tardella M. Utility of a simplified ultrasound assessment to assess interstitial pulmonary fibrosis in connective tissue disorders – preliminary results. *Arthritis Res Ther* 2011; **13**:R134.

4 Baldi G, Gargani L, Abramo A. Lung water assessment by lung ultrasonography in intensive care: a pilot study. *Intensive Care Med* 2013; **39**:74–84.

5 DexheimerNeto FL, Dalcin PR, Teixeira C, Beltrami FG. Lung ultrasound in critically ill patients: a new diagnostic tool. *J Bras Pneumol* 2012; **38**:246–256.

6 Volpicelli G, Elbarbary M, Blaivas M. International evidence-based recommendations for point of care lung ultrasound. *Intensive Care Med* 2012; **38**:577–591.

7 Bolliger CT, Herth FJF, Mayo PH. Clinical chest ultrasound: from the ICU to the bronchoscopy suite. *Prog Respir Res* 2009; **37**:22–33.

8 Mathis G. Thorax sonography-part I: chest wall and pleura. *Ultrasound Med Biol* 1997; **23**:1131–1139.

9 Zimbarra Cabrita I, Ruísanchez C, Grapsa J. Validation of the isovolumetric relaxation time for the estimation of pulmonary systolic arterial blood pressure in chronic pulmonary hypertension. *Eur Heart J Cardiovasc Imaging* 2013; **14**:51–55.

10 Zheng X, Zheng Q, Zhou J, Yang B. B-lines in assessment of pulmonary hypertension in patients with interstitial lung diseases. *J Ultrasound Med* 2015; **34**:1669–1675.

11 Farag T, Adawy Z, Sakb L, Abdellateefaet H. Transthoracic ultrasonographic features of diffuse parenchymal lung diseases. *Egypt J Bronchol* 2017; **11**:179–187.

12 Agmy G, Sayed S, Said A, Kasem AE. Assessment of transthoracic sonography in patients with interstitial lung diseases. *Egypt J Bronchol* 2016; **10**:105–112.