

Role of ultrasound in airway assessment in the respiratory ICUs

Mona M. Ahmed^a, Iman H.E. Galal^a, Hossam M. Sakr^b, Ashraf A. Gomaa^a, Ahmed M. Osman^b, Marwa H. El-Assal^c

Background Airway evaluation and its management remain an emerging clinical science. Ultrasound (US) provides point-of-care dynamic views of the airway in perioperative, emergency, and critical care settings. Identification of a difficult airway before intubation allows for optimal preparation, equipment selection, and participation of experienced personnel.

Objective The aim of this study was to evaluate the role of US in the assessment of airways and to determine whether US has the potential to serve as an effective, noninvasive method for the diagnosis of tracheomalacia.

Patients and methods A prospective cross-sectional study was carried out on patients admitted at the respiratory ICU. US examination of the airways and diaphragm was performed together with either fiberoptic bronchoscopy (FOB) or dynamic expiratory computed tomography chest. Dynamic expiratory computed tomography chest and FOB were done within 24 h of US examination.

Results A total of 53 patients were included. US could successfully confirm endotracheal tube (ETT) placement in all patients. ETT was endotracheal in 30 (94%) patients, whereas it was esophageal in two (6%) patients. Hyomental distance at a cut-off of up to 4.51 cm was a good predictor of difficult intubation with 100% sensitivity and 87.5% specificity. Subglottic airway transverse diameter was used as a predictor of ETT size. Patients with tracheomalacia by FOB had a significantly longer duration of mechanical ventilation. Lateral pharyngeal wall thickness was used as a predictor of obstructive sleep apnea, a new cut-off point was used at more

than 4.1 cm in the intubated group of patients with 87.5% sensitivity and 95.8% specificity, whereas a cut-off point more than 4.2 cm in the nonintubated patients had 100% sensitivity and 100% specificity. In the intubated group, out of the seven cases diagnosed with tracheomalacia by FOB, five patients were missed by US with 40% sensitivity, whereas in the nonintubated group, the results were significantly better, where only one case was missed by US with 80% sensitivity.

Conclusion US has many advantages for imaging the airway; it is safe, quick, repeatable, portable, widely available, and provides real-time dynamic images relevant for several aspects of management of the airway. Thus, it seems reasonable to consider the routine use of airway US in the ICU.

Egypt J Bronchol 2019 13:672–683

© 2020 Egyptian Journal of Bronchology

Egyptian Journal of Bronchology 2019 13:672–683

Keywords: airway assessment, ICUs, US

Departments of, ^aDiseases, ^bRadiodiagnosis, ^cChest Diseases, Faculty of Medicine, Ain Shams University, Cairo, Egypt

Correspondence to Marwa H. El-Assal, MSc MSc Chest Diseases, Assistant Lecturer of Pulmonary Medicine, Faculty of Medicine, Ain Shams University; Department of Chest Diseases, Faculty of Medicine, Ain Shams University, 38 El-Imam Abou Hanifa St, 7th District, Nasr City, Cairo, Egypt. Tel: +20 111 528 8872; e-mail: dr.marwahusseini89@gmail.com

Received: 16 July 2019 **Accepted:** 17 August 2019

Published: 21 January 2020

Introduction

Airway evaluation and its management remain an emerging clinical science. Current airway management tools are static and do not provide dynamic airway management. Ultrasound (US) provides a dynamic anatomical assessment that is not possible by clinical examination alone [1].

US provides point-of-care dynamic views of the airway in perioperative, emergency, and critical care settings. It is free from ionizing radiation, portable, reproducible, accurate, and can be easily mastered. Because of the superficial location of the larynx, US can provide images of even better resolution than advanced imaging modalities such as computed tomography (CT) and MRI [2].

Recognizing a potentially difficult airway is an important skill; anatomic variations in airway structures cannot be assessed fully before intubation. Identification of a difficult airway before intubation allows for optimal preparation,

equipment selection, and participation of experienced personnel [3].

Tracheobronchomalacia is a disorder that is encountered in both pediatric and adult medicine. It is characterized by a decrease of at least 50% in the cross-sectional area of the tracheobronchial lumen [4].

Although bronchoscopy has been considered the standard diagnostic method, its intrinsic invasiveness and other relative limitations have led to increasing use of expiratory CT as a major tool for the evaluation of suspected cases [5].

The aim of this study was to evaluate the role of US in the assessment of airways and to determine whether US

This is an open access journal, and articles are distributed under the terms of the Creative Commons Attribution-NonCommercial-ShareAlike 4.0 License, which allows others to remix, tweak, and build upon the work non-commercially, as long as appropriate credit is given and the new creations are licensed under the identical terms.

has the potential to serve as an effective, noninvasive method for the diagnosis of tracheomalacia.

Patients and methods

This prospective cross-sectional study was carried out on 53 consecutive patients either admitted to the respiratory ICUs of Ain Shams University Hospitals or undergoing fiberoptic bronchoscopy (FOB) in the period between March 2017 and September 2018. The study design was approved by the institutional research ethics committee, and a verbal informed consent was obtained from the patients or their relatives.

Patients were excluded from this study if they were noncooperative and failed to respond to breathing instructions during CT of the chest, patients with tracheal stents at the same level of analysis that would prevent the ability to determine the degree of airway collapse, patients receiving deep sedation or muscle relaxants that may compromise airway function or spontaneous ventilation, patients with known tracheomalacia, and patients with extensive surgical emphysema, neck trauma, cervical, or spinal cord injuries that require them to wear cervical collars.

All the patients included were subjected to a complete assessment of history, which was obtained from the patient and/or his relatives, including smoking history, comorbidities, and risk factors for tracheomalacia, thorough clinical examination, arterial blood gases, chest radiograph (anteroposterior in intubated and posteroanterior in nonintubated patients), echocardiography, US examination of the airways and diaphragm using the Mindray M7 ultrasound machine (Mindray Bio-Medical Electronics Co., Shenzhen, China), dynamic expiratory CT (128-row MDCT scanner GE 128, Optima 660; 128-row MDCT scanner GE Health Care 128, Optima 660; Chicago, USA) for nonintubated ICU patients, and FOB [HD PENTAX 3.2 Medical 70 K Series (EB-1970TK) video bronchoscope] for intubated ICU patients and for nonintubated patients undergoing bronchoscopy. Dynamic expiratory CT and FOB were performed within 24 h of US examination. FOB was performed using minimal to moderate sedation (intravenous midazolam with maximum dose of 0.07 mg/kg) in some patients, allowing spontaneous breathing, and positive end expiratory pressure was not applied during periods of assessment of tracheomalacia [6]. For patients undergoing FOB, tracheomalacia was detected when bronchoscopic visualization of at least 50% expiratory reduction of the airway lumen occurred [4]. The sonographer was

blinded to the results of both dynamic expiratory CT and FOB.

Protocol of ultrasound examination

The sonographic examination was performed by the respiratory ICU physician under the supervision of a certified Radiology consultant with experience in sonography of the head and neck.

Patients were placed in a supine position with their head extended and neck flexed (the sniffing position) [7]. The airway was imaged systemically along its course from the floor of the mouth to the level of the suprasternal notch using both linear and curvilinear transducers.

The ultrasound transducer was oriented with respect to the patient in one of three ways:

- (1) Longitudinally in the midline (the sagittal view).
- (2) Longitudinally 2 cm lateral to the midline (the parasagittal view).
- (3) Transversely across the anterior surface of the neck (the transverse view) [8].

Clinical applications of sonographic examination of the patients under study

- (1) Predicting difficult intubation:
 - (a) Hyomental distance:
 - (a) The distance between the upper border of the hyoid bone and the lower border of the mentum [9]
 - (b) Pretracheal soft tissue at the level of the vocal cords and the suprasternal notch:
 - (a) By measuring the distance from the skin to the anterior aspect of the trachea at the level of the vocal cords and the suprasternal notch [10].
- (2) Confirmation of endotracheal tube (ETT) placement:
 - (a) Confirmation of ETT placement was performed by US either directly or indirectly together with chest auscultation.
 - (b) Confirmation of endotracheal placement:
 - (c) Either by direct performance of a real-time scan of the anterior neck by placing the transducer just above the suprasternal notch (two hyperechoic lines in a double-tract or a double-lumen sign) [8] or by indirectly looking for ventilation at the pleura or the diaphragm level [8].
 - (d) Esophageal intubation:
 - (e) Hyperechoic dark line with a distal dark area (shadowing) appearing on one side of and deep to the trachea [11].

- (f) Endobronchial intubation:
 (g) Lung sliding on one side and lung pulse on the other side [12].
- (3) Prediction of the appropriate diameter of the ET tube:
 By measuring the diameter of the subglottic airway at the lower edge of the cricoid cartilage.
 US can measure the actual subglottic diameter, which helps in deciding the appropriate size of the ETT [13].
 The 'correct' tracheal tube size was defined as that size that allowed an audible air leak around the tube at an inspiratory airway pressure of 15–30 cmH₂O, with the head and neck in a neutral position [14].
- (4) Prediction of successful weaning:
 (a) By measuring diaphragmatic excursion (displacement of diaphragm during inspiration).
 (b) Assessment of obstructive sleep apnea (OSA):
 (c) By measuring lateral pharyngeal wall thickness
 (d) Detection of tracheomalacia:
 (e) By measuring the anteroposterior diameter of the trachea during inspiration and expiration at the level of the suprasternal notch.

Statistical analysis

The collected data were revised, coded, tabulated, and entered into a PC using the statistical package for the social sciences (IBM SPSS) version 20.0. (SPSS Inc., Chicago, Illinois, USA). Data were presented, and a suitable analysis was carried out according to the type of data obtained for each parameter. The quantitative variables were described as mean, SD, and range. The qualitative variables were described as number and percentage. An unpaired *t*-test was used to compare the quantitative variables in parametric data ($SD < 50\%$ mean). A receiver operator characteristic curve was used to determine the best cut-off value and the validity of certain variables. A *P* value higher than 0.05 was considered insignificant, a *P* value less than 0.05 was considered significant, and a *P* value less than 0.01 was considered highly significant.

Results

A total of 53 adult patients were enrolled in the study. Patients were divided into two groups: 32 intubated and 21 nonintubated patients. The baseline characteristics of all the patients included are presented in Table 1.

US assessment of the airway was performed before and during intubation. Different sonographic findings including predictors of OSA, difficult intubation, and successful weaning are presented in Tables 2 and 3.

Table 1 Baseline demographic and clinical characteristics of the patients included

	N=53
Age	
Mean±SD	57.25±15.41
Range	17–88
Sex [n (%)]	
Male	37 (69.8)
Female	16 (30.2)
Smoking status [n (%)]	
Smoker	15 (28.3)
Nonsmoker	28 (52.8)
Ex-smoker	9 (17.0)
Passive smoker	1 (1.9)
Pack years	
Mean±SD	42.92±21.62
Range	15–100
Weight (kg)	
Mean±SD	73.10±12.73
Range	55–100
Height (cm)	
Mean±SD	168.29±7.32
Range	150–180
BMI (kg/m ²)	
Mean±SD	26.24±5.73
Range	19–39.5
Comorbidities [n (%)]	
Hypertension	23 (43.4)
Diabetes mellitus	20 (37.7)
Chronic kidney disease	3 (9.4)
Ischemic heart disease	2 (6.3)
Heart failure	4 (7.5)
Old stroke	1 (3.1)
Neuromuscular disease	1 (3.1)
Sinusitis	3 (5.7)
Diagnosis [n (%)]	
Pneumonia	16 (30.2)
Acute exacerbation of ILD	1 (1.9)
Lung collapse	6 (11.3)
Decompensated heart failure	4 (7.5)
Acute exacerbation of COPD	19 (35.8)
Lung mass	4 (7.5)
Pleural effusion	1 (1.9)

COPD, chronic obstructive pulmonary disease; ILD, interstitial lung disease.

US could successfully confirm ETT placement in all patients either by direct performance of real-time scans of the anterior neck region during intubation or by indirectly looking for ventilation at the pleura or the diaphragmatic level. ETT was endotracheal in 30 (94%) patients, whereas it was esophageal in two (6%) patients as shown in Fig. 1.

Prolonged mechanical ventilation was the most frequent risk factor for tracheomalacia, which was present in 29 (54.7%) patients.

Table 2 Sonographic findings among the intubated group of patients

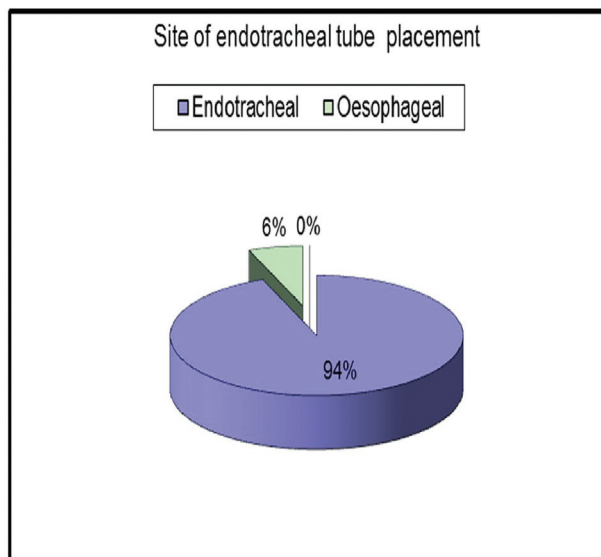
Variables	Mean±SD (range)
Predictor of OSA (LPW thickness) (cm)	3.88±0.62 (3.2–5)
Predictors of difficult intubation (cm)	
Hyomental distance	4.83±0.55 (3.91–5.9)
Distance from the anterior aspect of the trachea to the skin at the vocal cords	0.74±0.29 (0.33–1.94)
Distance from the anterior aspect of the trachea to the skin at the suprasternal notch	0.90±0.26 (0.6–1.82)
Anteroposterior diameter of the trachea (cm)	
During inspiration	2.15±0.35 (1.7–2.8)
During expiration	1.88±0.35 (1.2–2.65)
Prediction of the appropriate diameter of ETT (subglottic airway transverse diameter) (cm)	1.94±0.32 (1.13–2.35)
Predictor of successful weaning (diaphragmatic excursion) (cm)	0.94±0.43 (0.3–1.9)

ETT, endotracheal tube; LPW, lateral pharyngeal wall; OSA, obstructive sleep apnea.

Table 3 Sonographic findings among the nonintubated group

Variables	Mean±SD (range)
Predictor of OSA (LPW thickness) (cm)	3.81±0.53 (3.2–5)
Anteroposterior diameter of trachea (cm)	
During inspiration	1.85±0.41 (1.26–2.63)
During expiration	1.59±0.36 (1.01–2.3)

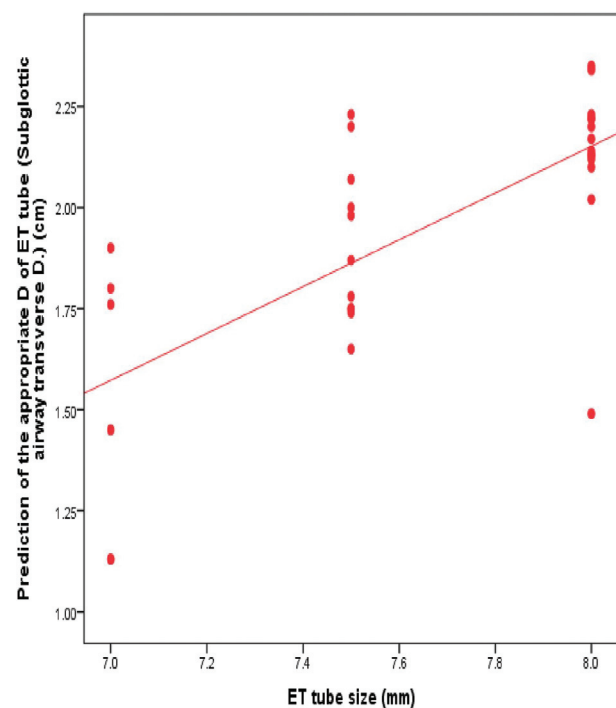
LPW, lateral pharyngeal wall; OSA, obstructive sleep apnea.

Figure 1

Site of endotracheal tube placement.

There was a highly statistically significant positive correlation between subglottic airway diameter and ETT diameter as presented in Figs 2–4.

In terms of the sonographic predictors of difficult intubation, there was no significant correlation between difficult intubation and pretracheal soft tissue at the level of the vocal cords or the suprasternal notch. In contrast, hyomental distance was a good predictor of difficult intubation as shown in Table 4.

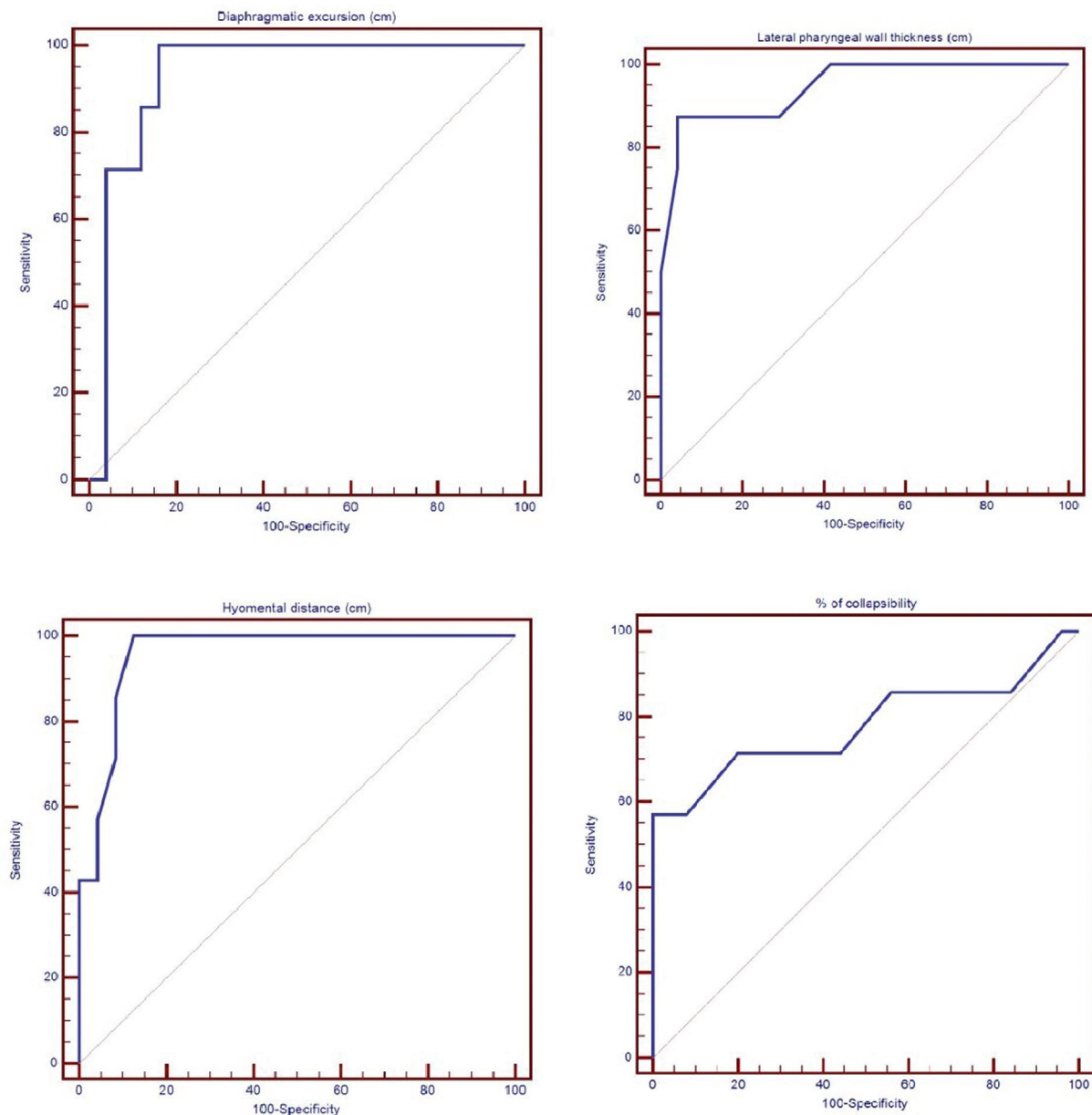
Figure 2

Scattered plot for subglottic airway transverse diameter.

Lateral pharyngeal wall (LPW) thickness was used as a predictor of OSA as shown in Tables 5 and 6, where LPW thickness was greater among the patients with OSA symptoms in both the intubated and non-intubated groups.

New cut-off points were used for both hyomental distance and LPW thickness as reported in Tables 7 and 8. Hyomental distance at a cut-off of up to 4.51 cm was a good predictor of difficult intubation with 100% sensitivity and 87.5% specificity. LPW thickness at a cut-off point at more than 4.1 cm in the intubated group of patients was a good predictor of OSA with 87.5% sensitivity and 95.8% specificity, whereas a cut-off point more than 4.2 cm in the nonintubated patients had 100% sensitivity and 100% specificity.

Figure 3



Receiver operator characteristic for different sonographic parameters among the intubated patients.

In terms of the diagnosis of tracheomalacia by US, more than 21 and 20% collapsibility of the tracheal wall in the intubated and nonintubated groups, respectively, was found to be equivalent to 50% collapsibility of the tracheal wall by either FOB or dynamic expiratory CT chest as shown in Tables 7 and 8.

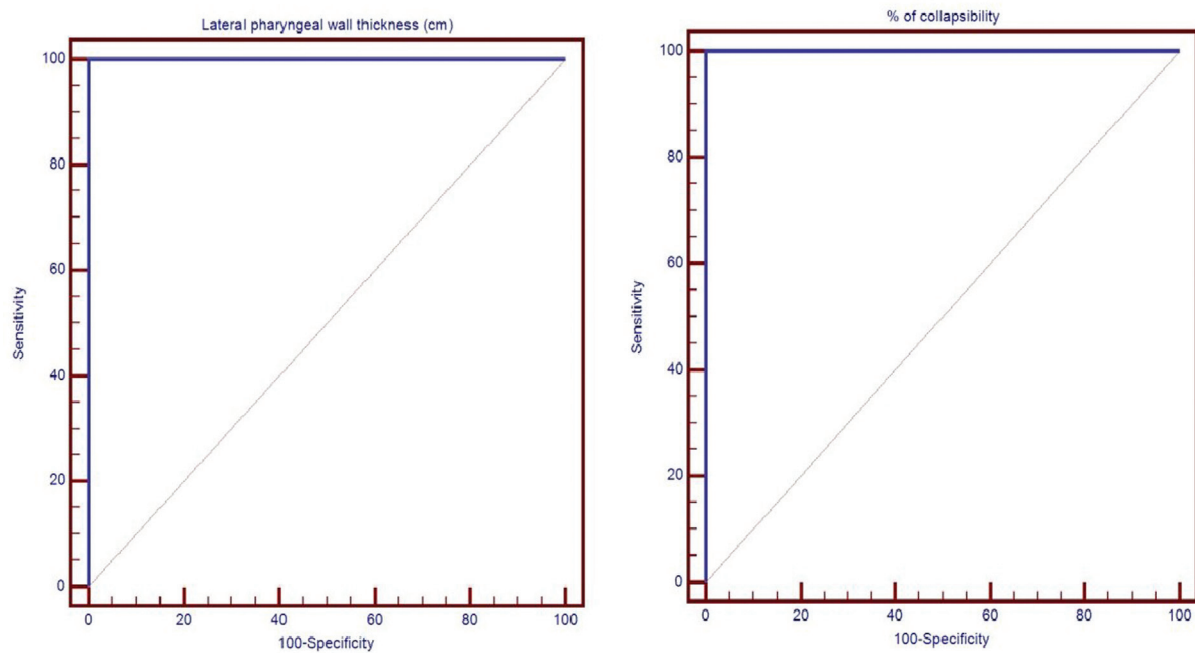
In terms of the risk factors for tracheomalacia, only chronic obstructive pulmonary disease (COPD) significantly increased the risk of tracheomalacia by FOB as reported in Table 9.

Patients with tracheomalacia by FOB had a significantly longer duration of mechanical ventilation as reported in Table 10.

Among the 32 intubated patients, tracheomalacia was diagnosed by FOB only in seven (21.9%) patients, which is shown in Fig. 5. In the intubated group, out of the seven cases diagnosed with tracheomalacia by FOB, five patients were missed by US with 40% sensitivity, whereas in the nonintubated group, the results were significantly better, where one case only was missed by US with 80% sensitivity.

Patients diagnosed with tracheomalacia by FOB showed a highly statistically significant increase in percentage of collapsibility of US compared with those without tracheomalacia in both groups as reported in Table 11.

Figure 4



Receiver operator characteristic for different sonographic parameters among the nonintubated patients.

Table 4 Comparison between patients with or without difficult intubation in sonographic predictors of difficult intubation

	Difficult intubation		Test value	P value	Significance
	Yes	No			
Distance from the anterior aspect of the trachea to the skin at the vocal cords (cm)					
Mean±SD	0.87±0.47	0.71±0.22	1.29	0.207	NS
Range	0.65–1.94	0.33–1.22			
Distance from the anterior aspect of the trachea to the skin at the suprasternal notch (cm)					
Mean±SD	0.96±0.34	0.88±0.25	0.626	0.536	NS
Range	0.68–1.68	0.6–1.82			
Hyomental distance (cm)					
Mean±SD	4.18±0.25	5.02±0.46	4.566	<0.001	HS
Range	3.91–4.51	4.2–5.9			

HS, highly significant.

Table 5 Comparison between symptoms of obstructive sleep apnea in terms of lateral pharyngeal wall thickness

LPW thickness (cm)	Symptoms of OSA		Test value	P value	Significance
	Yes (N=3)	No (N=18)			
Nonintubated group					
Mean±SD	4.87±0.12	3.64±0.33	6.310	0.000	HS
Range	4.8–5	3.2–4.2			
Intubated					
Mean±SD	4.73±0.43	3.60±0.37	7.181	<0.001	HS
Range	3.7–5	3.2–4.8			

HS, highly significant; LPW, lateral pharyngeal wall; OSA, obstructive sleep apnea.

Table 6 Comparison between diaphragmatic excursion among different weaning states

Diaphragmatic excursion (cm)	Weanable		Test value ^a	P value	Significance
	Yes	No			
Mean±SD	1.44±0.23	0.81±0.43	4.372	<0.001	HS
Range	1.14–1.83	0.30–1.9			

P>0.05, NS; P<0.05, significant; P<0.01, highly significant (HS). ^aIndependent t-test.

Table 7 Predictive power of different sonographic parameters among the intubated group of patients

	Cut-off point	Area under the curve	Sensitivity	Specificity	Positive predictive value	Negative predictive value
Diaphragmatic excursion	>1.07	0.931	100.00	84.00	63.6	100.0
Lateral pharyngeal wall thickness	>4.1	0.945	87.5	95.83	87.5	95.8
Hyomental distance	≤4.51	0.958	100.00	87.50	70.0	100.0
Percentage of collapsibility of tracheal wall by ultrasound	>21	0.78	57.14	100.00	100.0	89.3

Table 8 Predictive power of different sonographic parameters among the nonintubated group

	Cut off point	AUC	Sensitivity	Specificity	PPV	NPV
LPW thickness (cm)	>4.2	1.000	100	100	100	100
Predictive power of percentage of collapsibility by US	>20	1.000	100.00	100.00	100.0	100.0

AUC, area under curve; LPW, lateral pharyngeal wall; NPV, negative predictive value; PPV, positive predictive value; US, ultrasound.

Among the nonintubated group of patients, the percentage of collapsibility of the tracheal wall was significantly higher among patients diagnosed with tracheomalacia as shown in Table 12.

Among the nonintubated group of patients, US could diagnose all cases of tracheomalacia confirmed by dynamic expiratory CT, but missed one case against which was diagnosed by FOB as shown in Table 13.

Discussion

US has recently emerged as a novel, simple, portable, and noninvasive tool that is useful for airway assessment and management [15].

Safe airway management is the prime goal of anesthesiologists. US is a recent addition to the anesthesiologist armamentarium and is gaining importance in every skill related to the field. Use of point-of-care US for the real-time dynamic imaging of airway structures has many advantages. The sonography of the airway structures may help the anesthesiologist to assess the size of the airway, predict difficulty in intubation, and detect any airway-related pathologies [1].

Acquired diffuse tracheobronchial collapse is observed with COPD and is believed to represent the chronic

inflammatory response of larger airways to tobacco smoke [16].

This study showed that the most common risk factor for tracheomalacia was prolonged mechanical ventilation; this can be attributed to the high pressures in the ETT cuff that may cause localized ischemic injury to the tracheal wall. Prolonged mechanical ventilation was present in 29 (54.7%) patients, followed by COPD, which was present in 20 (37.7%) patients.

These results were consistent with the results of Kandaswamy *et al.* [17], where the mean ICU stay on mechanical ventilation was significantly longer in those patients with tracheomalacia compared with the control group. Similarly, in the previous work of Ernst *et al.* [18] and Loring *et al.* [19], 57 and 40% of patients with tracheobronchomalacia had COPD, respectively.

This study is in agreement with the literature, where Carden *et al.* [4] identified endotracheal intubation as the most common cause of secondary tracheomalacia in adults. Other factors included recurrent intubation, severe tracheobronchitis, and cigarette smoking.

This study showed that the most common presenting symptom among the patients studied was dyspnea, which was found in all patients, followed by productive cough, which was found in 23 patients. These results are also similar to those of Adnan *et al.* [20], who reported dyspnea and cough as the presenting symptoms in nine out of 10 patients.

In this study, tracheomalacia was found more repeatedly among patients diagnosed with COPD exacerbation; this is in agreement with the previous study, where Kerolous and Ikladios [21] suggested an association between tracheomalacia and recurrent exacerbations of COPD.

'Difficult airway' constitutes a problem in establishing or maintaining gas exchange through a mask, an artificial airway, or both. Intubation is considered difficult if more than three attempts are necessary or if conventional laryngoscopy requires more than

Table 9 Comparison between the findings of tracheomalacia by fiberoptic bronchoscopy in terms of the risk factors for tracheomalacia

	Tracheomalacia by FOB [n (%)]		Test value ^a	P value	Significance
	Yes (N=7)	No (N=25)			
Previous mechanical ventilation					
Yes	2 (28.6)	5 (20.0)	0.235	0.628	NS
No	5 (71.4)	20 (80.0)			
Inhaled corticosteroids					
Yes	0	3 (12.0)	0.927	0.336	NS
No	7 (100.0)	22 (88.0)			
COPD					
Yes	5 (71.4)	4 (16.0)	8.312	0.004	HS
No	2 (28.6)	21 (84.0)			
Tracheostomy					
Yes	1 (14.3)	1 (4.0)	0.987	0.320	NS
No	6 (85.7)	24 (96.0)			
Recurrent upper respiratory tract infections					
Yes	0	6 (24.0)	2.068	0.150	NS
No	7 (100.0)	19 (76.0)			
Trauma					
Yes	1 (14.3)	0	3.687	0.055	NS
No	6 (85.7)	25 (100.0)			

COPD, chronic obstructive pulmonary disease; FOB, fiberoptic bronchoscopy; HS, highly significant. ^a χ^2 -Test.

Table 10 Comparison between days of mechanical ventilation and tracheomalacia

Days of Mechanical ventilation	Tracheomalacia by FOB		Test value	P value	Significance
	Yes	No			
Mean±SD	8.14±5.84	4.44±3.22	2.228	0.034	S
Range	3–20	1–16			

FOB, fiberoptic bronchoscopy; S, significant.

10 min. It represents a complex interaction between patient factors and the skills of the practitioner [22].

Interestingly, US provides a dynamic anatomical airway assessment that is not possible by clinical examination alone.

Recently, sonographic parameters such as hyomental distance and pretracheal soft tissue thickness at the level of the vocal cords and suprasternal notch have been suggested as predictors of difficult intubation [10].

Yet, in this study, there was no significant correlation between difficult intubation and pretracheal soft tissue at the level of the vocal cords as well as the suprasternal notch, which is not in agreement with the previous work published by Ezri *et al.* [10], Wu *et al.* [23] and Ezri *et al.* [10] found that difficult laryngoscopy patients had much more soft tissue at the level of the vocal cords and the suprasternal notch, and they concluded that quantification of neck soft tissue at the level of the vocal cords and the suprasternal notch appears to be the best predictor of a difficult

laryngoscopy. One reason for the different results between our study and that of Ezri *et al.* [10] may be related to the different BMI of the populations studied, where these patients fell in the morbidly obese range. Also, Adhikari *et al.* [24] found that the sonographic measurements of the anterior neck soft tissue at the level of the hyoid bone were much greater in the difficult laryngoscopy group compared with the easy laryngoscopy group.

Komatsu *et al.* [25] used US to quantify the neck soft tissue from the skin to the anterior aspect of the trachea at the level of the vocal cords in 64 obese patients; they reported that difficult laryngoscopy patients had less soft pretracheal tissue than the easy laryngoscopy patients. Conversely, they concluded that pretracheal soft tissue thickness at the level of the vocal cords did not predict difficult intubation in obese patients.

In this study, the hyomental distance, which is the distance between the hyoid bone and the mandibular mentum, was used as a predictor of difficult intubation. Currently, there is no standard cut-off value for the hyomental distance. It was found to differ significantly

between the easy intubation and difficult intubation patients. Moreover, a cut-off value less than 4.51 cm was considered to be a good predictor of difficult intubation with 100% sensitivity and 87.5% specificity.

This is somewhat in agreement with Kalezic *et al.* [26], who reported that hyomental distance can be used as a predictor of difficult intubation at a cut-off value less than 5.3 cm, with 76% sensitivity and 62% specificity. Similarly, Abraham *et al.* [27], who investigated 137

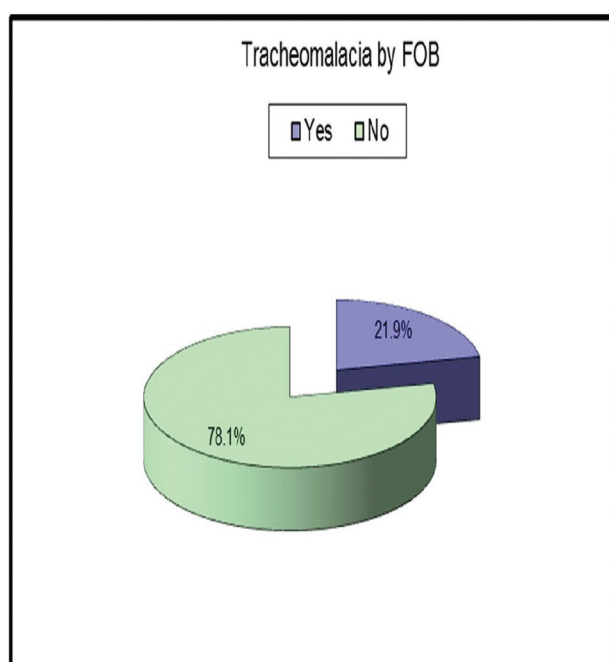
patients to predict the difficulty in intubation preoperatively using US, found the hyomental distance to be a valid criterion in predicting difficult intubation with 90% sensitivity and 88% specificity.

Several methods are utilized to confirm proper ETT placement, but these methods can be unreliable or unavailable in certain settings [28]. For example, quantitative waveform capnography that was recommended in the 2010 ACLS guidelines as the most reliable method of detection may fail in low-flow states [29,30]. Recently, real-time laryngeotracheal US to confirm correct ETT was shown to be very useful in cadaveric models and during emergency intubation [31].

In this study, US could successfully confirm ETT placement in 100% of cases either by direct performance of real-time scans of the anterior neck region during intubation or by indirectly looking for ventilation at the pleura or the diaphragmatic level, where the tube was endotracheal in 30 (94%) cases and esophageal in two (6%) cases.

Several previous studies have evaluated the use of US to confirm correct ETT placement. The systematic review by Gottlieb *et al.* [32] identified 17 studies ($n=1595$ patients) in which transtracheal US had 98.7% sensitivity and 97.1% specificity. Similarly, Chun *et al.* [28] reported that US could detect ETT placement in 100% of cases, where the tube was endotracheal in 13 patients and endobronchial in two trauma patients. Also, Chou *et al.* [33], who enrolled 89 patients in their study to evaluate the

Figure 5



Tracheomalacia confirmed by fiberoptic bronchoscopy among the intubated patients.

Table 11 Comparison between tracheomalacia by ultrasound and fiberoptic bronchoscopy

Percentage of collapsibility by US	Tracheomalacia by FOB		Test value	P value	Significance
	Yes	No			
Intubated group					
Mean±SD	23.57±14.86	12.26±4.40	3.423	0.002	HS
Range	7–53	3.5–21			
Nonintubated group					
Mean±SD	30.83±8.89	10.33±2.08	7.006	<0.001	HS
Range	24.5–41	7–13.5			

FOB, fiberoptic bronchoscopy; HS, highly significant; US, ultrasound.

Table 12 Comparison between percentage of collapsibility by ultrasound and tracheomalacia by dynamic expiratory computed tomography

Percentage of collapsibility	Tracheomalacia by dynamic expiratory CT		Test value	P value	Significance
	Yes (N=2)	No (N=7)			
Mean±SD	27±7.07	12.14±4.53	3.729	0.007	HS
Range	22–32	7–20			

CT, computed tomography; HS, highly significant.

Table 13 Comparison between ultrasound, fiberoptic bronchoscopy, and dynamic expiratory computed tomography in the diagnosis of tracheomalacia among the nonintubated patients

Tracheomalacia by US			Test value	P value	Significance
Yes	No				
Tracheomalacia by FOB					
Yes	2 (100.0)	1 (10.0)	7.200	0.007	HS
No	0	9 (90.0)			
Tracheomalacia by dynamic expiratory CT					
Yes	2 (100.0)	0	9.000	0.003	HS
No	0	7 (100.0)			

CT, computed tomography; FOB, fiberoptic bronchoscopy; HS, highly significant; US, ultrasound.

accuracy of tracheal US for assessing the ETT position during cardiopulmonary resuscitation, found that seven out of 89 patients had esophageal intubations with 100% sensitivity and 85.7% specificity.

Chou *et al.* [34] carried out a systematic review and meta-analysis to summarize evidence on the diagnostic value of US for the assessment of ETT placement in adult patients from a total of 12 eligible studies involving adult patients and cadaveric models identified from 1488 references, for the detection of esophageal intubation; the pooled sensitivity was 95% and the specificity was 95%.

The smallest diameter of the normal upper airway is located at the level of the cricoid cartilage. This diameter governs the selection of the ETT size, as increased tube diameter may damage the tracheal mucosa, leading to postextubation stridor or subglottic stenosis. Unfortunately, selection of ETT size on the basis of height, weight, or age does not reliably lead to the proper tube size. The knowledge of airway diameter, especially using a bedside noninvasive tool, could therefore be useful in anesthesia and intensive care [35]. US can measure the actual subglottic diameter, which helps in deciding the appropriate size of the ETT [13].

In this study, US was found to be useful to assess the subglottic diameter in the clinical setting. There was a strong positive correlation between subglottic airway diameter and ETT diameter.

This is in agreement with Lakhal *et al.* [36], who studied 19 healthy volunteers with a mean age of 27 years to compare between the transverse diameter of the cricoid lumen by US and MRI. They concluded that US is a reliable tool to assess the subglottic upper airway diameter.

In pediatric patients, subglottic upper airway diameter measured by US was found to be a good predictor of correct cuffed and uncuffed ETT sizes. Shibasaki *et al.* [35] found that subglottic airway diameter was correlated highly with outer ETT diameter deemed optimal on clinical grounds.

The good agreement of the US method to measure the smallest subglottic diameter found in our study was not in agreement with the findings of Husein *et al.* [37]; they found that US could not provide accurate measurements of the subglottic diameters. US was found to provide measurements that were significantly smaller. This disagreement may be explained by the different age groups of both studies; the study of Husein *et al.* [37] obtained this finding in a younger group of patients (1–20 years).

OSA is a common clinical disorder characterized by paroxysmal and repetitive episodes of partial or complete airway obstruction that occur during sleep. The gold standard for the diagnosis of OSA, polysomnography, cannot anatomically localize the level of airway obstruction [38].

In this study, LPW thickness was presented as a predictor of OSA, where LPW thickness was greater among patients with symptoms suggestive of OSA in both the intubated and nonintubated groups.

The previous literature did not report a cut-off point for the LPW thickness. Thus, in this study, a new cut-off point was set at more than 4.1 cm in the intubated group of patients with 87.5% sensitivity and 95.8% specificity, whereas a cut-off point more than 4.2 cm in the nonintubated patients had 100% sensitivity and 100% specificity.

These data were in agreement with the study of Liu *et al.* [39]; in which patients with significant OSA had greater LPW thickness than those without significant OSA. Extubation outcome is in direct relation to the respiratory muscle endurance, where diaphragmatic function plays a pivotal role [40]. In this study, there was significantly larger displacement of the liver and spleen in patients with successful extubation than patients in whom extubation failed. Diaphragmatic excursion at a cut-off value of 1.07 cm was a good predictor of successful weaning with 100% sensitivity and 84% specificity.

These data are in agreement with the previous work of Jung-Rern *et al.* [41]; Osman *et al.* [42] stated that diaphragmatic excursion at a cut-off value 1 cm

correlated well with successful weaning with 88.9% sensitivity and 100% specificity. Jung-Rern *et al.* [41] carried out their study on 55 patients scheduled to be extubated; at a cut-off value of diaphragmatic excursion of 1.1 cm, the sensitivity and specificity were 84.4 and 82.6%, respectively.

Kim *et al.* [43] carried out a prospective observational study on 88 consecutive patients who required mechanical ventilation over 48 h and fulfilled the criteria for spontaneous breathing trial; it was found that decreased diaphragmatic excursion on M-mode US predicted weaning failure equivalent to a rapid shallow breathing index during spontaneous breath trials, at a cut-off of 1.4 cm for diaphragm excursion, and less excursion was consistent with a greater chance of weaning failure.

Similarly, Saeed *et al.* [44] carried out a prospective observational study on 32 patients with COPD to evaluate the role of diaphragmatic excursion as a predictor of successful weaning in different modes of mechanical ventilation; diaphragmatic excursion was higher in the weaned group with different cut-off values according to the selected ventilator mode.

Tracheomalacia is a condition defined by excessive expiratory collapse of the trachea because of weakness of the airway walls and/or supportive cartilage [45]. In this study, US was performed to detect tracheomalacia in comparison with either FOB or dynamic expiratory CT. The percentage of collapsibility of the anteroposterior diameter of the tracheal wall was found to be a good predictor of tracheomalacia and corresponds to at least 50% expiratory reduction of its lumen with 57% sensitivity and 100% specificity in the intubated patients and 100% sensitivity and 100% specificity in the nonintubated patients.

In the intubated group, out of the seven cases diagnosed with tracheomalacia by FOB, five patients were missed by US with 40% sensitivity, whereas in the nonintubated group, the results were significantly better; only one case was missed by US with 80% sensitivity. These data cannot be generalized owing to the limited number of patients diagnosed with tracheomalacia. Moreover, the fact that the posterior tracheal wall is difficult to visualize by US because of the artifacts created by the intraluminal air column could be a possible explanation.

Finally, it is worth mentioning that experienced airway sonographers are well aware that differences in probe pressure applied while scanning the neck can significantly alter measurements of these superficial neck structures. It was thus emphasized that the

sonographer places the probe against the neck with the least pressure needed to maintain skin contact.

Airways are superficial structures and filled with air; this does not allow proper transmission of the US signals through the air-filled passage, hence producing poor US images.

The limitation of our study was that the posterior tracheal wall was difficult to visualize by US because of the artifacts created by the intraluminal air column.

US has many advantages for imaging the airway; it is safe, quick, repeatable, portable, widely available, and provides real-time dynamic images relevant for several aspects of management of the airway. US of the upper airway is capable of providing detailed anatomic information and has many clinical applications.

Financial support and sponsorship

Nil.

Conflicts of interest

There are no conflicts of interest.

References

- Garg R, Gupta A. Ultrasound: a promising tool for contemporary airway management. *World J Clin Cases* 2015; **3**:926–929.
- Beale TJ, Rubin JS. In: Orloff LA, editor. *Laryngeal ultrasonography*. San Diego: Plural Publishing; 2008. pp. 183–202.
- Hall EA, Showaihi I, Shofer FS, Panebinco NL, Dean AJ. Ultrasound evaluation of the airway in the ED: a feasibility study. *Crit Ultrasound J* 2018; **10**:3.
- Carden KA, Boisselle PM, Waltz DA, Ernst A. Tracheomalacia and tracheobronchomalacia in children and adults: an in-depth view. *Chest* 2005; **127**:984–1005.
- Lee KS, Sun MRM, Ernst A, Feller-kopman D, Majid A, Boisselle PM. Comparison of dynamic expiratory CT with bronchoscopy for diagnosing airway malacia: a pilot evaluation. *Chest* 2007; **131**:758–764.
- Wahidi MM, Jain P, Jantz M, Lee P, Mackensen GB, Barbour SY, *et al.* American College of Chest Physicians consensus statement on the use of topical anesthesia, analgesia and sedation during flexible bronchoscopy in adult patients. *Chest* 2011; **140**:1342–1350.
- Singh M, Chin KJ, Chan VW, Wong DT, Prasad GA, Yu E. Use of sonography for airway assessment: an observational study. *J Ultrasound Med* 2010; **29**:79–85.
- Osman A, Sum KM. Role of upper airway ultrasound in airway management. *J Intensive Care* 2016; **52**:1–7.
- Wojtczak JA. Submandibular sonography: assessment of hyomental distances and ratio, tongue size, and floor of the mouth musculature using portable sonography. *J Ultrasound Med* 2012; **31**:523–528.
- Ezri T, Gewürtz G, Sessler DI, Medalion B, Szmuk P, Hagberg C, *et al.* Prediction of difficult laryngoscopy in obese patients by ultrasound quantification of anterior neck soft tissue. *Anaesthesia* 2003; **58**:1111–1114.
- Tejesh CA, Manjunath AC, Shivakumar S, Vinayak P, Yatish B, Geetha CR. Sonographic detection of tracheal or esophageal intubation: a cadaver study. *Saudi J Anaesth* 2016; **10**:314–316.
- Sustic A. Role of ultrasound in the airway management of critically ill patients. *Crit Care Med* 2007; **3**:173–177.

- 13 Altun D, Sungur MO, Ali A, Bingül ES, Seyhan TO, Çamcı E. Ultrasonographic measurement of subglottic diameter for paediatric cuffed endotracheal tube size selection: feasibility report. *Turk J Anaesthesiol Reanim* 2016; **44**:301–305.
- 14 Bae JY, Byon HJ, Han SS, Kim HS, Kim JT. Usefulness of ultrasound for selecting a correctly sized uncuffed tracheal tube for paediatric patients. *Anaesthesia* 2011; **66**:994–998.
- 15 Kundra P, Mishra SK, Ramesh A. Ultrasound of the airway. *Indian J Anaesth* 2011; **55**:456–462.
- 16 Giassart HA, Burns J. The compromised airway: tumors, strictures, and tracheomalacia. *Surg Clin North Am* 2010; **90**:1065–1089.
- 17 Kandaswamy C, Bird G, Gill N, Math E, Vempilly JJ. Severe tracheomalacia in the ICU: identification of diagnostic criteria and risk factor analysis from a case control study. *Respir Care* 2013; **58**:340–347.
- 18 Ernst A, Majid A, Feller-Kopman D, Guerrero J, Boisselle P, Loring SH, *et al.* Airway stabilization with silicone stents for treating adult tracheobronchomalacia: a prospective observational study. *Chest* 2007; **132**:609–616.
- 19 Loring SH, O'Donnell CR, Feller-Kopman DJ, Ernst A. Central airway mechanics and flow limitation in acquired tracheobronchomalacia. *Chest* 2007; **131**:1118–1124.
- 20 Adnan M, Kumar G, Jully MS, Robert LB, Erik F, Sebastian FB, *et al.* Evaluation of tracheobronchomalacia by dynamic flexible bronchoscopy. *Ann Am Thorac Soc* 2014; **11**:951–955.
- 21 Kerolous G, Ikladios O. Tracheomalacia and recurrent exacerbations of chronic obstructive pulmonary disease: a case report and review of the literature. *J Community Hosp Intern Med Perspect* 2016; **48**:61–66.
- 22 Caplan RA, Benumof JL, Berry FA, Blitt CD, Bode RH, Cheney FW, *et al.* Practice guidelines for management of difficult airway: a report by American Society of Anaesthesiologists Task Force on management of the difficult airway. *Anesthesiology* 1993; **78**:597–602.
- 23 Wu J, Dong J, Ding Y, Zheng J. Role of anterior neck soft tissue quantifications by ultrasound in predicting difficult laryngoscopy. *Med Sci Monit* 2014; **18**:2343–2350.
- 24 Adhikari S, Zeger W, Schmier C, Crum T, Craven A, Frokaj I, *et al.* Pilot study to determine the utility of point-of-care ultrasound in the assessment of difficult laryngoscopy. *Acad Emerg Med* 2011; **18**:754–758.
- 25 Komatsu R, Sengupta P, Wadhwa A, Akca O, Sessler DI, Ezri T. Ultrasound quantification of anterior soft tissue thickness fails to predict difficult laryngoscopy in obese patients. *Anaesth Intensive Care* 2007; **35**:32–37.
- 26 Kalezić N, Lakicevic M, Milicic B, Stojanovic M, Sabljak V, Markovic D. Hyomental distance in the different head positions and hyomental distance ratio in predicting difficult intubation. *Bosn J Basic Med Sci* 2016; **16**:232–236.
- 27 Abraham S, Himarani J, Mary Nancy S, Shanmugasundaram S, Krishnakumar Raja VB. Ultrasound as an assessment method in predicting difficult intubation: a prospective clinical study. *J Maxillofac Oral Surg* 2018; **17**:563–569.
- 28 Chun R, Kirkpatrick AW, Sirois M, Sargasy AE, Melton S, Hamilton DR, *et al.* Where's the tube? Evaluation of hand-held ultrasound in confirming endotracheal tube placement. *Prehosp Disaster Med* 2004; **19**:366–369.
- 29 Neumar RW, Otto CW, Link MS, Kronick SL, Shuster M, Callaway CW, *et al.* American Heart Association Guidelines for cardiopulmonary resuscitation and emergency cardiovascular care. Part 8. *Circulation* 2010; **122**:729–767.
- 30 Adi O, Chaun TW, Rishya M. A feasibility study on bedside upper airway ultrasonography compared to waveform capnography for verifying endotracheal tube location after intubation. *Crit Ultrasound J* 2013; **5**:7.
- 31 Ma G, Davis DP, Schmitt J. The sensitivity and specificity of transcricothyroid ultrasonography to confirm endotracheal tube placement in a cadaver model. *J Emerg Med* 2007; **32**:405–407.
- 32 Gottlieb M, Holladay D, Peksa GD. Ultrasonography for the confirmation of endotracheal tube intubation: a systematic review and meta-analysis. *Ann Emerg Med* 2018; **72**:627–636.
- 33 Chou HC, Chong KM, Sim SS, Ma MH, Liu SH, Chen NC, *et al.* Real-time tracheal ultrasonography for confirmation of endotracheal tube placement during cardiopulmonary resuscitation. *Resuscitation* 2013; **84**:1708–1712.
- 34 Chou EH, Dickman E, Tsou P, Tessaro M. Ultrasonography for confirmation of endotracheal tube placement: a systematic review and meta-analysis. *Resuscitation* 2015; **90**:97–103.
- 35 Shibasaki M, Nakajima Y, Ishii S, Shimizu F, Shime N, Sessler DI. Prediction of pediatric endotracheal tube size by ultrasonography. *Anesthesiology* 2010; **113**:819–824.
- 36 Lakhal K, Deplace X, Cottier JP, Tranquart F, Sauvagnac X, Mercier C, *et al.* The feasibility of ultrasound to assess subglottic diameter. *Anesth Analg* 2007; **104**:611–614.
- 37 Husein M, Manoukian JJ, Patenaude Y, Platt R. Ultrasound and a new videobronchoscopy to assess the subglottic diameter in the paediatric population: a first look. *J Otolaryngol* 2002; **31**:220–226.
- 38 Isaiah A, Mezrich R, Wolf J. Ultrasonographic detection of airway obstruction in a model of obstructive sleep apnea. *Ultrasound Int Open* 2017; **3**:34–42.
- 39 Liu KH, Chu WC, To KW, Ko FW, Tong MW, Chan JW, *et al.* Sonographic measurement of lateral pharyngeal wall thickness in patients with obstructive sleep apnea. *Sleep* 2007; **30**:1503–1508.
- 40 Kocis KC, Radell PJ, Stenberger WI. Ultrasound evaluation of piglet diaphragm function before and after fatigue. *J Appl Physiol* 1997; **83**:1654–1659.
- 41 Jiang JR, Tsai TH, Jerng JS, Yu CJ, Wu HD, Yang PC. Ultrasonographic evaluation of liver/spleen movements and extubation outcome. *Chest* 2004; **126**:179–185.
- 42 Osman AM, Hashim RM. Diaphragmatic and lung ultrasound application as new predictive indices for the weaning process in ICU patients. *Egypt J Radiol Nucl Med* 2017; **48**:61–66.
- 43 Kim WY, Suh HJ, Hong SB, Koh Y, Lim CM. Diaphragm dysfunction assessed by ultrasonography: influence on weaning from mechanical ventilation. *Crit Care Med* 2011; **39**:2627–2630.
- 44 Saeed AM, El Maraghy AA, Raafat RH, Abd El Samad AM. Assessment of diaphragmatic mobility by chest ultrasound in patients with chronic obstructive pulmonary disease on different modes of mechanical ventilation. *Egypt J Bronchol* 2019; **13**:184–190.
- 45 Jokinen K, Palva T, Sutinen S, Nuutinen J. Acquired tracheobronchomalacia. *Ann Clin Res* 1977; **9**:52–57.