

# Swirling pattern in patients with exudative pleural effusion

Khaled Kamel, Raef H. Emam, Amira I. Almeldin, Yasmine H. El Hinnawy

**Objective** Thoracic ultrasound is the gold-standard method for studying pleural effusions. It is more sensitive than chest radiography or computed tomography.

**Aim** The aim of the paper was to determine whether the echogenic swirling pattern identifiable on real-time chest ultrasonographic images is a predictor of malignant pleural effusions.

**Design** Medical records of patients undergoing chest ultrasonography in the Chest Department in Kasr Alaini Cairo University Hospital in the period from July 2013 to December 2014 were reviewed retrospectively. Patients with an echogenic swirling pattern in the pleural effusion, or with malignant diseases associated with pleural effusions, whose pleural fluids had been examined cytologically or whose pleural tissues had been examined pathologically, were enrolled in this study. A total of 45 patients were included. Malignant pleural effusions were diagnosed by the presence of malignant cells in the pleural fluid identified by pleural biopsy. The echogenic swirling pattern was defined as numerous echogenic floating particles within the pleural effusion, which swirled in response to respiratory movement or heartbeat.

## Introduction

Pleural effusions are a common manifestation of many diseases. Lung cancer and other malignancies are commonly associated with pleural effusions. Malignant pleural effusions are not symptoms of respiratory system disease only [1].

Most effusions arise from tumor emboli to the visceral pleural surface, with secondary spreading to the parietal pleura [2]. Direct tumor invasion, distant hematogenous metastases, and lymphatic involvement may also lead to malignant pleural effusions. Paramalignant pleural effusions have been defined as effusions that are not the direct result of neoplastic involvement in the pleura, but are still related to the primary tumor, and include effusions owing to tumor-related lymphatic obstruction, postobstructive pneumonia or atelectasis, chylothorax, and hypoalbuminemia [3].

Thoracic ultrasound is the 'gold-standard' method for studying pleural effusions. Real-time chest ultrasonography offers a more effective and convenient method than traditional radiography for the detection of pleural effusions [4]. The role of real-time chest ultrasonography in identifying small-volume pleural effusions, pleural thickening, pleural metastases, pleural empyema, and pneumothorax is well documented.

This study aimed to determine whether the echogenic swirling pattern identifiable on real-time chest

**Results** There was a statistically significant relation between the swirling sign and the diameter, type, and amount of pleural fluid, with *P* value of 0.001. There was no statistical significance between the swirling sign and each of the diagnosis, whether malignant or nonmalignant, malignant cases either primary or secondary malignancy, and side of effusion.

**Conclusion** The presence of the swirling sign is related to the nature and amount of fluid and has no predilection to the diagnosis of the cause of pleural effusion.

*Egypt J Bronchol* 2017 11:250–254

© 2017 Egyptian Journal of Bronchology

*Egyptian Journal of Bronchology* 2017 11:250–254

**Keywords:** echogenic swirling, pleural effusions

Department of Chest Diseases, Faculty of Medicine, Cairo University, Cairo, Egypt

Correspondence to Yasmine H. El Hinnawy, MD, 16 El Tayaran Street, Nasr City, Cairo - 11759, Egypt; Tel: +20 122 233 7683; e-mail: jasminehamdy@yahoo.com

**Received** 25 July 2016 **Accepted** 28 February 2017

ultrasonographic images is a predictor of malignant pleural effusions in patients with pleural effusion.

## Patients and methods

A retrospective study included 45 patients who were selected from the inpatient Chest Department of Kasr Alaini Hospital, from July 2013 till December 2014.

### Inclusion criteria

Patients diagnosed as having exudative pleural effusion underwent transthoracic ultrasound as well as thoracentesis and thoracoscopy.

### Exclusion criteria

All transudative pleural effusion cases and undiagnosed cases of exudative pleural effusion were excluded.

Descriptive data of the study population were obtained including sex of the patients, side of pleural effusion, amount of fluid, and type of fluid.

We searched for swirl pattern in all patients with pleural effusions detected by chest ultrasonography,

---

This is an open access article distributed under the terms of the Creative Commons Attribution-NonCommercial-ShareAlike 3.0 License, which allows others to remix, tweak, and build upon the work noncommercially, as long as the author is credited and the new creations are licensed under the identical terms.

and all the patients had undergone cytologic examination of their pleural effusions or pathologic examination of pleural tissues (Fig. 1).

We classified the patients into two main groups – malignant and nonmalignant – and the malignant cases were subclassified as primary and secondary malignant effusion.

Malignant effusions were defined as exudates with evidence of malignant cells on cytologic examination of pleural fluids or pathologic examination of pleural tissues ( $N=30$ ).

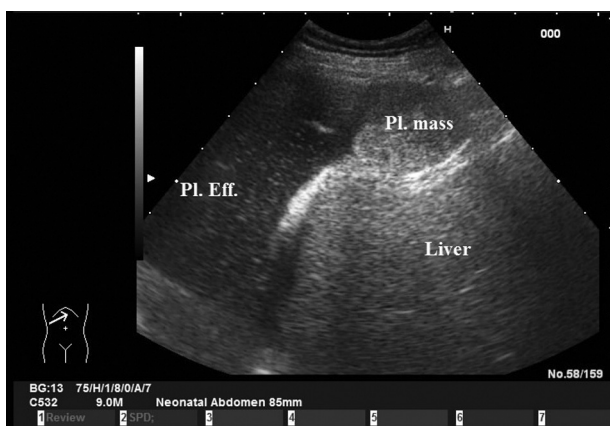Nonmalignant exudative effusions were defined as effusions owing to any other causes apart from malignancy, which may be parapneumonic effusion, tuberculosis, or collagen vascular diseases ( $N=15$ ).

#### Ultrasonographic criteria for defining the echogenic swirling pattern

Examinations were performed using a real-time ultrasound scanner (Hitachi EUB-7000 with 3.5 MHz convex probe transducer, Hitachi, Japan). All patients were examined in an upright sitting position or the lateral decubitus position. The chest ultrasonographic scanning was operated by well-trained chest physicians.

The swirling pattern was defined as numerous floating echogenic particles within the pleural effusion that moved in response to respiratory movement and/or heartbeat under real-time sonographic examination. Descriptions of this echogenic swirling pattern in pleural effusions have been recorded in previous chest ultrasonography reports [5].

**Figure 1**



Transthoracic ultrasound showing right sided pleural mass and effusion.

#### Pleural fluid and biopsies

All pleural fluid records of biochemical and cytological examinations were reviewed. Also all histopathological examination of thoracoscopic pleural biopsy were revised.

#### Statistical methods

Data were coded and entered using the statistical package statistical package for the social sciences version 23 (SPSS; SPSS Inc., Chicago, Illinois, USA). Data were summarized using mean and SD for quantitative variables and frequencies (number of cases) and relative frequencies (percentages) for categorical variables. Comparisons between groups were done using unpaired *t*-test [6]. For comparing categorical data,  $\chi^2$ -test was performed. Exact test was used instead when the expected frequency is less than 5 [7]. *P* values less than 0.05 were considered as statistically significant.

#### Results

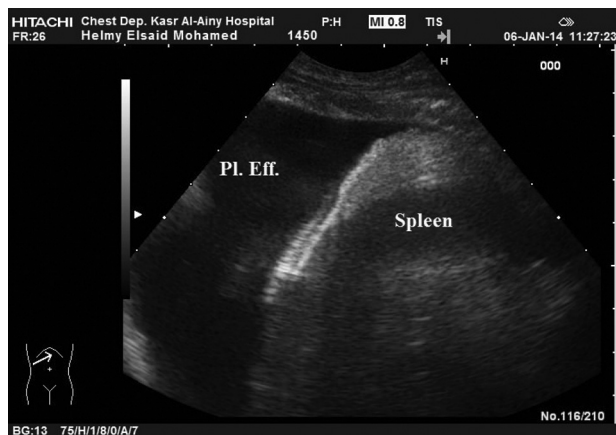
The descriptive analysis is shown in Table 1. A total of 45 patients formed the study population, where 23 (51.1%) were male and 22 (48.9%) were female.

Overall, 40% of cases had left-sided pleural effusion and 60% had right-sided pleural effusion. The fluid was complex nonseptated in 82.2% (Fig. 2), complex septated in 13.3% (Fig. 3), and echogenic fluid in 4.4%.

**Table 1** Descriptive analysis of the study

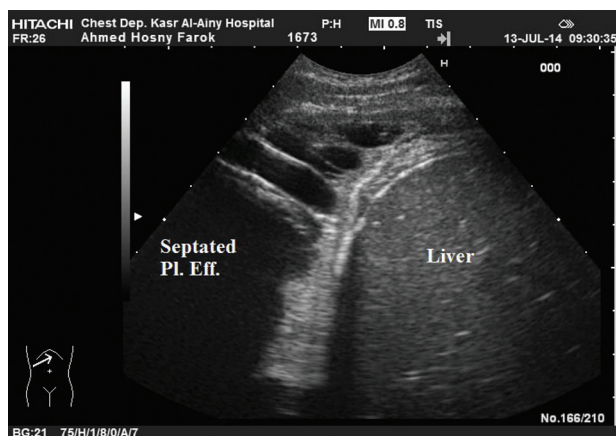
	Count (%)
Sex	
Female	22 (48.9)
Male	23 (51.1)
Side	
Left	18 (40.0)
Right	27 (60.0)
Amount	
Mild	5 (11.1)
Moderate	21 (46.7)
Massive	19 (42.2)
Type	
Complex nonseptated	37 (82.2)
Complex septated	6 (13.3)
Echogenic	2 (4.4)
Swirling	
Positive	34 (75.6)
Negative	11 (24.4)
Diagnosis	
Malignant	30 (66.7)
Nonmalignant	15 (33.3)
Subdiagnosis	
Primary	10 (33.3)
Secondary	20 (66.7)

Figure 2



Transthoracic ultrasound showing left sided complex nonseptated pleural effusion.

Figure 3



Transthoracic ultrasound showing right sided complex septated pleural effusion.

The mean diameter of the pleural fluid was 9.13 cm, with minimum 2 cm and maximum 14 cm as shown in Table 2.

In case of positive swirl sign, the mean diameter of the fluid was 10.18 with SD of 1.98, whereas in cases with negative swirl sign, the mean diameter was 5.91 with SD of 3.3 (Table 3). There was a statistically significant relation between the swirling sign and the diameter of pleural fluid, with *P* value of 0.001 (Fig. 4).

Overall, 94.1% of the positive swirl sign were with complex nonseptated effusion whereas 5.9% of them were with complex septated effusion. Moreover, 45.5% of negative swirl sign were having complex nonseptated effusion whereas 36.4% had complex septated effusion and 18.2% had echogenic effusion (Fig. 5). Table 4 shows that there was a statistical significance between swirling sign and the type of pleural fluid, with a *P* value of 0.001.

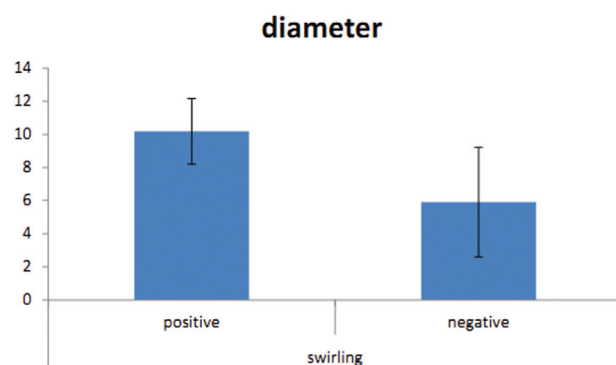
Table 2 Diameter of the pleural fluid

	Mean±SD	Minimum–maximum
Diameter	9.13±2.97	2.00–14.00

Table 3 Relation between the swirling sign and the diameter of the pleural fluid

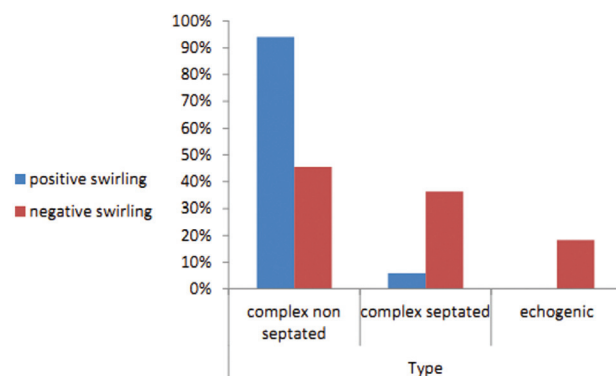
	Swirling (mean±SD)		<i>P</i> value
	Positive	Negative	
Diameter	10.18±1.98	5.91±3.30	0.001

Figure 4



Relation between the swirling sign and the diameter of the pleural fluid.

Figure 5



Relation between the swirling sign and the type of pleural fluid.

Table 4 Relation between the swirling sign and the type of pleural fluid

Types	Swirling [n (%)]		<i>P</i> value
	Positive	Negative	
Complex nonseptated	32 (94.1)	5 (45.5)	0.001
Complex septated	2 (5.9)	4 (36.4)	
Echogenic	0 (0.0)	2 (18.2)	

In positive swirl sign, 64.7% were malignant cases whereas nonmalignant cases were 35.3%. In addition, 72.7% of the negative swirl sign were malignant cases whereas 27.3% were nonmalignant cases. There was no statistical significance between

the swirling sign and the diagnosis, whether malignant or nonmalignant (Table 5).

Within the malignant cases, a subdivision is done into primary malignancy of the pleura having positive swirl sign in 31.8% and secondary malignancy having positive swirl sign 68.2%. There were no statistical significance between swirling sign and malignant cases, either primary or secondary malignancy (Table 6).

Positive swirl sign was present in 61.8% on the right side, whereas 38.2% on the left side. There was no statistical significance between the swirling sign and side of effusion (Table 7).

Positive swirling sign was equal in moderate and massive effusions, with 50% each, whereas negative sign was seen in 45.5% in mild cases, 36.4% in moderate, and 18.2% in massive pleural effusion (Fig. 6). There was a statistical significance between the swirling sign and amount of effusion, with *P* value of 0.001 (Table 8).

## Discussion

Chest ultrasonography is a very useful tool in assessing the nature of pleural opacities and effusions [8]. The sonographic patterns of pleural effusions have been subclassified as anechoic, complex nonseptated, complex septated, or echogenic [9].

There was a statistical significance between the presence of swirling sign and diameter (Table 3) and amount of fluid (Table 8), which can be explained by

the more the fluid, the more the space to allow motion of fluid particles.

Also there was a statistical significance between the presence of swirling sign and type of fluid. We assumed that septation impede the movement of the fluid as well as the echogenic fluid had high viscosity that decreased the fluid mobility.

In our study, there was no statistical significance between the presence of swirling sign and diagnosis of either malignant or nonmalignant cases. It contradicts the study done by Chian *et al.* [5] where they concluded swirling correlates strongly with malignant pleural effusions in patients with malignancies. However, there was no definite explanation for this, and further studies are needed.

We also found that there is no statistical significance between the presence of swirling sign and subdiagnosis of malignancies, either primary or secondary. This is in agreement with Chian *et al.* [5] where they found that swirling does not correlate with the presence of adenocarcinoma cells in malignant pleural effusions.

The side of the effusion and the presence of swirling sign showed no statistical significance, meaning that the heart pulsations do not affect the fluid pulsations.

The limitation of the study was the relatively the number of the patients forming the study population

**Table 5 Relation between the swirling sign and the diagnosis**

Diagnosis	Swirling [ <i>n</i> (%)]		<i>P</i> value
	Positive	Negative	
Malignant	22 (64.7)	8 (72.7)	0.726
Nonmalignant	12 (35.3)	3 (27.3)	

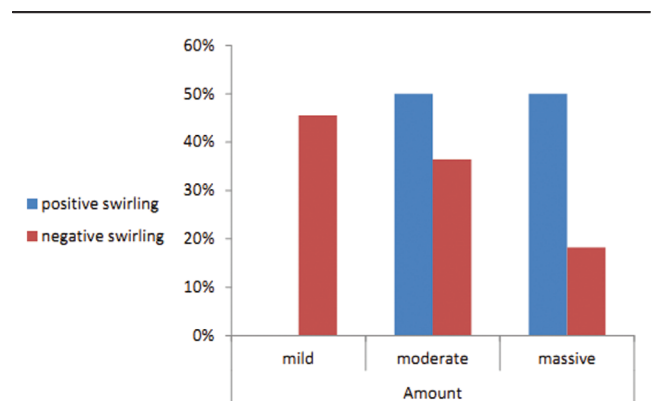
**Table 6 Relation between the swirling sign and the subdiagnosis**

Subdiagnosis	Swirling [ <i>n</i> (%)]		<i>P</i> value
	Positive	Negative	
Primary	7 (31.8)	3 (37.5)	1
Secondary	15 (68.2)	5 (62.5)	

**Table 7 Relation between the swirling sign and the side of effusion**

Side	Swirling [ <i>n</i> (%)]		<i>P</i> value
	Positive	Negative	
Left	13 (38.2)	5 (45.5)	0.732
Right	21 (61.8)	6 (54.5)	

**Figure 6**



Relation between the swirling sign and the amount of effusion.

**Table 8 Relation between the swirling sign and the amount of effusion**

Amount	Swirling [ <i>n</i> (%)]		<i>P</i> value
	Positive	Negative	
Mild	0 (0.0)	5 (45.5)	0.001
Moderate	17 (50.0)	4 (36.4)	
Massive	17 (50.0)	2 (18.2)	

and its retrospective nature, and further studies are needed to study the motion of the fluid particles and nature of the swirling sign.

### Conclusion

The presence of the swirling sign is related to the nature and amount of fluid and has no predilection to the diagnosis of the cause of pleural effusion. Echogenic swirling ultrasonographic pattern is not a predictor of malignant pleural effusion.

### Financial support and sponsorship

Nil.

### Conflicts of interest

There are no conflicts of interest.

### References

- 1 Chernow B, Sahn SA. Carcinomatous involvement of the pleura: an analysis of 96 patients. *Am J Med* 1977; **63**:695–702.
- 2 Meyer PC. Metastatic carcinoma of the pleura. *Thorax* 1966; **21**: 437–443.
- 3 American Thoracic Society. Management of malignant pleural effusions. *Am J Respir Crit Care Med* 2000; **162**:1987–2001.
- 4 Hirsch JH, Roger JV, Mack LA. Real-time sonography of pleural opacities. *AJR Am J Roentgenol* 1981; **36**:297–301.
- 5 Chian CF, Su WL, Soh LH, Yan HC, Perng WC, Wu CP. Echogenic swirling pattern as a predictor of malignant pleural effusion in patients with malignancies. *Chest* 2004; **126**:129–134.
- 6 Chan YH. Biostatistics 102: quantitative data – parametric & non-parametric tests. *Singapore Med J* 2003; **44**:391–396.
- 7 Chan YH. Biostatistics 103: qualitative data – tests of independence. *Singapore Med J* 2003; **44**:498–503.
- 8 Rosenberg ER. Ultrasound in the assessment of pleural densities. *Chest* 1983; **84**:283–285.
- 9 Yang PC, Luh KT, Chang DB, Wu HD, Yu CJ, Kuo SH. Value of sonography in determining the nature of pleural effusion: analysis of 320 cases. *Am J Roentgenol* 1992; **159**:29–33.