

# Endoscopic transbronchial needle aspiration in sampling mediastinal lesions

Mohammed A. Ibrahim<sup>a</sup>, Aida M. Yousef<sup>a</sup>,  
Mohamed S. Abdelrahman Hantera<sup>b</sup>, Magda Abdelsalam Ahmed<sup>a</sup>,  
Sayed A.M. Abdelhafez<sup>a</sup>

**Context** Endoscopy plays an integral part in the evaluation of mediastinum. Transbronchial sampling can be done conventionally or guided with endobronchial ultrasonography (EBUS), which is a new tool that allows seeing beyond the airway. Following its invention, the use of conventional sampling has declined.

**Aims** To evaluate the efficacy of EBUS-transbronchial needle aspiration (TBNA) in sampling mediastinal lesions after conventionally negative TBNA result and to compare EBUS-TBNA sampling in subcarinal and hilar sites versus paratracheal sites regarding diagnostic yield.

**Settings and design** A prospective evaluation study was done.

**Patients and methods** The study enrolled 52 patients with undiagnosed mediastinal lymphadenopathy or lesions. Subcarinal lesions were sampled by both conventional TBNA and EBUS-TBNA sampling (after negative conventional sampling results), and paratracheal lesions were sampled only with EBUS.

**Statistical analysis** used Data were analyzed to test statistical significant difference between groups. Quantitative data were presented as mean $\pm$ SD, and Student *t* test was used to compare between two groups.

**Results** No complications were reported. Conventional subcarinal TBNA sampling was done in 37 cases, where

sufficient sampling was seen in 67.6% of cases, was diagnostic in 16.2% and had sensitivity of 20%. EBUS-TBNA was done in 22 cases after negative conventional sampling result, and in additional 15 cases as an initial procedure during the study. EBUS diagnosed 89.2% of cases, with sensitivity of 97.1%. Diagnostic percent in EBUS targeting subcarinal/hilar sites was 81.8% whereas was 100% in paratracheal EBUS sampling.

**Conclusion** Both modalities of sampling are safe. Diagnostic value of EBUS-TBNA exceeded much more than conventional sampling.

*Egypt J Bronchol* 2019 13:314–322

© 2019 Egyptian Journal of Bronchology

*Egyptian Journal of Bronchology* 2019 13:314–322

**Keywords:** conventional transbronchial needle aspiration, endobronchial ultrasonography-transbronchial needle aspiration, endobronchial ultrasound, mediastinal lymph nodes, transbronchial needle aspiration

<sup>a</sup>Department of Chest Medicine, Mansoura University, Mansoura,

<sup>b</sup>Department of Chest Medicine, Tanta University, Tanta, Egypt

Correspondence to Mohammed Ahmed Ibrahim, MSC, MD Chest Medicine, Lecturer of Chest Medicine, Mansoura University, Mansoura faculty of medicine, El gomhuria street, Mansoura, Dakahlia, 35516, Egypt. Tel: +20 100 940 0754; e-mail: mohammedmansour.md@gmail.com

**Received** 10 December 2018 **Accepted** 16 May 2019

## Introduction

Mediastinal evaluation includes tissue sampling, which can be done by a variety of modalities such as endoscopic techniques (e.g. bronchoscopy), radiological methods [e.g. computed tomography (CT), fluoroscopy, and MRI], nuclear medicine techniques (e.g. positron emission tomography), and surgical procedures (e.g. mediastinoscopy and video-assisted thoracoscopy) [1]. Traditionally, mediastinoscopy is considered the gold standard [2]. However, less and minimally invasive procedures such as conventional transbronchial needle aspiration (cTBNA) and ultrasound-guided needle aspirate are available [3]. cTBNA attracts pulmonologists as it can be performed at the same setting as conventional bronchoscopy without the need for any complexed facilities [4]. More recently, endobronchial ultrasound-guided transbronchial needle aspiration (EBUS-TBNA) has been introduced as a new and interesting tool that allows prompt re-evaluation of all mediastinal sampling [5]. EBUS-TBNA (convex probe) has been introduced as a real-time sampling

method and allows imaging of surrounding vessels, which is not provided by conventional sampling [6]. Moreover, EBUS-TBNA seems to be superior over cTBNA regarding sampling of lesions near mediastinal vasculature and remote locations, but it may not be available, especially in low-resource settings [7].

The aim of the present study was to evaluate the efficacy of EBUS-TBNA in sampling mediastinal lesions after conventionally negative TBNA results and to compare EBUS-TBNA sampling in subcarinal and hilar sites versus paratracheal sites regarding diagnostic yield.

## Patients and methods

This prospective study was conducted between October 2016 and October 2018 in the Endoscopy

This is an open access journal, and articles are distributed under the terms of the Creative Commons Attribution-NonCommercial-ShareAlike 4.0 License, which allows others to remix, tweak, and build upon the work non-commercially, as long as appropriate credit is given and the new creations are licensed under the identical terms.

Unit of Mansoura University and Endoscopy Unit of Tanta University International Educational Hospital. A total of 52 patients with undiagnosed mediastinal lymphadenopathy and/or lesions were enrolled. Cases with undiagnosed mediastinal lymphadenopathy (stations 2R, 2L, 4R, 4L, 7, 10R, and 10L) or mediastinal lesions supposed to be within reach of EBUS-TBNA convex probe were included, whereas patients with clear contraindication to bronchoscopy such as life-threatening arrhythmia, poorly controlled heart failure, and severe or refractory hypoxemia were excluded, and also lesions or lymph node stations outside the scope of EBUS convex probe or small lesions with their short axis less than 10 mm in CT study were excluded. Patients with strict paratracheal (neither subcarinal nor hilar) pathology or previous cTBNA before being enrolled in our study were excluded from conventional sampling and passed directly into EBUS-TBNA sampling. There was no randomization, because all participants meeting inclusion criteria during the study period in our hospitals were included. Written informed consent was obtained from all patients included in this study, and the study protocol was approved by the ethics committee of Faculty of Medicine, Mansoura University, approval code 16.10.17, during October 2016.

All cases presenting with mediastinal lesions to our institutes during the time of study were enrolled in the study, provided that their lesions were within the reach and scope of EBUS probe regardless of their size or number, and cases with subcarinal lesions underwent conventional sampling and then EBUS sampling, and the comparison of safety and efficacy between EBUS and conventional sampling was at this level (one site, two modalities of sampling).

Cases with paratracheal lesions underwent EBUS sampling. The results of this were compared with EBUS sampling of subcarinal sites (two different target sites, same modality of sampling).

## Methods

- (1) Full clinical evaluation, laboratory evaluation (complete blood count and bleeding profile), other individualized testing according to the situation, and radiological evaluation by chest radiography and postcontrast CT.
- (2) Flexible bronchoscopy (possible endobronchial lesion and possible diagnostic lavage) was standard in all cases with local anesthesia with lidocaine 1–2% and conscious sedation with incremental doses of midazolam in slow

intravenous injection with initial dose of 2–2.5 mg (0.5–1 mg in the frail or elderly) given 5–10 min before procedure. Supplemental doses were given if required: 1 mg (0.5–1 mg in frail or elderly) at 2–10-min intervals, with usual maximum total dose of 3.5–7 mg (3.5 mg in frail or elderly, and may be higher in EBUS), and the position of the patient was supine with monitoring of blood pressure, ECG, and oxygen saturation.

- (3) Patients were subjected to cTBNA [eligible patients for cTBNA intervention, i.e., with lesions within the scope of cTBNA (stations 7 and 10 and/or lesions in corresponding sites), and patients had not been subjected to cTBNA before being enrolled in our study].
- (4) Then patients were subjected to EBUS-TBNA (after conventionally negative TBNA). Moreover, EBUS-TBNA was done from the start as an initial intervention in patients who were not eligible for cTBNA intervention (with strict paratracheal lesions or patients had previous nondiagnostic cTBNA before being enrolled in our study), and also patients diagnosed with conventional sampling were excluded from EBUS-TBNA.
- (5) For cTBNA:
  - (a) Available equipment was EP-i5000 (Pentax, Tokyo, Japan).
  - (b) Needle available in size of 22 G (ENDO-FLEX GmbH, Achenmule, Germany).
  - (c) The jabbing method was the used TBNA procedure in our study (it involves passing the catheter of needle through the scope's working channel, bringing the needle tip outside the catheter, and pushing the needle through the tissue while holding the bronchoscope firmly at mouth or patient's nostril), with added negative suction.
  - (d) Specimen is then prepared by flushing the needle with a small amount of air using a syringe directly onto a slide. A thin preparation is then made by smearing the specimen across the slide using a second slide. The slide is then immediately fixed with 70% alcohol (diluted formalin can be used if core biopsy is obtained). Cytology specimens were sent to the cytopathologist and labeled 'diagnostic' if a definitive cytologic diagnosis was made with TBNA or considered 'nondiagnostic' if no definitive cytological diagnosis could be obtained.

- (6) For EBUS-TBNA: Available equipment EBUS convex probe was HI VISION Avius (Hitachi Company, Tokyo, Japan), and the used needle had size of 21/22 G (ECHO-

HD, 22-EBUS P, Echotip, Ultra; Cook Ireland Ltd, Limerick, Ireland). This procedure was done using local anesthesia (lidocaine 1–2%) plus moderate sedation (incremental dosing of midazolam). The jabbing method was the used TBNA procedure, and systematic evaluation of mediastinal stations was done. Rapid on-site evaluation (ROSE) of EBUS-TBNA specimens was done to check sample adequacy and establish a preliminary diagnosis by performing a rapid stain in the bronchoscopy suite G. Undiagnosed cases by these modalities were referred to other diagnostic methods (CT-guided biopsy or mediastinoscopy).

#### Slide preparation for endobronchial ultrasonography-transbronchial needle aspiration

Following the TBNA, the stylet is reinserted into needle sheath to push cells through the needle, and then the tissue is split between two slides at least and then smeared. Overall, 50 ml of air can be flushed through the needle to dislodge tissue. One slide made is put directly into ethanol solution for traditional pathological examination, and the other slide can be examined with ROSE.

We worked on confirming sample adequacy by procedure-related parameters (number of punctures at least three per node). The minimum number of passes in any sample in our study is 3, so we achieved this condition. Other pathological factors included gross appearance of aspirated specimens (puslike or anthracotic), presence of tumor cells or granulomas, presence of microscopic anthracotic pigment, and high lymphocyte density in aspirates, and these were checked by a pathologist.

#### Statistical analysis

The statistical analysis of the data was done by using excel and statistical package for the social science programs, version 17 (Microsoft cooperation, Redmond, Washington, USA). The description of the quantitative data was done in the form of median (minimum–maximum). The analysis of the data was done to test statistical significant difference between groups. For quantitative data, they were presented as mean±SD, and Student's *t* test was used to compare between two groups.

#### Results

This prospective study included 52 patients of undiagnosed mediastinal lymphadenopathy and/or lesions (40 males and 12 females), with age range from 22 to 75 years, and mean±SD of 49.02±14.07. The most predominant presenting pulmonary symptom

in the studied patients was dyspnea (Table 1), which was encountered in 98.1% of patients followed by cough in 96.2% (51 and 50 cases, respectively), whereas signs suggestive of superior vena caval obstruction were found in five cases. All cases had postcontrast CT chest study with careful inspection of significant mediastinal lymph node stations (with their short axis >1 cm) and/or mediastinal lesions. Most of the cases had subcarinal pathology (lymph nodes and/or lesion) in ~84.6% (44 cases) followed by prevascular group and right hilar group (each of them were present in 46.2% of cases). Moreover, right lower paratracheal group was present in 23 (44.2%) cases (Table 2). The flow chart of cases is shown in Fig. 1. Regarding conventional sampling, 37 cases were subjected to cTBNA. Diagnosis was established in only six (16.2%) cases, with sensitivity of cTBNA being 20%. We failed to diagnose 31 cases by cTBNA, and most of them (22 cases) were subjected to EBUS-TBNA. The other nine cases did not complete EBUS sampling. One case was diagnosed by mediastinoscopy as sarcoidosis, two cases were diagnosed by CT guided as lymphoma and adenocarcinoma, and one case after follow-up was listed as pneumonia since showing complete clinical and radiological resolution.

Adenocarcinoma was the most common pathological finding (four cases), one case was diagnosed as sarcoidosis, and one case of lymph fluid was

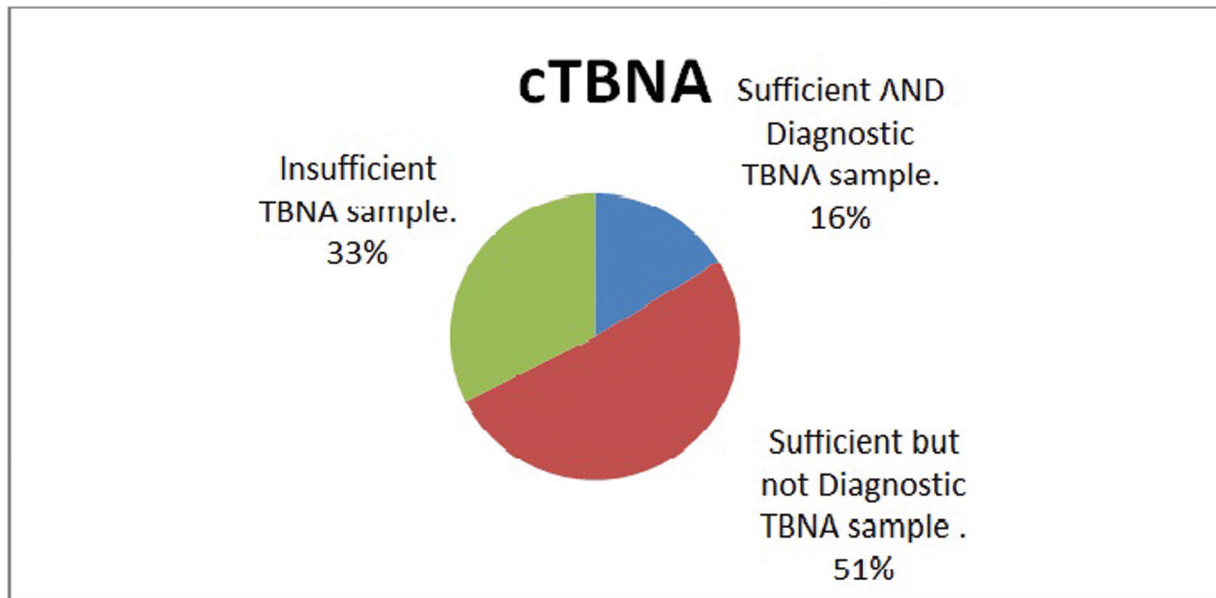
**Table 1 Presenting symptoms and signs of studied cases**

	Number	Percent % of all cases
Dyspnea	51	98.1
Cough	50	96.2
Chest pain	41	78.8
Wheezy chest	34	65.4
Toxic manifestation	15	28.8
Compression symptoms	15	28.8
SVCO (superior vena caval obstruction)	5	9.6

**Table 2 Radiological findings (lymph node stations) among studied cases**

Lesion	(N/%) of all studied cases
2R (upper right paratracheal group)	19 (36.5%)
2L (upper left paratracheal group)	4 (7.7%)
3 (prevascular and retrocaval group)	24 (46.2%)
4R (lower right paratracheal group)	23 (44.2%)
4L (lower left paratracheal group)	6 (11.5%)
5 (subaortic group)	8 (15.4%)
6 (paraaortic group)	8 (15.4%)
7 (subcarinal group)	44 (84.6%)
8 (paraesophageal group)	2 (3.8%)
10R (right hilar group)	24 (46.2%)
10L (left hilar group)	17 (32.7%)

Figure 1



Flow chart.

aspirated (bronchogenic cyst). Sampling was sufficient in most cases; however, it was not diagnostic in most cases (sufficiency of the sample was based on sample cellularity, presence of lymphocytes and adequacy for cytopathological examination) (Fig. 2). Cases are shown in Figs 3–5. Regarding EBUS-TBNA, the diagnostic percent reached 89.2%, with no reported complications related to the maneuver, and sensitivity of EBUS-TBNA was 97.1%. After performing EBUS-TBNA, four cases were not diagnosed; three of them refused further intervention and one was diagnosed by CT-guided biopsy as adenocarcinoma. Minimum number of passes per case was three, and maximum was six (Table 3), and the total number of passes within all cases had reached 149 passes. The most common station that was at target by EBUS-TBNA was subcarinal station with a percentage of 64.9% (was a common target in 24 cases), followed by lower right paratracheal group (32.4%), whereas upper paratracheal stations were the least to be biopsied (data are not cumulative, i.e., some cases were sampled at more than one station) (Table 4). Pathological results of EBUS and its subgroups are shown in Table 5. All cases are shown in Table 6.

We would like to point out that none of the microbiological data of BAL were diagnostic in any case.

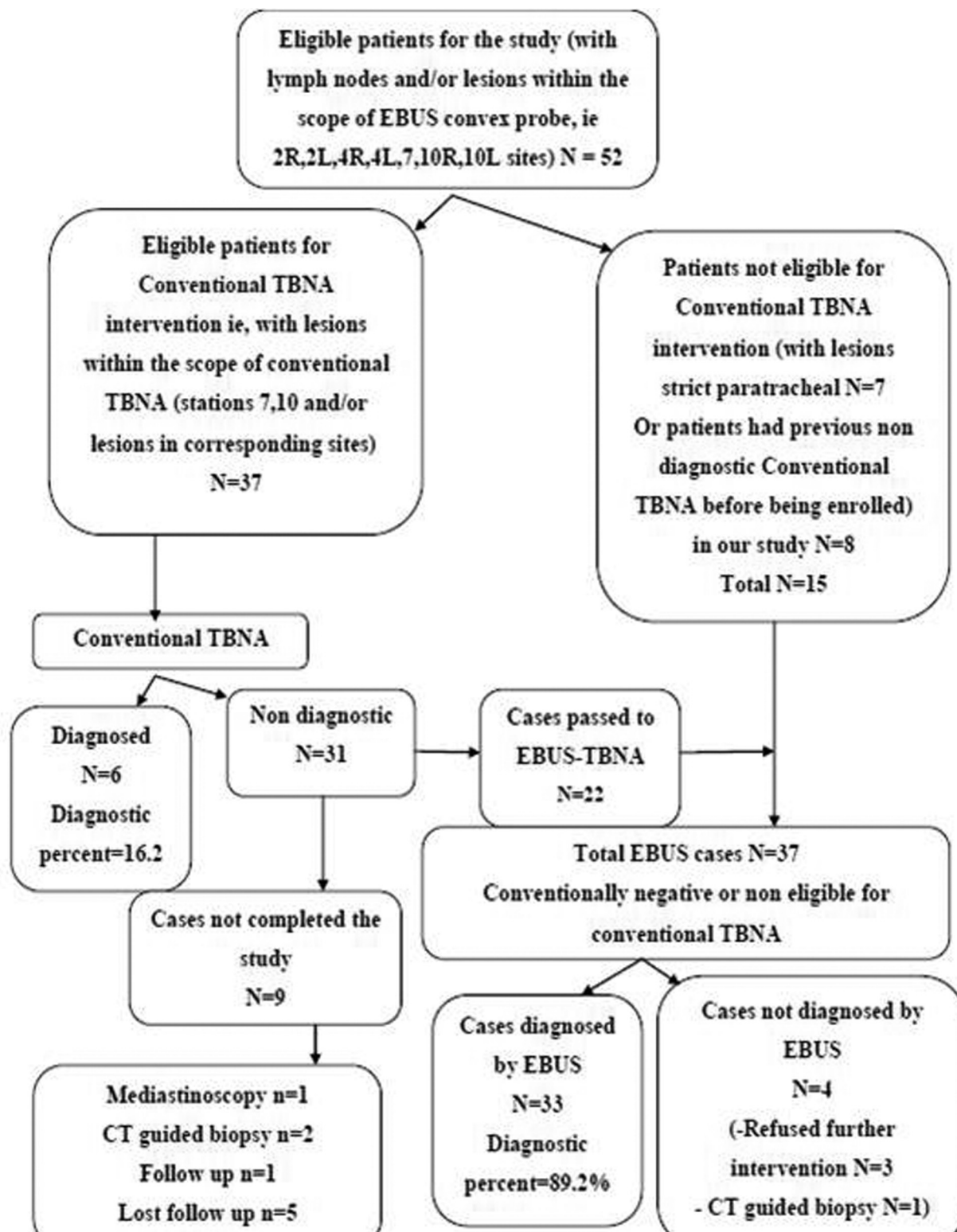
## Discussion

Our current study is concerned with mediastinal sampling, aiming primarily to evaluate the overall

safety of EBUS-TBNA (as regards complication), which was proved to be extremely safe with no related TBNA complication, and this was in accordance with most studies in literature, which also aimed to evaluate the efficacy of EBUS-TBNA in sampling mediastinal lymph nodes (stations 2R, 2L, 4R, 4L, 7, and 10) and mediastinal lesions in corresponding sites, which was high, with diagnostic percent of 89.2% and sensitivity of 97.1%. In a study done by Hong *et al.* [8], 33 patients were evaluated with EBUS-TBNA with diagnostic sensitivity of 90%. The number of passes ranged from one to five passes. In a study done by Sökücü *et al.* [9], EBUS-TBNA procedures were performed in 45 patients. The average number of needle passes was  $5.0 \pm 1.8$  (2–9) per patient (which exceed the number of passes among our cases). A total of 85 lymph nodes were sampled. Adequate material was found in all of the patients (100%). In 36 (80.0%) of the cases, the adequate material was diagnostic. They reported no complications. In a study done by Tournoya *et al.* [10], 60 patients were investigated with EBUS-TBNA. The majority (82%) had a prior (nondiagnostic) flexible bronchoscopy (like the majority of our cases). EBUS-TBNA was performed using a 22 G needle. Anesthesia in most cases was moderate sedation (midazolam,) whereas general anesthesia in six cases and local anesthesia only in four cases (we used only conscious sedation). Self-limiting atrial fibrillation was reported as a complication in one case, and diagnosis was confirmed in 77% of cases. In the study by Liu *et al.* [11], EBUS-TBNA was done in 55 patients, where a



Figure 2

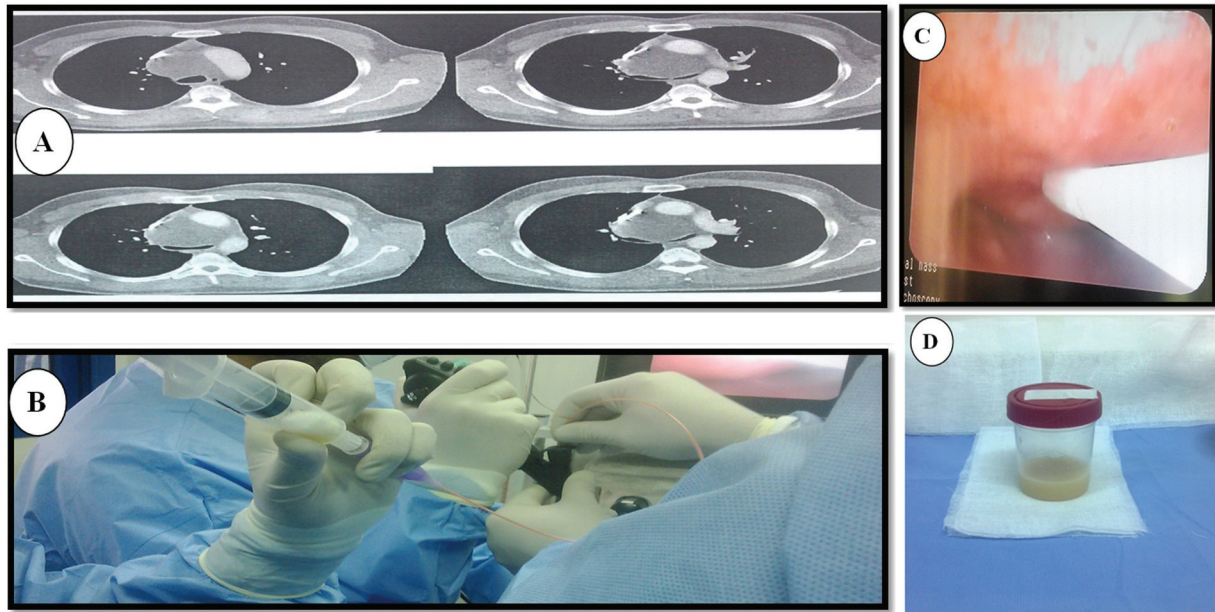


Conventional TBNA, sample adequacy. TBNA, transbronchial needle aspiration.

total of 80 stations were identified for sampling, and 178 biopsies were performed, with overall diagnostic accuracy of EBUS-TBNA was 87.3%. In our study, the most common sampled station by EBUS-TBNA was subcarinal station with a percentage of 64.9% (was a common target in 24 cases), followed by lower right

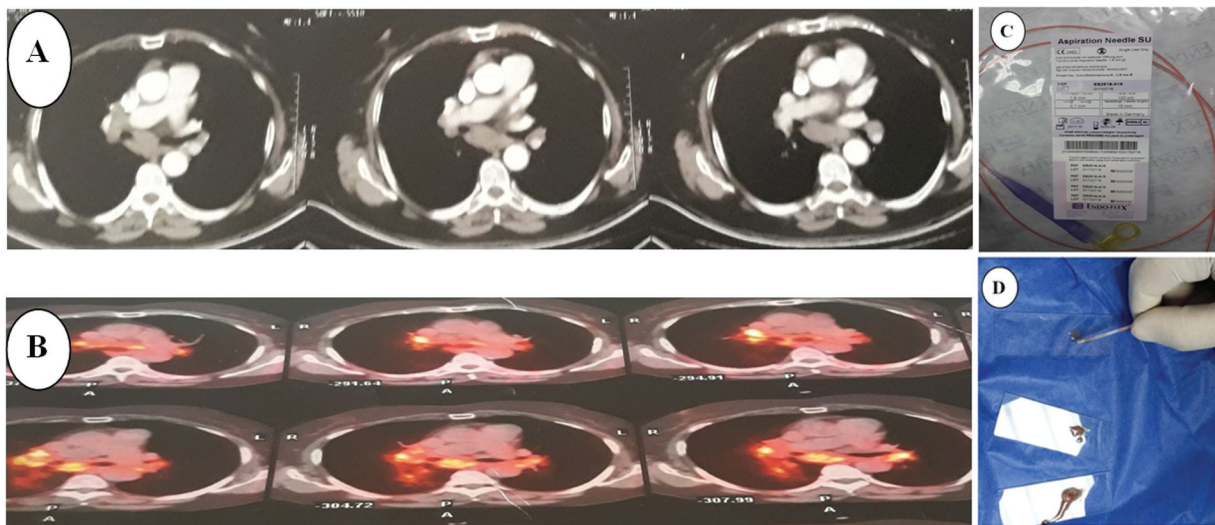
paratracheal group, and this was in accordance to Hong *et al.* [8]. The most sampled lymph node stations were subcarinal and right lower paratracheal sites. However, in the study by Sökücü *et al.* [9], the majority of sampled stations were subcarinal and hilar. In the current study, after performing EBUS-TBNA,

Figure 3



(a) Postcontrast CT chest study of a young male patient showing middle mediastinal homogenous, thin-walled and cystic lesion. (b) FOB-TBNA while negative suction brought milky fluid. (c) Bronchoscopic view while the needle is inserted anterior to tracheal carina. (d) Aspirated fluid collected in a bottle. All findings were suggestive of bronchogenic cyst. CT, computed tomography; TBNA, transbronchial needle aspiration.

Figure 4



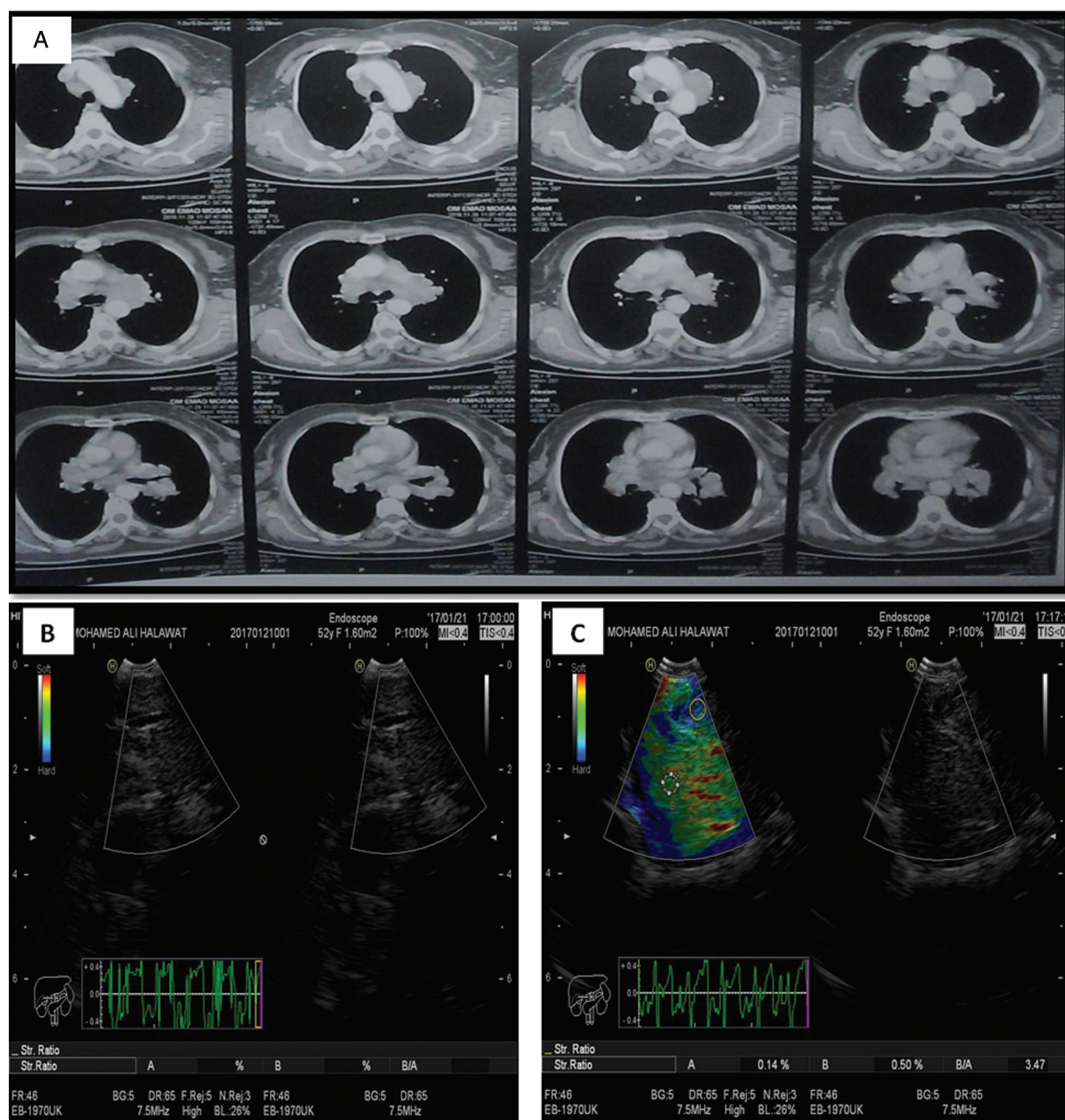
(a) CT chest with subcarinal and hilar lymphadenopathy of a 70-year-old male patient. (b) PET/CT positive uptake in subcarinal and hilar region. (c) A 22 G needle used for conventional sampling. (d) Preparation of thin smear over slides. Despite positive FDG-PET uptake of mediastinal lymph nodes and sufficient sampling (objective sufficiency –12 prepared slides) (pathological sufficiency with demonstrated few cellularity and lymphocytes. The result was negative conventional sampling). Patient refused resampling with EBUS. CT, computed tomography; EBUS, endobronchial ultrasonography; PET, positron emission tomography.

adenocarcinoma was the most common pathological diagnosis, and this was in accordance with Guarize *et al.* [12], which studied 1958 patients (largest published series in EBUS-TBNA), and adenocarcinoma was the prime diagnosis in this series (692 cases). Moreover, in a study by Liu *et al.* [11], 55 cases of EBUS-TBNA were evaluated and adenocarcinoma was the prime diagnosis (21 cases).

Moreover, our secondary objectives were to evaluate EBUS-TBNA versus cTBNA in sampling subcarinal and hilar lymph nodes (stations 7 and 10) and corresponding mediastinal lesions, besides evaluation of EBUS-TBNA in sampling subcarinal and hilar lymph nodes (stations 7 and 10) and lesions versus 2R, 2L, 4R, and 4L, that is, paratracheal and corresponding mediastinal lesions. We grouped



Figure 5



(a): A 52-year-old female patient, undergoing CT chest study showed enlargement of most lymph node stations (2R, 3, 4R, 5, 6, 7, 10R, 10L). She was diagnosed as having sarcoidosis by EBUS-TBNA after failed conventional transcarinal needle aspirate. (b and c) Images captured from EBUS during preparation for TBNA biopsy of a 52-year-old female patient diagnosed as having sarcoidosis. CT, computed tomography; EBUS, endobronchial ultrasonography; TBNA, transbronchial needle aspiration.

**Table 3** Number of TBNA passes

	Conventional TBNA	EBUS-TBNA
Minimum number of passes	3	3
Maximum number of passes	12	6
Mean	5.05	4.03
Standard deviation	±2.08	±0.96

EBUS, endobronchial ultrasonography; TBNA, transbronchial needle aspiration.

subcarinal and hilar stations together because most of pulmonologists are familiar with conventional sampling at these sites. Conventional sampling

reported no complication but established diagnosis in only six (16.2%) cases, with sensitivity of cTBNA of 20%. In Darjani *et al.* [13] 39 patients were subjected to cTBNA. Sampling of subcarinal, paratracheal, and hilar sites took place in this study. Definite final diagnosis was made in 22 patients (which is higher than our study). Evaluation of the aspirates obtained by TBNA showed that the sample was adequate and diagnostic in 21 (55.26%) patients, adequate but nondiagnostic in nine (23.68%) patients, and inadequate in eight (21.06%) cases. In the study by How *et al.* [14] on 25 patients, TBNA was positive in

**Table 4 Lymph node stations that were targeted by EBUS-TBNA**

Lesion	(N/%) of all EBUS-TBNA cases
2R (upper right paratracheal group)	1 (2.7%)
2L (upper left paratracheal group)	1 (2.7%)
4R (lower right paratracheal group)	12 (32.4%)
4L (lower left paratracheal group)	3 (8.1%)
7 (subcarinal group)	24 (64.9%)
10R (right hilar group)	3 (8.1%)
10L (left hilar group)	3 (8.1%)

EBUS, endobronchial ultrasonography; TBNA, transbronchial needle aspiration.

**Table 5 Pathological diagnosis and diagnostic percent in different subgroups of EBUS-TBNA (Endobronchial Ultrasound Guided Transbronchial Needle Aspiration)**

Total/ N	Both targeted/ N	Targeted Paratracheal sites/N	Targeted Subcarinal/ Hilar sites/N	
4	0	0	4	Not diagnosed
6	1	0	5	Sarcoidosis
16	2	7	7	Adenocarcinoma
7	0	2	5	Lymphoma
1	0	1	0	Squamous cell carcinoma
2	0	2	0	Small cell carcinoma
1	0	0	1	Large cell carcinoma
37	3	12	22	Total
89.2	100	100	81.8	Diagnostic percent%

15 (60%) patients. In a study by Lannes *et al.* [15] on 74 patients, 46% of samples were adequate and diagnostic. However, in the last three mentioned studies, they used 19 G eXcelon aspiration needle with larger pore than that used in our study. In our study, diagnostic percent of conventional sampling was 16.2%, whereas in EBUS-TBNA targeting subcarinal/hilar sites was 81.8%, and overall diagnostic percent of EBUS-TBNA was 89.2%. Other studies that compared EBUS-TBNA versus cTBNA like Stoll *et al.* [16], Wallace *et al.* [17], Rong *et al.* [18], Arslan *et al.* [19], Bellinger *et al.* [20], Tremblay *et al.* [21], and Gupta *et al.* [22], the number of involved patients were 262, 150, 95, 60, 291, 50, and 130, respectively, with diagnostic yield of EBUS-TBNA versus cTBNA of 85.2 versus 54.5%, 69 versus 35.7%, 96 versus 92%, 66.7 versus 33.3%, 84 versus 86%, 83.3 versus 50.9%, and 74.5 versus 48.4%, respectively. It is notable that most of the studies reported a significant superiority of EBUS-TBNA over cTBNA; however, the difference

**Table 6 Final diagnosis of all studied cases with the corresponding method of diagnosis**

	Frequency	Percent	Method of diagnosis
Adenocarcinoma	22	42.3%	EBUS-TBNA n=16, C-TBNA n=4, CT guided biopsy n=2
Lymphoma	8	15.4%	EBUS-TBNA n=7, C-TBNA n=0, CT guided biopsy n=1
Sarcoidosis	8	15.4%	EBUS-TBNA n=6, C-TBNA n=1, Mediastinoscopy n=1
Small cell carcinoma	2	3.8%	EBUS-TBNA n=2
Squamous cell carcinoma	1	1.9%	EBUS-TBNA n=1
Large cell carcinoma	1	1.9%	EBUS-TBNA n=1
Bronchogenic cyst	1	1.9%	C-TBNA n=1
Pneumonia	1	1.9%	Follow up after negative C-TBNA and had complete radiological resolution after 3 weeks
Not diagnosed	8	15.4%	Refused further interventions.
Total	52	100%	

EBUS-TBNA, endobronchial ultrasound guided transbronchial needle aspirate; C-TBNA, conventional transbronchial needle aspirate; CT, computed tomography.

was not significant in Rong *et al.* [18], but they reported that sample adequacy rate was higher with EBUS-TBNA. Bellinger *et al.* [20] reported superiority of conventional methods; however, they reported smaller sampled nodes with EBUS. Our study was in accordance with most of the studies reporting superiority of EBUS-TBNA. We achieved one of the highest diagnostic success with EBUS; however, unfortunately we reported one of the least diagnostic yield among conventional TBNA. Regarding the last objective diagnostic percent within a group was 100% in EBUS-TBNA of paratracheal sites, whereas was only 81.8% in cases targeting subcarinal and/or hilar sites; however, different number of cases were enrolled in each group.

We have some limitations in our study such as limited total number of included patients, limited number of patients inside different groups, limited resources that limited bringing more EBUS-TBNA needles for more cases, and the two arms of the study were done at two different centers, as ROSE was available in EBUS center while was not available for cTBNA cases (availability of ROSE for cTBNA can guide the bronchoscopist for how many passes are needed and may guide him to change the site of sampling if needed) (but ROSE not alter the final pathological data). Moreover, doing a study between two centers



allows some patients to be lost to follow up, and also some cases with failed cTBNA may refuse further interventions by EBUS-TBNA in another center.

We also lacked a confirmatory gold standard test like mediastinoscopy or surgery; however, most of the current studies are with the same limitation.

## Conclusion

The two techniques used in the study (EBUS-TBNA and cTBNA) were proved to be extremely safe, whereas efficacy of EBUS-TBNA exceed much more than cTBNA sampling; however, conventional method still has a role especially in low-resource settings.

## Financial support and sponsorship

Nil.

## Conflicts of interest

There are no conflicts of interest.

## References

- Jenssen C, Annema TJ, Clementsen P, Cui XW, Borst MM, Dietrich CF. Ultrasound techniques in the evaluation of the mediastinum, part 2: mediastinal lymph node anatomy and diagnostic reach of ultrasound techniques, clinical work up of neoplastic and inflammatory mediastinal lymphadenopathy using ultrasound techniques and how to learn mediastinal endosonography. *J Thorac Dis* 2015; **7**:E439–E458.
- Venissac N, Alifano M, Mouroux J. Video-assisted mediastinoscopy: experience from 240 consecutive cases. *Ann Thorac Surg* 2003; **76**:208–212.
- Dietrich CF, Annema JT, Clementsen P, Cui XW, Maximilian M, Jenssen C. Ultrasound techniques in the evaluation of the mediastinum, part I: endoscopic ultrasound (EUS), endobronchial ultrasound (EBUS) and transcutaneous mediastinal ultrasound (TMUS), introduction into ultrasound techniques. *J Thorac Dis* 2015; **7**:E311–E325.
- Medford AR, Bennett JA, Free CM, Agrawal S. Mediastinal staging procedures in lung cancer: EBUS, TBNA and mediastinoscopy. *Curr Opin Pulm Med* 2009; **15**:334–342.
- Low A, Medford AR. Endobronchial ultrasound-guided transbronchial needle aspiration. *Rev Recent Clin Trials* 2013; **8**:61–71.
- Medford AR. Convex probe endobronchial ultrasound: pitfalls, training and service issues. *Br J Hosp Med Lond* 2011; **72**:312–317.
- Medford AR. Endobronchial ultrasound-guided versus conventional transbronchial needle aspiration: time to re-evaluate the relationship? *J Thorac Dis* 2014; **6**:411–415.
- Hong G, Lee KJ, Jeon K, Koh WJ, Suh GY, Chung MP, et al. Usefulness of endobronchial ultrasound-guided transbronchial needle aspiration for diagnosis of sarcoidosis. *Yonsei Med J* 2013; **54**:1416–1421.
- Sökücü SN, Çetinkaya E, Altın S, Karasulu L, EkremCengizSeyhan EC, Turna A. Diagnostic value of EBUS in mediastinal and hilar lymph nodes. *Tur Toraks Der* 2009; **10**:167–171.
- Tournoya KG, Rintoulb RC, van Meerbeeck JP, Nicholas R, et al. EBUS-TBNA for the diagnosis of central parenchymal lung lesions not visible at routine bronchoscopy. *Lung Cancer* 2009; **63**:45–49.
- Liu A, Qian L, Zhong Y, Lu X, Zhao Y. Endobronchial ultrasound guided transbronchial needle aspiration combining with immunohistochemistry and genotype in lung cancer: a single-center, 55 cases retrospective study. *Ann Med Surg* 2017; **23**:1–7.
- Guarize J, Casiraghi M, Donghi S, Diotti C, Vanoni N, Romano R, et al. Endobronchial ultrasound transbronchial needle aspiration in thoracic diseases: much more than mediastinal staging. *Can Respir J* 2018; **2018**:4269798.
- Darjani HRJ, Kiani A, Bakhtiar M, Sheikhi M. Diagnostic yield of transbronchial needle aspiration (TBNA) for cases with intra-thoracic lymphadenopathies. *Tanaffos* 2011; **10**:43–48.
- How SH, Kuan YC, Ng TH, Norra H, Ramachandram K, Fauzi AR. Transbronchial needle aspiration of mediastinal lymph node. *Med J Malaysia* 2008; **63**:178–181.
- Lannes D, Monteiro AS, Toscano E, Cavalcanti A, Nascimento M, de Biasi P, et al. Transbronchial needle aspiration of hilar and mediastinal lymph nodes. *Rev Port Pneumol* 2007; **13**:651–658.
- Stoll LM, Yung RC, Clark DP, Li QK. Cytology of endobronchial ultrasound-guided transbronchial needle aspiration versus conventional transbronchial needle aspiration. *Cancer Cytopathol* 2010; **118**:278–286.
- Wallace MB, Pascual JM, Raimondo M, Woodward TA, McComb BL, Crook JE, et al. Minimally invasive endoscopic staging of suspected lung cancer. *JAMA* 2008; **299**:540–546.
- Rong F, Xiao SH, Liu J, Li YX, Mai HY, Lu YS. A comparative research on the conventional transbronchial needle aspiration and endobronchial ultrasound-guided transbronchial needle aspiration for the diagnosis of mediastinum lesions. *Zhonghua Jie He He Hu Xi Za Zhi* 2011; **34**:120–122.
- Arsalan Z, Ilgazli A, Bakir M, Yildiz K, Topcu S. Conventional vs. endobronchial ultrasound-guided transbronchial needle aspiration in the diagnosis of mediastinal lymphadenopathies. *Tuberk Toraks* 2011; **59**:153–157.
- Bellinger CR, Chatterjee AB, Chin R Jr, Conforti J, Adair N, Haponik E. Conventional and endobronchial ultrasound-guided transbronchial needle aspiration: complementary procedures. *South Med J* 2012; **105**:625–629.
- Tremblay A, Stather DR, Maceachern P, Khalil M, Field SK. A randomized controlled trial of standard vs endobronchial ultrasonography-guided transbronchial needle aspiration in patients with suspected sarcoidosis. *Chest* 2009; **136**:340–346.
- Gupta D, Dadhwal DS, Agarwal R, Gupta N, Bal A, Aggarwal AN. Endobronchial ultrasound-guided transbronchial needle aspiration vs conventional transbronchial needle aspiration in the diagnosis of sarcoidosis. *Chest* 2014; **146**:547–556.