

# Severe thrombocytopenia and intracranial hemorrhage: Unusual presentation of tuberculosis

Saad R. Samra

**Background** Although various hematologic abnormalities are seen in tuberculosis (TB), severe thrombocytopenia is a rare event.

**Case presentation** We report a case of a 26-year-old female patient who presented with severe thrombocytopenia-induced hemoptysis, macroscopic hematuria, and intracranial hemorrhage. The patient was found to have clinical, microbiological, and histopathological evidence of TB. The thrombocytopenia was successfully treated with anti-TB drugs.

**Conclusion** Severe thrombocytopenia can be one of the hematological manifestations of TB that is successfully treated with anti-TB drugs.

## Introduction

Tuberculosis (TB) is a common health problem in developing countries. Severe thrombocytopenia leads to spontaneous bleeding, and life-threatening complications of TB are exceedingly rare. We report a case of a patient with severe thrombocytopenia that led to serious complication and the patient responded well to anti-TB therapy.

A 26-year-old previously healthy woman presented with a 4-day history of hematuria and hemoptysis. She had a 2-month history of malaise, fatigue, weight loss of 5 kg, cough, and a small amount of purulent sputum production with progressive dyspnea. No other symptoms were reported. Detailed history disclosed no drug use before admission to our clinic. On physical examination, she had normal blood pressure, pulse 112/min, and respiration 30/min, with febrile temperature (38.5°C). There was bilateral axillary (apical and middle group) lymph node (LN), which was small (~0.5 cm) discrete, painless, and firm, with intact skin over it. There was a systolic cardiac murmur of grade II heard all over the pericardium. Chest examination stated stony dullness and decreased vesicular breath sound on lower axilla and infrascapular areas of right side. The remainder of the physical examination result was normal. The chest radiography demonstrated complete opacification of right side (Fig. 1).

Laboratory findings on admission revealed a white blood cells of 11 000/mm<sup>3</sup>, hemoglobin (Hb) 4.5 g/dl, platelet count 11×10<sup>9</sup>/l (normal range 200–400×10<sup>9</sup>/l), and reticulocytes of 19.7%. Erythrocyte morphology was polychromatic together with macrocytosis,

*Egypt J Bronchol* 2017 11:386–390

© 2017 Egyptian Journal of Bronchology

**Egyptian Journal of Bronchology** 2017 11:386–390

**Keywords:** thrombocytopenia, tuberculosis, unusual presentation

Department of Chest Diseases, Faculty of Medicine, Zagazig University, Zagazig, Egypt

Correspondence to Saad R. Samra, MD Degree in Chest Diseases and Tuberculosis. Tel: +20 100 554 2133; e-mail: saad\_samra2003@yahoo.com

**Received** 9 July 2016 **Accepted** 6 August 2016

spherocytosis, and anisopoikilocytosis, with 6% normoblasts, and remarkable for a paucity of platelets. The erythrocyte sedimentation rate was 37 mm/h, and the coagulation profile was within normal limits. Direct and indirect Coombs' test results were negative. Lactic acid dehydrogenase level was 520 U/l (normal range <250 U/l). Total protein was 7.45 g/dl, and globulin was 6 g/dl. Aspartate transaminase was 110 (normal range: 15–35) and alanine transaminase 31 (normal range: 15–35).

Chest computed tomography with contrast revealed collapsed right lung except a segment of upper lobe with large septal and multilobular lesion occupying most of right hemithorax, enlarged LN right axilla, paratracheal and anterior mediastinum, and ascites (Figs 2 and 3).

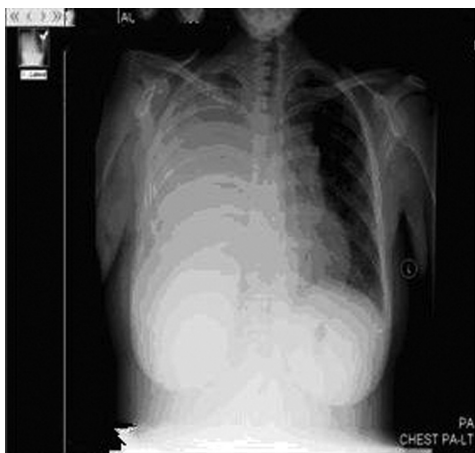Antinuclear antibody, rheumatoid factor, hepatitis, and HIV test results were all were negative. Under complete aseptic condition, 200 ml of hemorrhagic effusion was aspirated (pH of 7.03, adenosine deaminase of 73 IU/l, total and differential cell count 16 000/mm<sup>3</sup> with polymorph nuclear cells predominant, and no organism in gram stain or on culture; cytopathology revealed no malignant cells, and her pleural fluid result for acid-fast bacilli was negative).

Bone marrow examination disclosed significant erythroid hyperplasia and hypercellularity, with no

---

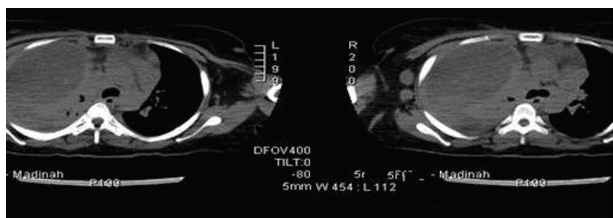
This is an open access article distributed under the terms of the Creative Commons Attribution-NonCommercial-ShareAlike 3.0 License, which allows others to remix, tweak, and build upon the work noncommercially, as long as the author is credited and the new creations are licensed under the identical terms.

Figure 1



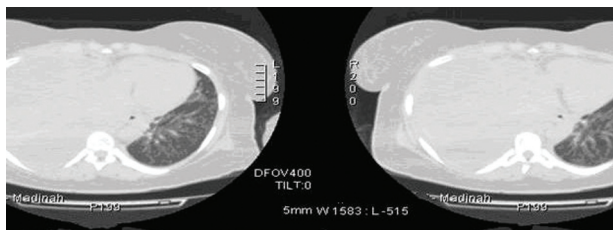
CXR showed massive rt sided pleural effusion.

Figure 2



CT Chest showed rt sided effusion.

Figure 3



CT chest represent rt pleural effusion.

atypical cells or granuloma observed on this biopsy. Bone marrow aspirate result was negative, and showed an increase in a number of megakaryocytes. Five sputum smears and urine test results for acid-fast bacilli were negative. The results of tumor markers ( $\alpha$ -fetoprotein and carcinoembryonic antigen, C125) were all negative. Fine needle aspiration (FNA) was not informative because it was difficult to perform as her palpable LN were too small. Bronchoscopy could not be instituted because of her very low platelet counts.

On admission, her platelet count was  $11 \times 10^9/l$  and Hb was 4.5 g/dl, so replacement therapy [5 U platelets and 2 U packed red blood cell (RBCs)] given.

On the fourth day since admission, her platelet count and Hb were still very low ( $7 \times 10^9/l$  and Hb was 6.8 g/dl, respectively) and the patient became drowsy and developed acute type 11 respiratory failure ( $pH=7.27$ ,  $PCO_2=65$  and  $HCO_3=25.3$ ), so the patient intubated and mechanically ventilated and started on anti-TB therapy consisting of isoniazid 5 mg/kg/day, ethambutol 25 mg/kg/day, rifampicin 10 mg/kg/day, levofloxacin 500 mg/12 h, and pyrazinamide 35 mg/kg/day) plus prednisolone 1 mg/kg/day, replacement therapy (in the form of 5 U platelets' and 2 U packed RBCs), and immunoglobulin G 25 g intravenously/5 days. The constitutional symptoms of the patient progressed day by day.

At the end of the 17th day after admission, her platelet count was four and Hb was 7.4, with coagulation profile, liver, kidney functions, and electrolytes within reference range. She developed fits in the face and upper limbs, and computed tomography brain was done and showed right front parietal hemorrhage (Fig. 4).

At the end of 18th day of anti-TB therapy, her platelet count started to increase (platelet count was  $68 \times 10^3$  and Hb 8.8 g/dl), so excisional biopsy of her right axillary LN was done, which came as a caseating granuloma in favor of TB (Figs 5 and 6). Therefore, she was continued on anti-TB treatment, and intercostal tube was inserted (2 l of hemorrhagic effusion was drained).

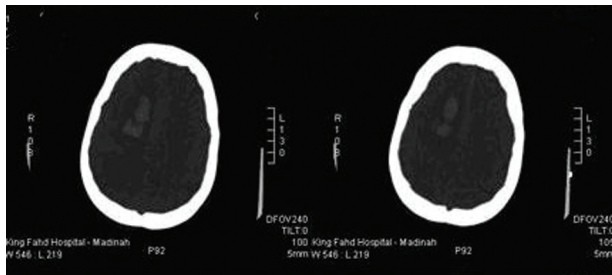
At the end of 20th day of anti-TB therapy, her platelet count was  $129 \times 10^3$  and Hb 9.8 g/dl.

Her anti-TB drug regimen was further modified; she was given rifampicin, and pyrazinamide, isoniazid, ethambutol, levofloxacin, vitamin B6 and pyrazinamide, ethambutol and levofloxacin were stopped after 2 months. She was discharged from the hospital and seen in an outpatient clinic, and she was generally fine and could move with a support, as her left side was still somewhat weak and was on anti-TB medication.

At the time of discharge, she had received 6 U of RBC and 15 U of platelets throughout the course of hospitalization.

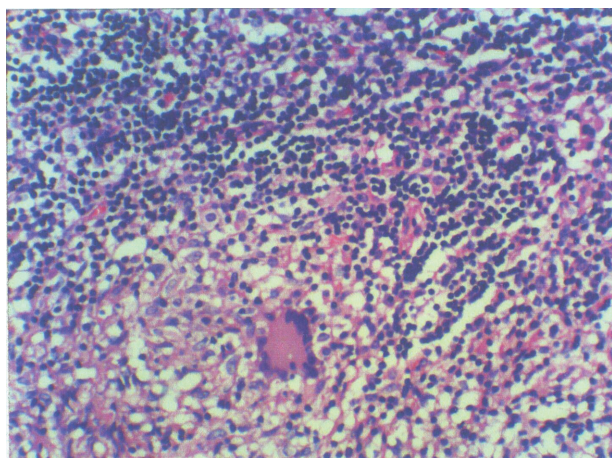
During her hospitalization, findings of hemorrhage or gastrointestinal bleeding and massive bleeding in another site, except hematuria, hemoptysis, and intracranial hemorrhage, were not established.

Figure 4



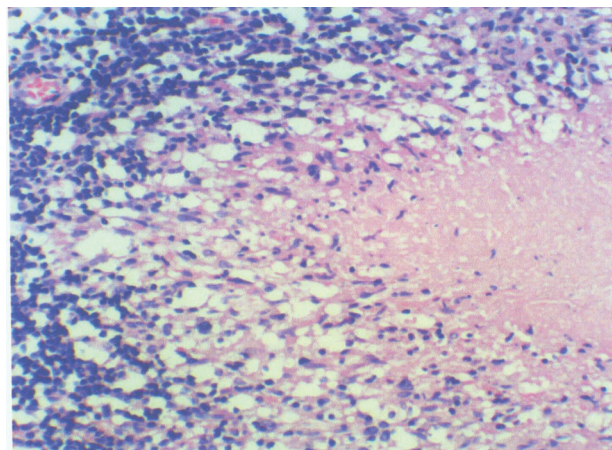
CT brain showed cerebral heamorrhage.

Figure 5



Histopathology of LN represent casting granuloma.

Figure 6



Showed longerhans giant cell and many lymphocytes with central necrosis.

A complete blood count at discharge demonstrated a white blood cells of  $5.1 \times 10^9/l$ , Hb of 10.5 g/dl, and platelet count was  $240 \times 10^9/l$  (Table 1). Corticosteroids were discontinued on day 14 of therapy, and the patient was discharged. Recurrent thrombocytopenia was not established after withdrawal

Table 1 Progress of the case

Day	Hb (g/dl)	Platelets ( $10^9/l$ )	WBCs ( $10^3/mm^3$ )	Treatment
1	4.5	11	11.2	Replacement therapy: 5 U platelets and 2 U packed RBCs
2	7	8	7.5	
3	7.2	12	3.9	
4	6.8	7	5	
				Intubation and mechanical ventilation started ATT pulse prednisolone 1 mg/kg/day, replacement therapy, and IgG 25 g IV/5days
5	8.5	7	3.44	
6	8	6.8	3.2	
7	9	13	3.9	
8	6.3	11.2	3.6	
9	6.4	9.6	6.6	
11	7.5	7.2	5.4	
14	7.6	17.2	4.6	
16	9.2	10	1.9	
18	8.5	7	2.3	
20	9.4	11	4.3	
21	7.4	4	6.7	
22	8.8	68	2.9	
23	8.5	85	2.9	
25	9.8	129	3.7	
30	9.9	189	3.9	
35	10.5	240	5.1	
90	11.5	279	6.4	

ATT, antituberculosis treatment; CT, computed tomography; Hb, hemoglobin; IgG, immunoglobulin G; IV, intravenous; RBC, red blood cell; WBC, white blood cell.

of corticosteroid therapy. Ninety days after discharge, the patient was well, with a platelet count of  $279 \times 10^9/l$  (Table 1), and she had no adverse effect thought to be secondary to anti-TB drugs.

**Discussion**

TB differs from many other infectious maladies in having particular social and geographic distributions. The disease was under control in developed nations and was getting under control in developing nations, until the emergence of drug-resistant strains of mycobacteria in HIV [1,2]. Various hematologic abnormalities such as anemia, leukocytosis, monocytosis, lymphopenia, leukopenia, thrombocytopenia, thrombocytosis, leukemoid reactions, and pancytopenia have been seen in TB [3,4]. An association between TB and thrombocytopenia is exceedingly rare. Pulmonary TB represents the most common clinical presentation, having occurred in 33% of cases, followed by disseminated TB and lymphadenitis [5].

Another complicated issue in the treatment of these patients is the hematological adverse effects of anti-



TB drugs like rifampicin and pyrazinamide. We observed no hematological effects with rifampicin and pyrazinamide in our patient [6].

The case that we report could be confused by coincidental presentation of thrombocytopenia and TB, by drug-induced thrombocytopenia, thrombotic thrombocytopenic purpura-hemolytic uremic syndrome, hemophagocytic syndrome, and disseminated intravascular coagulation (DIC) associated with TB. In our case, we excluded the adult immune thrombocytopenic purpura not only by basing on the standard criteria [7] but with response to steroids and intravenous immunoglobulin (IVIg) therapy as thrombocytopenia did not recur after withdrawal of prednisone and IVIg therapy. Moreover, we excluded other causes of thrombocytopenia such as hemophagocytic syndrome, thrombotic thrombocytopenic purpura, combined autoimmune cytopenias with history, clinical and laboratory findings, and examination of bone marrow aspiration, demonstration of positivity of acid-fast bacilli in pleural fluid by PCR, and excisional biopsy of her right axillary LN that came as caseating granuloma in favor of TB.

Several factors are known to cause bleeding in association with infections, of which thrombocytopenia is the most common. The etiology of thrombocytopenia in most cases appears to be increased destruction of platelets because of DIC or septicemia without evidence of DIC or platelet adherence to damaged vascular surfaces or direct platelet toxicity caused by the microorganism or involvement of bone marrow [8].

Although the most important therapy for infection-related thrombocytopenia is that directed at the underlying infection, treatment decisions for thrombocytopenia remain controversial and may include single or combination therapy with corticosteroids and IVIg according to degree of thrombocytopenia or hemorrhage [9].

Anti-TB therapy was applied combined with corticosteroids and IVIg because of severe thrombocytopenia and severe hemorrhagic diathesis.

Clinically, steroids are known to ameliorate the purpuric bleeding in patients before the platelet count actually increases. The early effect is because of decrease of vascular permeability. The effect of the steroids in the thrombocytopenia is probably complex. The mechanism of action of IVIg is unclear, but studies suggest blockage of the Fc receptors of the reticuloendothelial cells and

suppression of antibody production, and binding which may be because of anti-idiotypic antibodies that bind antiplatelet antibodies and modulate the immune response [9].

In our case, corticosteroids were discontinued on day 14 of therapy, and the patient was discharged, and recurrent thrombocytopenia was not established after withdrawal of corticosteroid therapy. These observations suggest that TB is the cause of thrombocytopenia in our patient. She received a total RBC of 6 U throughout the hospitalization stay. Ninety days after discharge, the patient was in good health, with a platelet count of  $279 \times 10^9/l$ , and she had no adverse effect thought to be secondary to anti-TB drugs [10,11]. The patient is follows up without the evidence of relapsing of thrombocytopenia.

## Conclusion

As the incidence of TB is currently increasing worldwide and it may present with different hematologic manifestations, in case of severe thrombocytopenia, TB should be recognized early in the course of the disease as a treatable and secondary cause of thrombocytopenia. Finally, further studies are needed to fully characterize the pathophysiology and immunological abnormalities in TB-related severe thrombocytopenia.

**Financial support and sponsorship**  
Nil.

## Conflicts of interest

There are no conflicts of interest.

## References

- 1 Goldenberg AS. Hematologic abnormalities and mycobacterial infections. In: Rom WN, Garay S, editor. *Text book of tuberculosis*. 1st ed. New York: Little, Brown and Company; 1996. pp.645-655.
- 2 Mert A, Bilir M, Tabak F, Ozaras R, Ozturk R, Senturk H, et al. Miliary tuberculosis: clinical manifestations, diagnosis and outcome in 38 adults. *Respirology* 2001; **6**:217-224.
- 3 Enarson DA, Murray JF. Global epidemiology of tuberculosis. In: Rom WN, Garay S, editor. *Text book of tuberculosis*. 1st ed. New York: Little, Brown and Company; 1996. pp. 57-76.
- 4 Paolo WF, Nosanchuk JD. Tuberculosis in New York city: recent lessons and a look ahead. *Lancet Infect Dis* 2004; **4**:287-293.
- 5 Ghobrial MW, Alborno MA. Immune thrombocytopenia: a rare presenting manifestation of tuberculosis. *Am J Hematol* 2001; **67**:139-143.
- 6 Aaron L, Saadoun D, Calatroni I, Launay O, Memain N, Vincent V, et al. Tuberculosis in HIV-infected patients: a comprehensive review. *Clin Microbiol Infect* 2004; **10**:388-398.
- 7 Ali R, Özkalemkas F, Özçelik T, Özkocaman V, Ozan Ü, Kimya Y, et al. Idiopathic thrombocytopenic purpura in pregnancy: a single institutional experience with maternal and neonatal outcomes. *Ann Hematol* 2003; **82**:348-352.
- 8 Levine SP. Thrombocytopenia caused by immunologic platelet destruction. In: Greer JP, Foerster J, Lukens JN, Rodgers GM, Paraskevas F, Glader B, editor. *Text book of Wintrobe's clinical*

- hematology*. 11th ed. Philadelphia: Lippincott Williams & Wilkins; 2004. pp. 1535–1554.
- 9 Levine SP. Miscellaneous causes of thrombocytopenia. In: Greer JP, Foerster J, Lukens JN, Rodgers GM, Paraskevas F, Glader B, editor. *Text book of Wintrobe's clinical hematology*. 11th ed. Philadelphia: Lippincott Williams & Wilkins; 2004. pp.1566–1572.
- 10 Stork CM, Hoffman RS. Toxicology of antituberculosis drugs. In: Rom WN, Garay S, editor. *Text book of tuberculosis*. 1st ed. New York: Little, Brown and Company; 1996. pp. 829–841.
- 11 Yee D, Valiquette C, Pelletier M, Parisien I, Rocher I, Menzies D. Incidence of serious side effects from first-line antituberculosis drugs among patients treated for active tuberculosis. *Am J Respir Crit Care Med* 2003; **167**:1472–1477.